Mind Maps in Gyn & Obst

By

Dr. Mohamed El-Mandooh

Assistant professor of obstetrics & Gynecology

Ain Shams University

www.Dr-Mandooh.com

DAR EL ALEBBA
دار الأطباء
للنشر والتوزيع

Contents

Gynecology

1 General classification
2 Anatomy
3 Body-cx-isthmus
4 External genitalia
5 Bl. supply/ Pelvic floor
6 Physiology (cycles)
7 Physiology (hormones)
8 Embryology (anomalies)
9 Menopause
10 Amenorrhea -1-
11 Amenorrhea -2-
12 Primary amenorrhea
13 Anovulation (PCO)
14 Abn. genital bleeding
15 Dysmenorrhea
16 Infertility (assessment)
17 Infertility (management)
18 Infection (organisms)
19 Infection (cervicitis/ PID)
20 Infection (continue)
21 Contraception
22 Contraception (continue)
23 G. scheme for tumors
24 Fibroid
25 Endometrial cancer
26 Endometriosis
27 Gest Troph. Neoplasia
28 Cancer cervix
29 Ovarian tumors -1-
30 Ovarian tumors -2-
31 Ovarian tumors -3-
32 Vulval lesions
33 Vulval lesions (continue)
34 Prolapse
35 Prolapse management
36 Stress urinary incont
37 Fistula
38 Pelvic floor operations
39 Scheme (4 sympt.)
40 Scheme (tumors)
41 Scheme (swellings)
42 Scheme (bleeding -1-)
43 Scheme (bleeding -2-)
44 Scheme (bleeding -3-)
45 Scheme (bleeding -4-)
46 Scheme (bleeding -5-)
47 Scheme (amenorrhea)
48 Scheme (anov. sympt.)
49 Scheme (infertility)
50 Pain in gyna
51 Childhood gynecology
52 Manifest of anomalies

Obstetrics

1 General obstet. scheme
2 General obstet. outline
3 Maternal adaptation
4 Abortion
5 Recurrent fetal loss
6 Ectopic pregnancy
7 Vesicular mole
8 Antepartum hge
9 Postpartum hge
10 Pre-eclampsia
11 Pre-eclampsia -2-
12 Diabetes mellitus
13 Heart disease
14 Heart disease -2-
15 Labor introduction -1-
16 Labor introduction -2-
17 Labor introduction -3-
18 Normal labor
19 Malpresent. scheme
20 OP /face /breech
21 Abn. uterine action
22 Contracted pelvis
23 Fetal well being
24 Fetal surveillance
25 IUGR / Macrosomia
26 PROM / Oligo / Poly
27 Multiple pregnancy
28 Hydrops fatalis
29 Forceps
30 Termination of preg
31 Scheme (Bl early preg -1-)
32 Scheme (Bl early preg -2-)
33 Scheme (Bl early preg -3-)
34 Scheme (PET / DM)
35 Scheme (DM + fetology)
36 Scheme (the whole labor)
37 Scheme (CPD / rupture ut)
38 Scheme(fetogy -1-)
39 Scheme(fetology -2-)
40 Scheme (fetal loss)
41 History
42 Examination
43 Investigations
44 Instruments
45 Obst cases -1-
46 Obst cases -2-

Gynecology

1 Basic Science

- Anatomy
  - الولادة *
  - ext. genit.
- Embriology (Anomalies)
  - ♀ ← ⊕ → ♂
- Physiology
  - A. 9-14 Puberty (مبكر ← → متأخر)
  - B. cycles
    - دم — ⇧ Abn. genital bl. / ⇩ Amenorrhea
    - وجع — Dys/menorrhea

} Abnormal 2 endocrindogy

Menopause
- Normal changes
- HRT

الوفاة *

3 infertility ⇩ الولادة

4 contra-ception ⇧ عالم

5 Infection بوابة (تفتح) cx — نواتج

6 Prolapse ut. cont. عنقة — الولادة

7 Oncology *
- cr endomet: Fibroid, endometriosis
- cr cervix: CIN
- cr ovary

تقسيمة المنهج

Obstetrics

Normal

1. Preg
   - الأم .... mat. adaptation
   - fetus --- F.C.B. (CTG)
2. Labor
   - Power --- uterus
   - Passenger --- البيبي
   - Passage --- الحوض
3. Peurp. — 42 days

- Abn. ut. action
- Malpresentations
- Contracted pelvis
- DVT
- peurp. sepsis

Abnormal

- الأم
  - diseaus --- HRP — HTN, DM, heart
  - bleeding --- early in preg: 1] Abortion, 2] Ectopic, 3] V. mole; --- Late in preg: 1] P. previa, 2] Acc. hge, --- Post-partum hge (كارثة)
- الجنين
  - الحجم: ↓ IUGR, ↑ macrosomia
  - المياه: ↓ oligo, ↑ poly, # PROM
  - العدد: twins
  - الشكل: مشوه

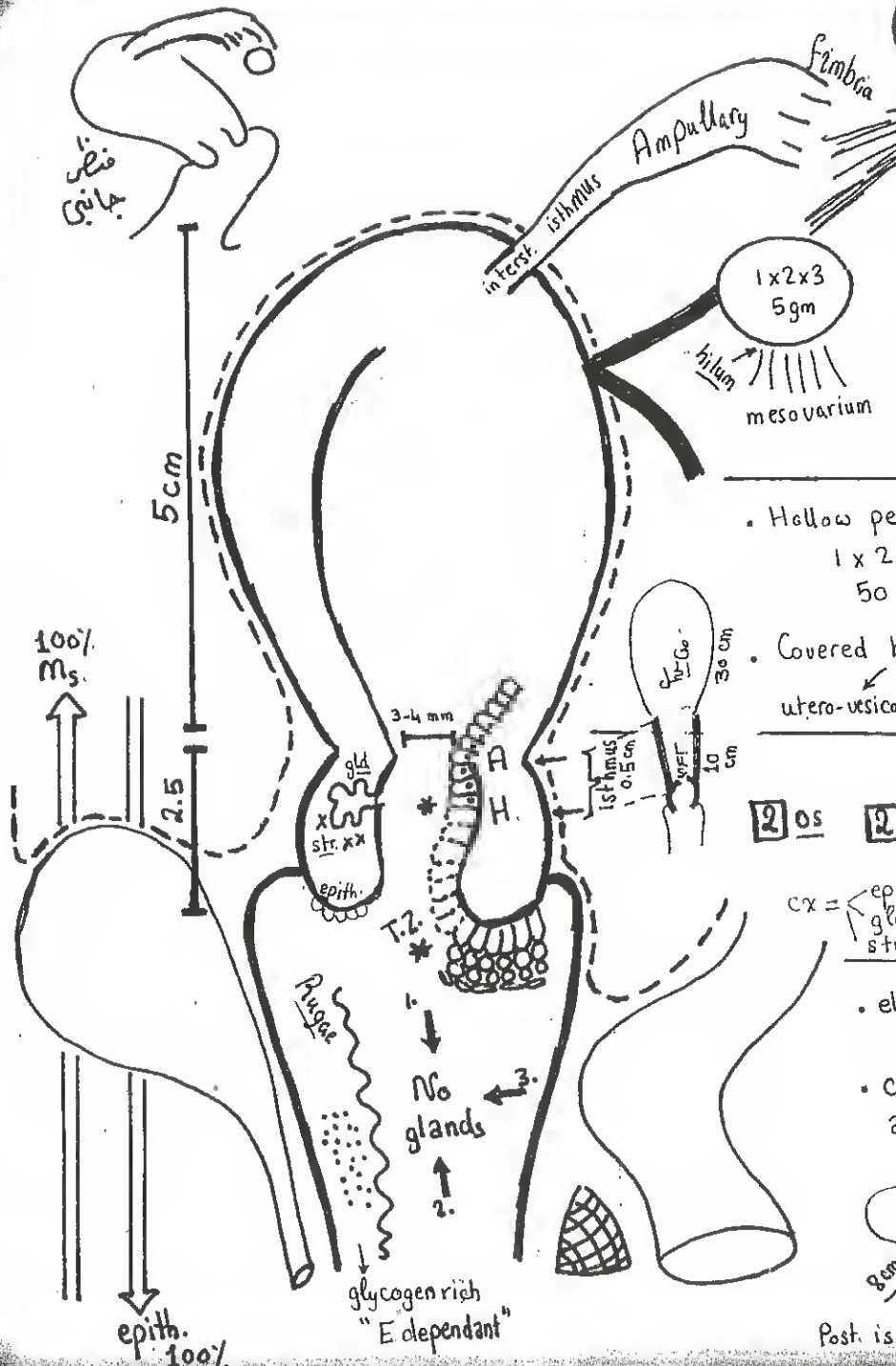

Anatomy

	epith.	muscles	Physiology
lies in ! free border of br. lig = 10 cm (4")	Parts not covered by perit. - interstitial - fimbria - inf. border	2 layers < outer long. / inner circ. prevent retrograde menses delay ovum 3 days	• ovum pick up (esp. fimbria, ovaric) • fertilization • uterotubal sphincte
lies freely in ! perit. cavity connected by [1] ov. lig. to ! uterus [2] infundibulo pelvic lig. to lat. pelvic wall [3] mesovarium to back of ! broad lig.	No perit. → coelemic epith. (not germinal) medulla vascular CT stroma cortex: main compartment		• ovum production • Hormones < E P An in cyclic manner
• Hollow pear shaped organ 1 x 2 x 3 " 50 gm • Covered by peritoneum < utero-vesical pouch, D. pouch	glands 2. 1. colum. epith. 3. 4. stroma	mainly muscular (3 layers) • outer longit. → pace maker at ! cornu • middle oblique → 8-shaped • inner circular → 3 sphincters	**Pregnancy** Rich in bl. supply Rt. lt
[2] os [2] parts < supra-vaginal, portio-vaginalis; cx = < epith. glands stroma	Hist. os: columnar [2] junct. st. sq. epith. Sq. col. j. = T.Z. دائما متحركة CIN: دائمي	mainly fibrous (90%) → Adv. strong for 9 ms Disady needs ripenining (PG)	**Support** Holds ! baby ⊕ < lig. pelvic floor
• elastic fibro-muscular canal • cervix projects in its ant. wall :- 4 fornices	St. sq. non-Keratinized ⊡ Rugae ⊡ No Glands < cervix, Bartholin, vag. transudation → D.E.S :- Vag. adenosis ⊡ Thick - glycogen rich } "E" dependant ph = 3.5-4.5	2 layers → outer longitud. → inner circular Cut section: Tr. / long.	**sexual intercourse** (through ext. genit.) liable to infect. esp. • Prepubertal - Postmenop.

Post. is deepest (8 cm, 10 cm) — 2 lateral

Body

1. **Perit**

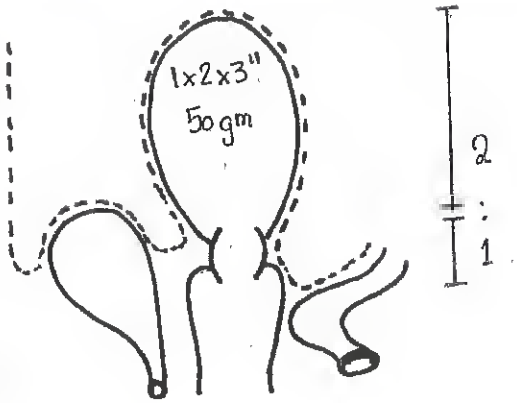

2. **Muscle**

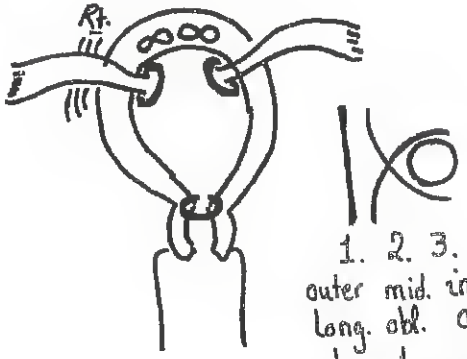

3. **Epith.**

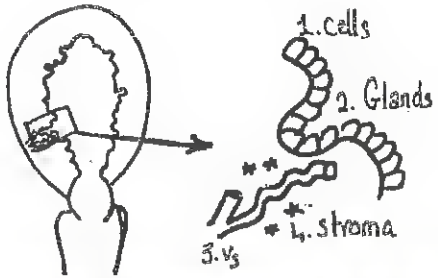

Cervix

2
- os ..... int. & ext.
- parts .... supravag. & portiovag.
- junct. .... Hist. int. os, Sq. col junc.

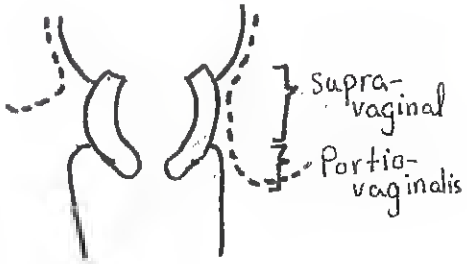

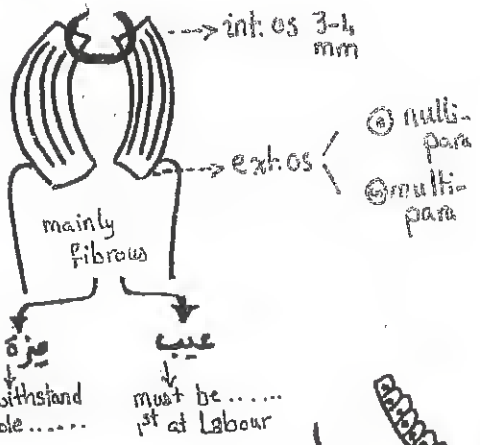

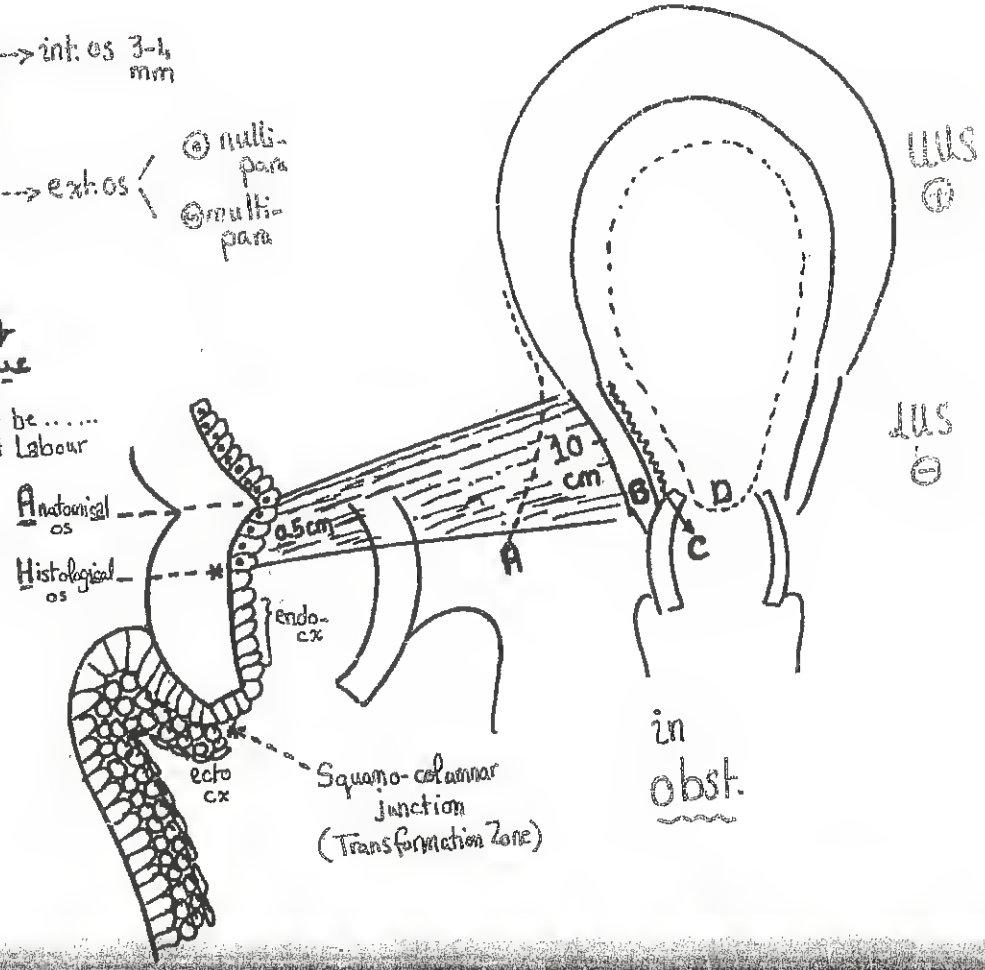

Isthmus

A. perit → loose

B. ms → 2 weak layers

C. decidua → weak

D. Amniotic sac → Loose

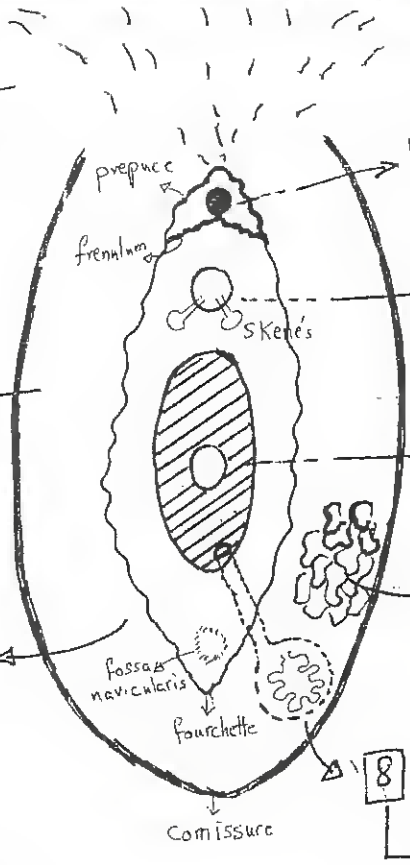

1 Mons pubis (veneris) — محدة ، وسادة
- pad of fat
- cushion during intercourse

2 Labia majora — جلد عادي
- 2 elliptical skin folds
- Keratinized
- labial fat
- hair follicles
- sebaceous glands
- sweat (apocrine) glands

3 Labia minora — جلد رفيع أحمر
- 2 elliptical modified skin
- no Keratin
- no fat
- no hair
- enclosing ! vestibule
  - ext. ureth. meatus
  - vag. orifice (introitus)
  - Barth. ducts

4 Clitoris — 1.5-2 cm
- inverted ▽, if hirsutism → apex reaches umbilicus
- 2 crura, body, head
- suspensory lig.
- 2 corpora cavernosa

5 ext. ureth. meatus — 3-4 cm
- Transitional epith. except distal 1/3 → st.

6 Hymen
- st. sq. epith.
- reminants after defloration :- Caruncular myrtiformis

7 vestibular bulb
- 2 collections of vascular C.T.
- in its lower 1/3 lies

8 Bartholin gland — غدة مخاطية — نظري

Anatomy
- size of a pea
- gland : racemose
- duct : 2cm (transit. epith.)

Significance :
- Bartholinitis (acute / chronic)
- ✓ Barth. cyst
- Adenocr. of Barth. (vulval swelling)

Vulva

Bl. supply
- Internal pudendal a. ✓✓
- ± sup. & deep ext. pud. (femoral)

Nerve supply
- Pudendal nerve ✓✓
- ± perineal br. of (lat. / post. cut. n. of thigh)
- ilio (inguinal / hypogastric)
- genital br. of genito-femoral n.

lymphatics = groin LN.

Vagina

Bl. supply (very rich)
- uterine (descending cx-vaginal / circular a. of ! cx → ant. & post. azygous)
- IIA → middle rectal, vaginal
- Int. pud. → inferior rectal

Nerve supply
- upper part (insensitive) ..... lower 1/4 (pudendal)

lymphatics
- upper part (with cx) ..... lower 1/4 (with vulva)

Female genital mutilation

Def. All procedures that involve partial / total removal of ext. genit. for cultural non-therapeutic reasons

- It is still practiced in Egypt, Sudan (tradition ?! / african ?! / religious ?!)
- It is tottaly condemned by ! WHO except (cosmetic / dyspareunia d.t. hypertrophy / Nymphomania)

types
- I → prepuce or ! whole clitoris
- II → + labia minora
- III → all ! ext. genit. + narrowing of introitus } Sudaneese ☹
- IV → unclassified e.g. tatoo, piercing

Comp

Immediate
- severe pain
- hge, inf.
- injury (urethra)

later on
- Psychological
- Retention dermoid
- obst. labor (fibrosis)

Blood supply

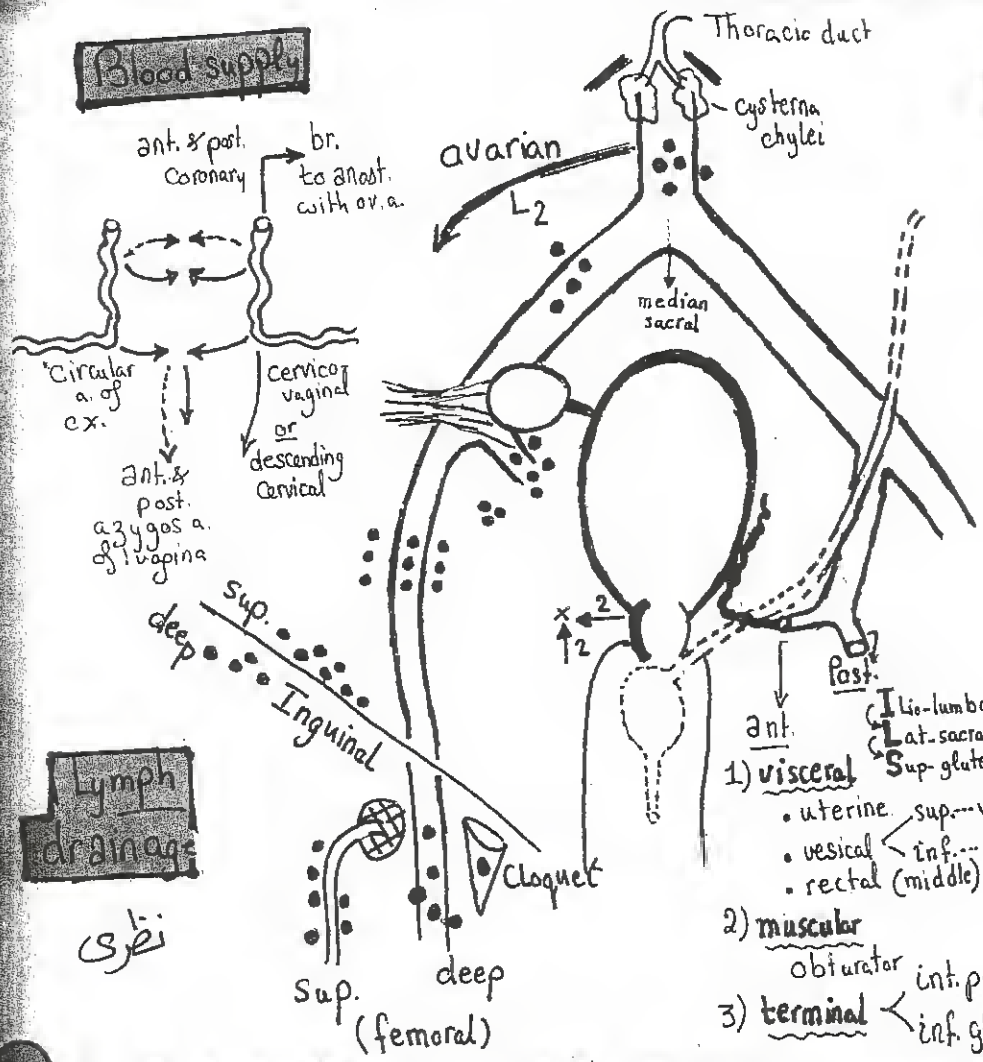

Lymph drainage

نظري

pelvic ureter

12-15 cm

- Surface anatomy
- Sites of possible injury
  1. Hysterectomy < abd. / vag.
  2. Pelvic LN
  3. Bilat Int. iliac a. lig.
  4. Adenexectomy
- Injury is ↑ed by
  - Distorted anatomy < cong / acquired
  - Rapid blind clamping
- Injury is ↓ed by
  - Preoperative: IVP
  - intraoperative: clamping should be < near ! uterus / under vision
- Injury < direct / indirect / fistula / obstruction

Pelvic Support

1. AVF
2. Lig.
3. Pelvic floor
   - peritoneum
   - pelvic fascia
   - pelvic diaphragm
   - Perineum

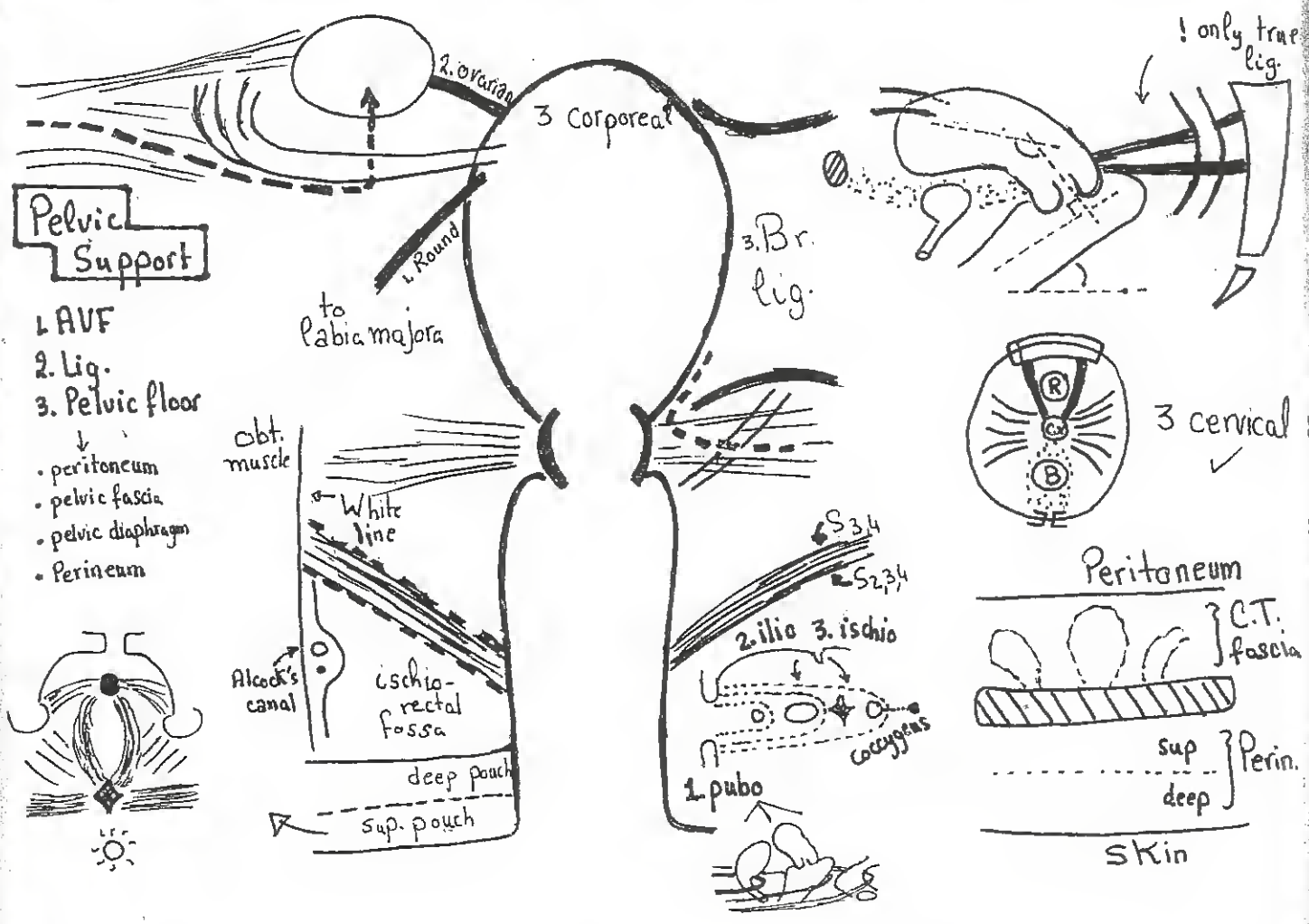

Horm.

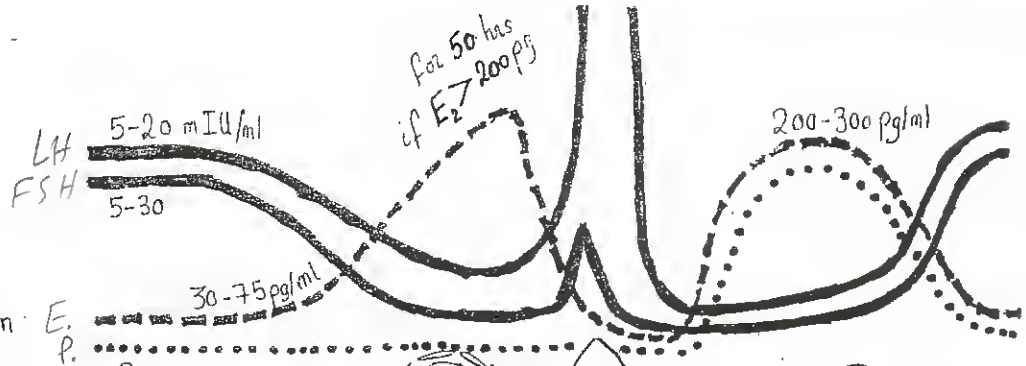

ovary

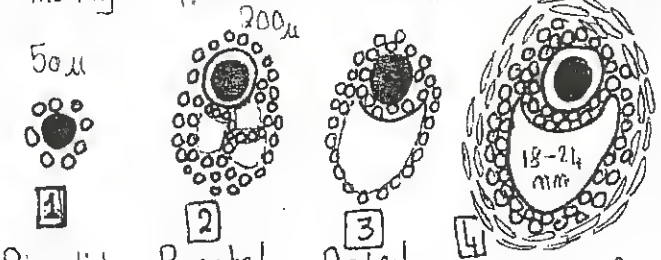

1. Primordial follicle
2. Preantral follicle
3. Antral follicle
4. Preovulatory f.

- oocytes (arrested in prophase of 1st meiosis) + single layer of granulosa
- 2 cell theory: LH → ↑ A (theca); FSH → ↑ E (gran)
- ↓ Zona pellucida + liquor folliculi appears (prevent excess growth of ovum)
- ! Dominant follicle → escapes atresia d.t. ↑ed FSH R
- ! mature Graafian foll. = 9 layers → resumption of 1st meiosis: 1ry oocyte, 1st polar b.

ovulation
- LH surge
- a small FSH surge
- LH → androgens
- mech. of ovum extrusion
- surge is short lived

- Proliferation
- Vascularization ✓✓
- Luteinization
  1. Gr → Lutein
  2. theca → para-lu

if no preg. → regression (14 days)

if +ve preg. → CL of preg. (12 wks)

uterus

1. Cells
2. Glands
3. Stroma
4. vessels

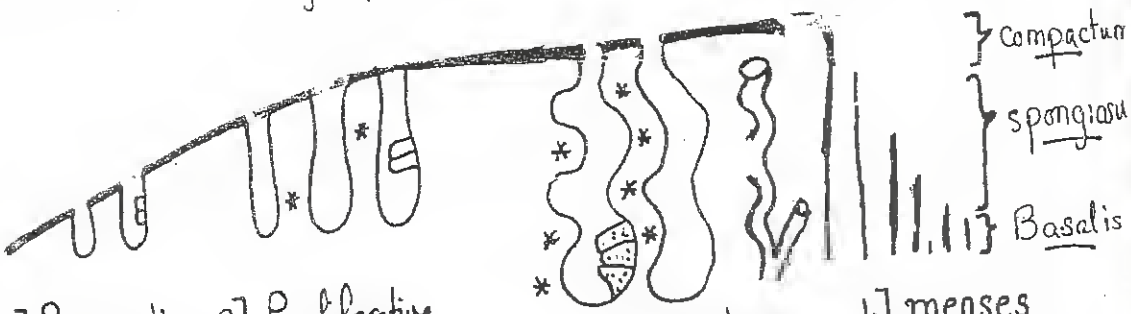

1] Regeneration — 1-2 days, 1-2 mm

2] Proliferative — 9-10 days, 3-4 mm

3] Secretory — 14 day, 7-8 mm

4] menses — 3-5 wks; 3-5 days; 50-80 cc

Cx

wetting ..... excessive
+ve Fern .... clear watery
+ve SpinBark ... stretchable

- scanty
- cellular
- viscid

vag.

1) Superficial cells
2) acidophylic cytoplasm
3) Dark pyknotic nucleus

1) intermediate
2) Basophilic
3) Clear vesicular

Prog. withdrawal → ↓ edema → shrink of end. → coiling of vessels → ischemia → break lysosymes → $PGF_{2\alpha}$ → more ischemia (4-24 hrs) → shedding of str. (compact. / spong.)

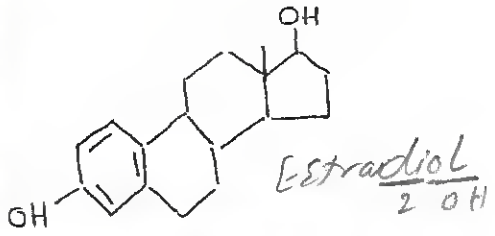

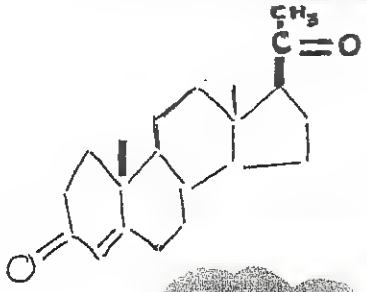

Estrogen 18

A] **Natural**
- E_2 // Estradiol
- E_1 (metabolite of E_2) — Estrone
- E_3 (pregnancy) — Estriol
- E_4 (fetal) — Estetrol

Source: Glands / P. conversion from androgen

Both are
- Bound (99% SHBG)
- free level (1%)
- metab. in liver (prog..... pregnandiol)

B] **Semi-synthetic**
- Ethinyl estradiol
- Mestranol — methyl-Ethynyl-Estradiol — Smethyl EE

C] **Synthetic**
- Stilbesterol
- D.E.S.
  - vag. adenosis
  - pat. int. os
  - T-shaped ut
  - tubal anomalia

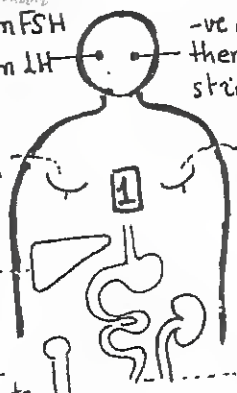

Progesterone 21

A] **Natural**
- ovary (C.L.)
- Placenta
- supra-renal (small amount)

B] **Synthetic**
- 1st
  - estrane .... Nor
  - pregnane .... MPA
- 2nd — levonorgestrel
- 3rd
  - Desogestrel
  - Gestodene (gynera)
  - Norgestimate

Uses

1] To improve vulva & vagina
- Prepub., post menop. V. vaginitis
- Vulval dystrophy
- Trophic ulcer in prolapse

2] ERT → T.F.S.

3] Bleeding → Acute

4] infertility → with clomid

5] Contraception → emergency

both:-
- C.O.C.
- H.R.T.
- D.U.B.
- P.M.T.

1] Obst.
- Abortion
  - threatened
  - C.L.I
  - habit. ab.
- Before surgery during preg.

2] Gyna
est. عدو ال
أي مرض ناتج عن
Hyper-est.

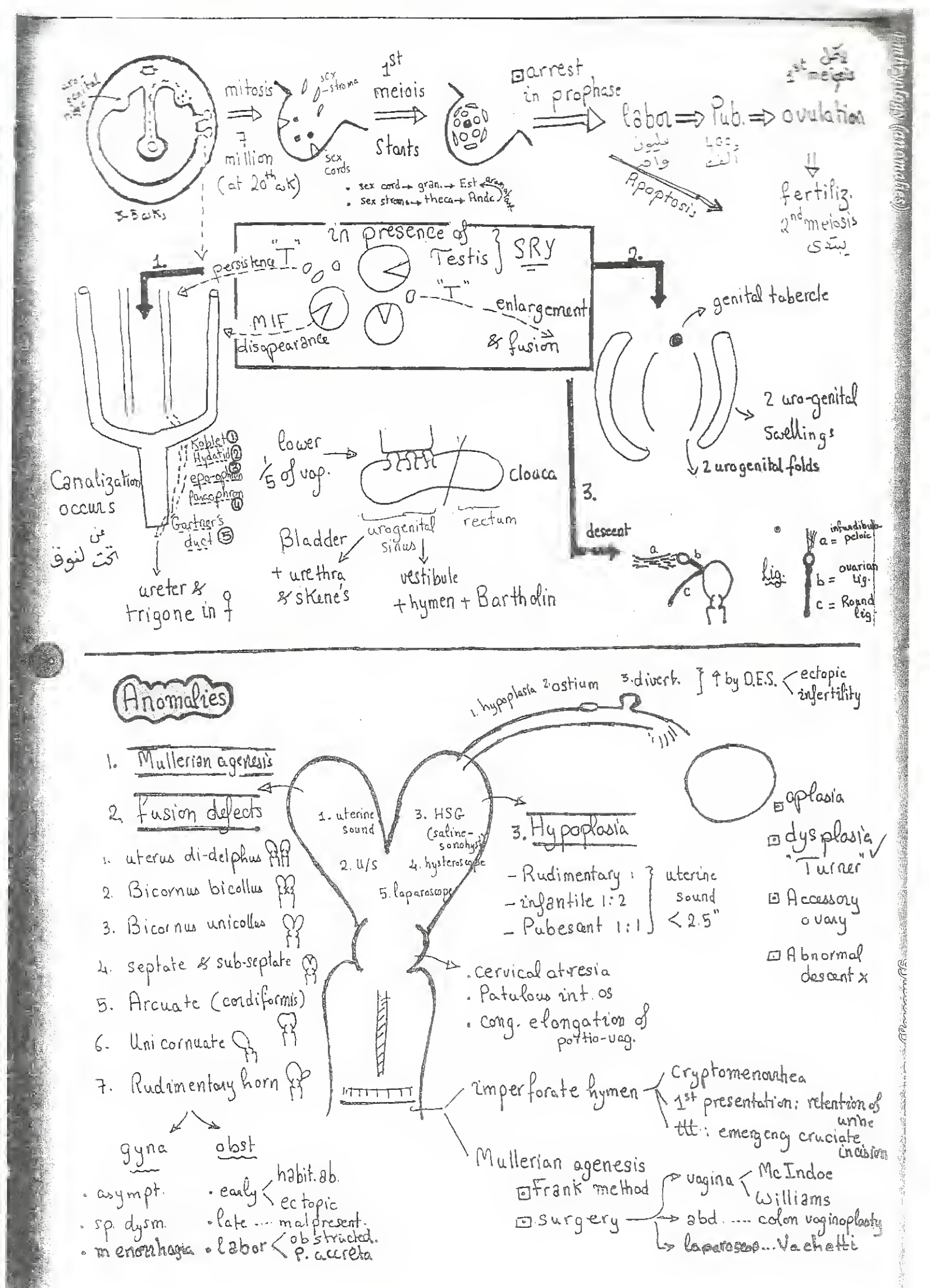

Anomalies

1. Müllerian agenesis
2. Fusion defects
   1. uterus di-delphus
   2. Bicornus bicollus
   3. Bicornus unicollus
   4. septate & sub-septate
   5. Arcuate (cordiformis)
   6. Unicornuate
   7. Rudimentary horn
      - gyna
        - asympt.
        - sp. dysm.
        - menorrhagia
      - obst
        - early < habit. ab. / ectopic
        - late .... malpresent.
        - labor < obstructed. / P. accreta
3. Hypoplasia
   - Rudimentary 1:1
   - infantile 1:2
   - Pubescent 1:1

   } uterine sound < 2.5"

1. uterine sound
2. U/S
3. HSG (saline-sonohyst)
4. hysteroscope
5. laparoscope

1. hypoplasia 2. ostium 3. divert. } ↑ by O.E.S. < ectopic / infertility

- aplasia
- dysplasia "Turner" ✓
- Accessory ovary
- Abnormal descent ✗

- cervical atresia
- Patulous int. os
- Cong. elongation of pottio-vag.

Imperforate hymen
- Cryptomenorrhea
- 1st presentation: retention of urine
- ttt: emergency cruciate incision

Müllerian agenesis
- Frank method → vagina < McIndoe / Williams
- surgery → abd. .... colon vaginoplasty
- → laparoscop... Vachetti

Inv. | Menop. | Phys. changes | Clinical sympt. | effect | HRT | Drugs

Menop.

- Permanent cessation
- occurs gradually
- diagnosed retro-spective

Phys. changes

- sudden sense of heat
- d.t. hypoth. instability
- from twice/d .... every 15 m
- disappear spont. (1-2 yrs)

Clinical sympt.

! annoying sympt. (10%)

Hot flushes ---- vaso-motor symptoms ---- ⇩ 75% but...

Hirsutism ---- skin

↑ LH .... ↑ androgen

Br. atrophy ---- disfigurement ---- ⇧ slightly ?!

↓ E_2 .... ↑ androgen (↓ SHBG)

CVS ---- CHD, Hypert. ---- ⇧ Significantly

- ↑ LDL, ↓ HDL
- ↑ cholest. → atherosclerosis
- Risk f. :- +ve FH, obese, DM

- DVT
- myocard. infarction

Hormones ---- Psych. ---- no proven effect

- ↓ ovarian E & P
- Test... same levels → E_1 ✓
- ↑ FSH (mainly) & LH

Osteoporosis ---- Rh. pain, Backache, Dowager's hump ---- ⇩ 30% but....

- progressive bone resorption
- ↓ BMD: L. vert., femur neck, distal radius
- Risk f:
  - +ve FH, cigarette, alcohol
  - sedentary life, liver, kidney
  - drugs: heparin, thyroid, steroid

Genital ---- Discharge, Dyspareunia, SUI & cystitis ---- ⇩ esp. with local drugs

& suppat → prolapse, SUI

& urinary → reccurent infections

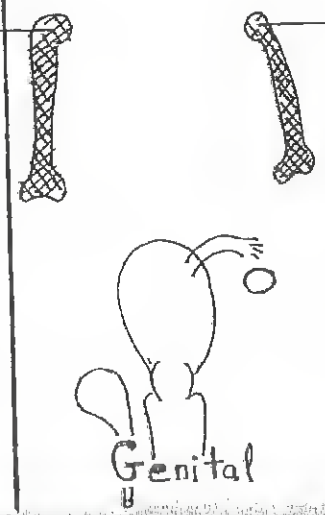

- Triglycerides
- cholesterol
- LDL الردئ
- HDL الكويس

⊛ lipid profile

to confirm

✓ * FSH > 25-40 mIU/ml

* E_2 < 20 pg/ml

* vag. cytology

⊛ DEXA > 2.5 SD

- T score (adult)
- Z score (old age)

U/S على الكلى ...

urine collagen ...

effect

- WHI study
- one million study

HRT

Work up < start

- History
- Ex. (BP., Br., P.V.)
- inv. → sugar, mamogram, lipid profile

Duration

- Some .... 10 yrs
- some ... for life
- recently .... max. 2 yrs

Mech. of action

⇩ cholest. deposition

⇧ HDL, ⇩ LDL

However, it

↑ clotting factors

↓ antithromb. III

⇩ effect of parath. on osteoclast

⇧ Ca abs. & bone loss

indication

1. menop. synd.
2. Asympt. f but high risk <
3. Routine for all fs

Contraindication

القلب — myoc. infarction, DVT, active vasc. dis.

الكبد ... active liver dis.

الرحم ... unexplained bleeding

Drugs

* Hormones

1. Est. only لو شايلة الرحم

   - oral: CEE 0.625-1.25 mg/d.
   - non-oral: estra-derm, estra-gel, Premarin cr., S.C. implant
     - No GIT troubles
     - Higher conc. <
     - No met. effect <
     - No DVT

2. E + P لو الرحم موجود

   - cyclic .... withdrawal bl.
   - continous ... amenorrhea ذ ضلال منة

* Non-Hormones

1. SERM (tamoxifen)
   - +ve on .... CVS & bone
   - -ve on ... uterus & breast
2. Tibolone (livial), weak
   - estrogen ... -ve ut. & br.
   - progest ... no need to add it
   - androgen ... +ve bone & lipids
3. Hot flushes (agreal) or clonidine patch, phyto-estrogens
4. osteoporosis: Ca, vit D ⊕
   - Biphosphonate (fosamax)
   - Calcitonin (myacalcic)
   - fluoride

	Hypothalamus	Pituitary	Ovary	Uterus
Cong.	* Frohlich * Laurence Moon Biedl * Kallmann	* Levi-Lorain → short, obese	* Agenesis * Dysgenesis (Turner) * Test. fem. $ → *	* Aplasia, hypoplasia → Mullerian agenesis
Tr. Infl. Neop.	- Fracture base of skull - Meningitis, encephalitis - Destructive tumors	....	- oophrectomy (medical, surgical, irrad.) - Mumps, T.B. → Destructive → Secretory - Est. tumors - And. tumors - P.C.O.	* Asherman synd. min. → hypomen, habit. abortion mod. → PTI, Pl. accreta severe → Amen, Infert.
Misc.	* Psychological - severe stress - Anorexia nervosa - Bulimia - Pseudocyesis * Hyperprolact. of hypoth. origin * Postpill amen.	* Empty Sella $ (1ry (Cong.), 2ry (after surg.)) Galact. amen. * Simmond $ panhypopit. * Sheehan $ after severe hge.	Andr. ROS Prol. P.C.O. C.L.I. POF → IUFS 1] E → prolif. 2] P → secr.	Adeno Neuro FSH, LH, TSH, ACTH, MSH dopamine (-ve) → GH, * Prolactin الوحيد
General	* Endocrine (thyroid, adrenal, acromegaly) * General debilitating disease			* Drugs → hormones: - steroids, - androgens, - C.O.C.; → hyperprolact.

Amenorrhea

Path.

1ry amen.

- Constitutional
- ov. dysgenesis
- Mullerian agenesis
- TF $

True: Cryptomen.

False:
- imp. hymen
- vag. septum
- cx. atresia

Phys.

Preg. & lactation

< puberty — menop. >

2ry amen.

Assesment

History

Exam

Gyn

- Anovulation (short period am. followed by PPI, infertility) → Br. (2ry sex. char.), ut.
- Hyperand → hirsutism, signs of viriliz.
- Hyperprol. → galactorrhea, squeeze ! breast

End. (أي غدة)

- Thyroid ↓, Adrenal ↑, GH, D.M. → Tall/short, thin/obese

Local (أعراض المحل ! اختبار)

- 1ry: cryptomen., ambig. genit.
- 2ry: gross pathology, pregnant

General (أدوية) → severe dis.

Inv.

B-HCG (preg. ↓, ↑ ectop.)

Pr. challenge (+ve Anov. e.g. PCO)

Ex Pr. chall (-ve uterus, +ve)

FSH, LH

- ovary (hyperGn. hypogonad)
- Pit. hyp (hypogon. hypogon.)

Amenorrhea

Path

hypoGn. ↑ — hyper Gn. ↑

Hypogonadism

	H.	P.	Ov.	ut.	out-flow tract obst
Cong.	Kallman $	Levi-Lorain $	Turner $	• M agenesis • TFS	- imperf. hymen - Tr. vag. septum - Cx atresia
tr.	fracture base of skull		• surgery • irradiation • chemoth	→ D&C → Peurp. sepsis, septicab, T.B	Amen. ↓ Asherman $
infl.	meningo encephal.		TB. > mumps		
Neop.	cranio-pharyngioma	An↑ (Cushing) Pr↑ (adenoma)	↑E.... ↑An..... Bilat. dest.		
Misc.	• Stress التأثيرات العامة • Anorexia nervosa القهرية • Pseudo-cyesis كرمية كاذبة	galact, amen	↑An. ↑Pr. → POF PCO		
		• Empty Sella $ • Sheehan $ مع severe PPhge			

1ry
2ry

→ non inv. U/S
→ inv. HSG, Hysteroscopy

Adhesiolysis by D&C or hyst. followed by cyclic E & P.

Pre-requisites for normal menst.

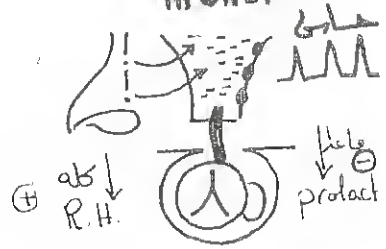

fat 20% ⇒ sex Steroids ⇔ drugs

- ch. 27
- Pr. 21
- An. 19
- est. 18



Phys

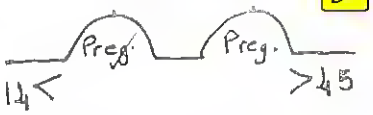

Assesment

history

genital:
- menarche
- Regul. — POF — PCO (<40 menopause, SoHA)
- E. → Breast
- Prol. → squeeze ! br
- galact
- Andr. → central areas, hirsut
- general
- drugs

exam.

inv.

T3, T4, TSH, HCG, Pr.
↓
Progest... anov.
↓
U/S
PCO — Asch. $
CT / Brain

Tt

medical

- induction of ov. ← PCO → lap. ov. drilling
- Cidophage
- (Parlodel) Bromocryptine, Cabergoline (Dostinex) — dopam. ag. ← Hyperpr. → surgery
- Diane, Androcur ← Hyperand → Laser epilation
- L-thyrox. ← Hypothyr.
- Cyclic E+P — Ascherman → adhesiolysis

Surgical

General causes

- OM, T.B
- ⊛ general debilitating dis.
- ⊛ endocrine disorders — hypoth., Cushing.
- ⊛ drugs e.g.
  - Progest..... atrophy
  - COC..... postpill amen.
  - Danagel..... synth andr.

cont. minnur.... GnRH
hyper pr.... Progest.

Hyperprolact.

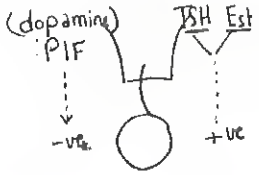

1) Phys.... الحمل والرضاعة
2) Drugs... Anti
3) Pit. adenoma (macro, micro)
4) Hypothyr... ↑ TSH
5) Hypoth..... dest.

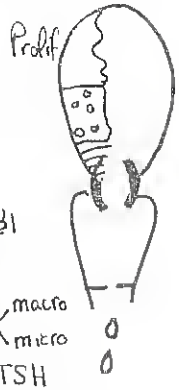

1ry Amen.

false

= cryptomenorrhea
= outflow tract obst

C/O

- 1ry amen
- cyclic lower abd pain
- Pelvi-abd. swelling
- Acute ret. of urine

O/E

Bluish bulging memb.

ttt

surgery: Cruciate incision

true

- H.... نادر
- Pit.... نادر

	Turner ♀	M. agenesis	T.F.S.
• etiology	failure of backward oocyte migration	absent developm of Mull. ducts	Androgen receptor insensitivity
• Karyot.	45xo (أحيانا f...mosaic 45xo / 46xx)	46 xx	46 xy
• Phenot.	<150 cm, web neck, shield ch. ♡ anom...coarct.	Norm. ♀	Norm. & beautiful
• Gonad	streak	ovary	testis (ing. canal, labia)
• hormone	no E_2	E_2	300 ng/dl test. ... Periph. aromat. E_1 30 pg/ml
1) int. genit	infantile	no ut.	no ut.
2) ext. genit	infantile	vag. pouch	vag. pouch
3) 2ry sex. ccc	infantile	Br. +ve	Br. +ve
• ttt	Cyclic E&P for life but not <13 yrs ± GH (8cm)	Vagino-plasty "creation of neovagina" → vag. McIndoe / laparosc. Vachetti → Abd colon-vaginoplasty	. Vaginoplasty ← . Gonadectomy must be done (?) at 18 yrs (?) followed by ERT (?)

☐ No oophrectomy except if Y-chr → malig risk 25%.

☐ - إيه الحيض دورة ؟
- إيه البقى طويلة ؟
- وازاى تشك فيها وقت الولادة ؟

☐ It is an X-linked recessive dis ↳ absent receptors to androgen (end organ insensitivity)

Assesment

History
- false: cyclic lower abd. pain
- true: Breast
  - -ve
  - +ve

Exam
- false: Hymen
- true: Breast
  - -ve .... ccc. of Turner
  - +ve ... ax, pubic hair

Inv.
- false: U/S... Hemato (colpus, metra, salpinx)
- true: Karyotype
- ⊕ U/S
  - no ov....
  - no uterus...

Embryology

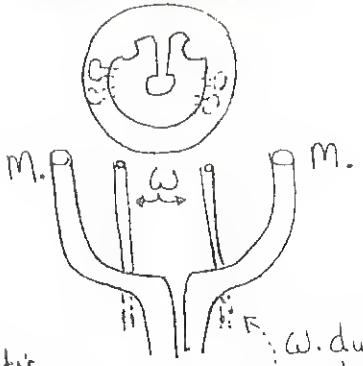

☒ **testis**

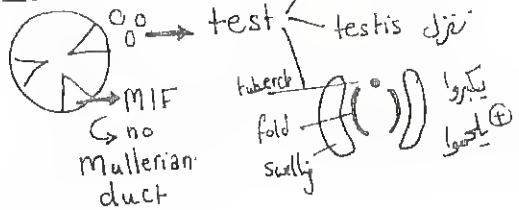

☒ **ovary**

No MIF → M. ducts persists

No test → Wolf. ducts disapear

Hyperandr.

DHT

5αR

1. Constitutional
2. Iatrogenic
3. Pitut. — hyperpr. / Cushing / acromegaly

SHBG
4. Thyroid ?
5. Liver
6. Pancreas
} hypo

7. Adrenal
8. Ovary ✓
} hyper

adren. ovary

Inv
- diagnosis — exclude drug / androgen level
- etiology — ! most serious / Others
- if -ve .....

ttt
- of ! Cause — Surg.
- Drugs
  - ↓T ..... Adrenal: cortisone / Ovary: COC — cyproterone acetate / Spironolactone
  - ↑SHBG (E. in COC)
  - ↓5αR — • Finasteride • Flutamide

PCO

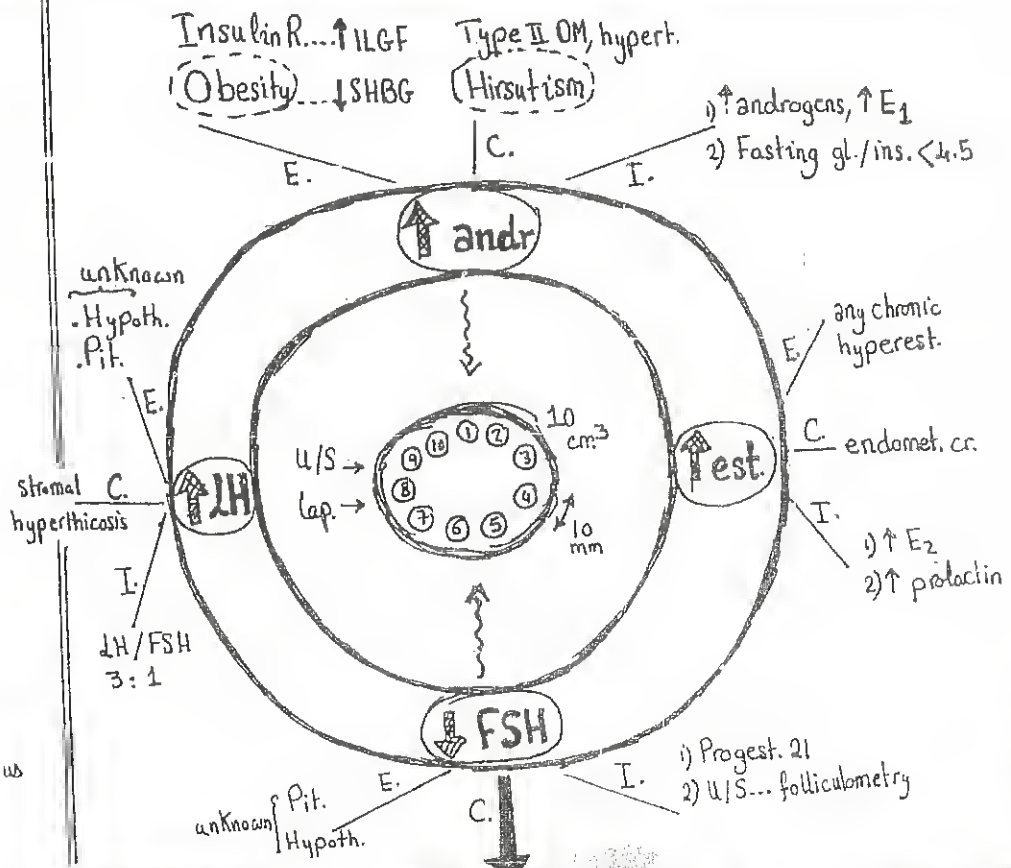

Hirsutism → **Anovulat** ← **Galactorrhea**

Hirsutism:
- ± other skin signs
- ± other viriliz. signs
- + C/P of ! cause

Anovulat:
- Bleeding — C.O.C / D&C / hyst.
- infertility — Clomid / laparosc. / I.V.F.

Galactorrhea:
- ± PMT
- ± Hirsutism
- + C/P of ! cause

Hyperprolact.

↓ dopamine

Physiological .1
Iatrogenic .2
Pituitary .3 — ✓ adenoma / acromegaly / empty S.♀
hypo: Thyroid .4, Kidney .5
irritat.: Breast .6
Hypoth. 7.
Ovary 8.
} ↑ prolactin

Inv
- diagnosis — exclude drug / Prolactin level
- etiology — ! most serious / others
- ..... if -ve

ttt
- of ! cause — surg.
- Drugs
  1. Bromocryptine (parlodel)
  2. Lisuride (dopergine)
  3. Cabergoline (dostinex)
  4. Quinagolide (norprolac)

(dopaminergic)

Acc. to cyclicity

1. cyclic < menorrhagia (زيادة الكمية/الدم), Polymenorrhea (متكرر), الاثنين مع بعض
2. acyclic < Metro, meno-metro, intermenst., contact bl.

Acc. to hormones

1. Withdrawal
2. Breakthrough

Acc. to pattern

	Local	syst.	funct.
1. Meno	congenit.	أي حاجة	ovular
2. Poly	congin ov.		ovular
3. Metro	tumors + ulcers	الأدوية بس	anovular

4. contact bleeding : Cx – vag. < inf., tumor

Acc. to age

- Neonate : birth crisis
- childhood : F.B., precoc
- Puberty : DUB, coagulopath
- CBP : الحمل + وبالل مع الحمل
- Menopause : D.U.B, fibroid
- Post-meno : cr. endomet.

[* most common →
[* most serious →

Organic

Assessed by

[1] History

- Age
- marital status (مشاكل الحمل)
- HPI
  - Pain, bl., infert. = EØ
  - SOHA
  - something protrudg
  - fever + pain + disch.
- Menst < cyclic, acyclic
- obst. if recent TOP → chorioca.
- Contr. → horm. (لولب)
- Past → general cause

[2] Exam.

- General < درجة الانيميا, dis. أي, metastasis
- Abd. – swelling (حمل؟)
- Local < PV, PR

[3] Inv.

∝ < lab. --- CBC; scan --- U/S; scope; biopsy --- D&C.

(*) General

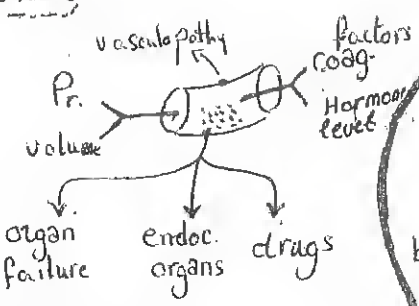

[1. intact HPO
[2. local PG

[1. C.L.... الطبقات
[2. ↑H.... no bleeding

(*) Local ↑ vascularity

- Pregnant < early, APhge, PPhge
- Pelvic path.
  - Cong : double uterus
  - trauma : obst. / surgical
  - infection : acute / chronic
  - Tumors : benign / malig.
  - Miscell. : Prolapse, RVF, chronic inv.

functional = D.U.B. < Puberty, menopause (حول)

Cyclic : Ovular

مشكلة في التوقيت

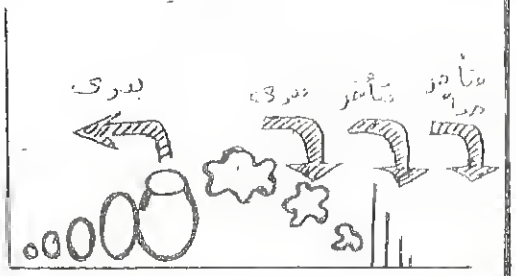

- Polymenorrhea → frequent cycles
- irreg. ripening → Premenst. spotting (C.L.)
- irreg. shedding → Postm. spotting
- Persist C.L. → • am. → • pain → • bl.

menorrhagia

tt:
- if she doesn't want preg.
  1) Prog. in 1st 2nd half
  2) C.O.C. is easier
- if she is also infertile
  1) Clomid / HCG
  2) ART if failed.

Acyclic : Anovular

Metropathia Hgrica ✓

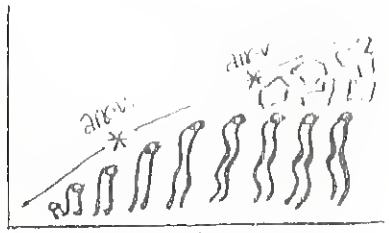

short period of amen. ⟹ P.P.I.

- TVUS < large uterus, follicular cyst
- D&C < protif / hyperpl., no sec changes

tt:
1. Drugs
   - الزيت → Fe, folate
   - Well → Prog. / COC. / Androge / GnRH cont.
   - Infertil → induction of ov.
2. D&C < diag., therap
3. Hyst. → الحل hysteroscopic ablation

Spasmodic < 1ry idiopathic

Def.: spasmodic (colicky) pain with No organic pelv. path.

C/P

1. Type of pt.
   - Age: - 2-3 yrs after menarche; - improves after 25 yrs } only in ov. cycles
   - Parity: • more in virgins (sedentary life) • improved after labor (cx. dil.)
2. Type of pain
   - site ... lower abd. spasmodic → lower limb
   - time ... 1st day → ↓ after 24 hours
   - association ... N&V, diarrhea, sweating, facial pallor

etiology

1. excess PG
   - as they occur only in ov. cycles
   - PG intake → painful ut. cont.
   - explains associating Sympt.
2. retained menses
   - → obstruction ... cx. stenosis
   - → hypoplastic ... uterus
   - → disturbed ... polarity

ttt

⇒ General
- Reassurance ... إنتي أحسن
- avoid emotional dist., sedentary life, smoking

⇒ Medical
- anti-PG ✓✓
- C.O.C. (لما تغلب) ... E → ↑ development; P → Relax uterus

⇒ Surgical (معمولة!!)
1. D&C < dilates ! pathway; lacerates paracerv. Symp. (لكنها بتريح كاتر)
2. LUNA (presacral neurectomy) cuts motor, sensory nerves (لكنها عملية كبيرة وممكن تتور ureter, vessels)

Congestive (2ry)

Def. cont. dull aching pain 2ry to p. pathology

C/P

1. Type of pt.
   - Age ... > later in life
   - Parity ... > in MP
2. Type of pain
   - site ... lower abd. + backache
   - time ... 3-5 days before menses → gradual ↓ with time
   - association ... menorrhagia, Polymenorrhea, vag. disch.

etiology
- Cong. ... ut. anomalies
- infl. (على فكرة نفس أسباب الالتهاب)
- neoplastic
- miscellaneous < displacement; functional (simple) (↳ anxiety, constipation, coitus interruptus)

ttt
1. of ! cause ✓
2. Analgesics
3. Glycerine (↓ constip.) icthyol supp. (↓ congestion)

Membranous	Ovulatory	2ry spasmodic
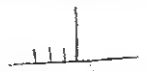 severe pain with scanty flow (في الأول) followed by passage of large end cast ! - increased flow - relief of pain	Mittleshmertz: fluid, PG; ± mid cyclic < discharge, spotting (ممكن يبقى معاها N&V بيفكروها زايدة)	crescendo (endometriasis)  always in pain

PMT



Def.
- Presence of cyclic sympt. ≈ 150
- Both < Physical, psych.
- in ! luteal phase ∴ should be ovulatory [relieved by menses, not present in ! follicular phase]
- in ! absence of dig pelvic path.

etiology (imbalance of)
1) serotonin, β end.
2) ↑E/↓P ratio
3) vit. B_1 B_6 def.

C/P
- Psychological & mood dist. (PDD) 5% (ممكن تتغير أو تموت جوزها) ... ± tranq., antidepressant, ± psychotherapy
- Mastalgia ... Dopamine agonists + vit. B_6 (pyridoxine) 100 mg → ↑ serotonin, dopamin
- abd. distension, N&V, diarrhea, constipation ... anti-PG
- edema of face, ↑ weight (salt & H_2O reten.) ... ↑ sugar, ↓ salt in diet; linolenic acid derivative (primarose); Diuretics ... spironolactone 25 mg 1x3
- joint pains, ms cramps

ttt Reassurance (إنتي أحسن)

inhibition of ovulation (آخر حل ممكن يبقى)

- ↑ Prolactin
- ↑ PG
- ↑ ADH, aldosterone; High salt, low sugar diet
- ↑ PG

1 Etiology — 2 Assesment — 3 ttt

Cong.	Tr.	Inf.	Neop.	Misc.
I H.P. failure	II H.P. dysfunction 1ry ✓ (PCO)	III ovarian failure	Others. • Prolactin↑ • androgen↑ • CLI • LUFS	
-hypoplasia -diverticul. - ostrium	surgery on / near	PID 2ry ✓✓	stretching tube fib. / ov. cyst	EØ < anatomy / function
• Mullerian agenesis • TFS	↘ Ascherman	↙	fibroid	displacement
Atresia	• cauterization • amputation • conc biopsy	chronic cervicitis	Polyp	Poor cx mucous 1. wrong time 2. ↓ gland < surgery / clomid 3. infection 4. immunolog
Septum	surgery, scarring	hostile sec.	rare	Abs < agglutin. / immobiliz
hypospadius epispadius	spinal surg. ↳ retrograde ej.	DM		• impotence • premature ejac.
- Cong. abs. vas - cystic fibrosis - Kartagner S	surgery (Hernia)	• epididmitis • Prostatitis ✓✓	rare	
• Sertoli cell only synd. • undesc. T. • Klinf. S.	• Direct • Thermal ✓ • irradiation	Mumps	rare	2ry test. failure (Low FSH)

History

- disch. / pain / spotting — "E" ⇐ mid-cyc. — "C.L." ⇒ Regular / sp. dysm. / PMT
- ± genital endoc. < am.... PPI bleed / galactorrhea / hirsutism
- ± general endoc. أعراض أي غدة
- Previous surgery
- PID < fever / abd. pain / discharge
- EØ < Pain / bleed / infertility — 6D
- previous surgery < D&C / C.S.
- fibroid (ABCDE PPP)
- postpartum < hge (sheehan) / inf. (Ascherman)
- Purulent discharge
- Low back-ache
- deep dysparuenia
- sexual H. < dysparuenia / frequency / use of lubricant
- DM
- anti < hypert. / depressants
- → urethral disch.
- → previous surg.
- cytotoxic drugs
- irradiation
- anti < fungal / malarial

Invest.

- Folliculometry — G. / T. / L. — LH — Prog. ✓
- laparoscope — Tuboscope — T. cannulation — 2nd-3rd Post-menst — insufl. — HSG — HyCoSy
- 1- 2- 3- 4- 5- 6-
- mid-cycle — N. semen — PCT → mucous: Moghisi scor; sperm: 5-20 forward
- if -ve → sperm penetration < slide / tube
- semen < 20 / 30 / 50
  - Azo → Test. biopsy → +ve → obst.; -ve → ↓c FSH → 2ry failure → Karyotyping; ↑ FSH → 2ry failure → CT brain
  - OTA → C&S; imm. assay

ART آخر حل لو فشلنا

- {induction of ovulation}
- PEB — Spinbarkeit, Fern
- vaginal cytology
- • Tuboplasty — laparos. / laport. / hysl
- • EØ < ind. of ov / surgery
- Surgery
- • inf. → Antib. / cauter.
- • Imm. → cstds
- • Poor → E
- impotence:
  - Psychotherapy
  - sung. Correction
- OTA
  - antibiotics
  - mucolytics
  - steroids
  - ⇓ AIH (if failure)

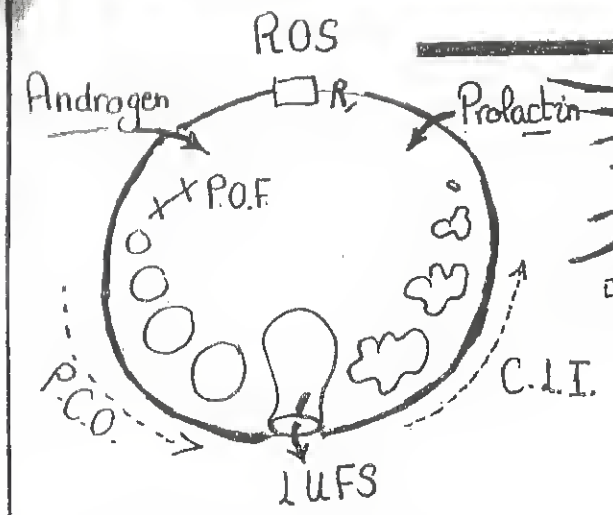

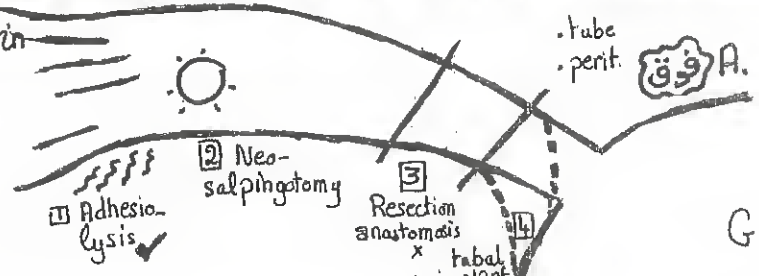

Clomid ± HCG

50 mg 1x2x5 starting on 2nd day up to 250 mg

* Natural: Professi, Pregnyl
* DNA → ovidrel

5.000-10.000 IU when 18-22 mm, 1000-1500 pg/ml

x failure < other cause, Poor mucous, CLI, LUFS
x Others - parlodel, dexam. - $T_{3,4}$, nalotrexone

FSH LH

- Better results, but more < expensive, side effects
- Different schedules

urine → Humegon ---- I.M.
→ Metrodin ---- LH < 1 IU

DNA → Puregon ---- S.C.

GnRh

only if given pulsatile < nasal spray, pump

Side effects

1. Multiple preg.
2. Abortion, PTL
3. Ectopic
4. OHSS
   - esp if HCG
   - rare with clomid
   - never with GnRH

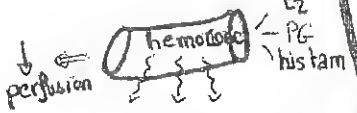

extravastion

a) mild --- home
b) mod.
c) severe } ICU

follow up: ov. cysts, ascite pl. eff, elect. imb., coag. profile

No < diuretics, laparotomy

جديد < heparin, albumin

6. Luteal Phase Support

- Cx < inf., imm.
- unexplained

B.

1. super-ovulation

long protocol: GnRH cont..... ⊖
short protocol: FSH... HCG..... ⊕

2. ovum pick-up — vag. guided U/S

GIFT
ZIFT
E.T.
tube
uterus
5.

I.V.F. 4. Microinsem

ICS
SUZI

3. sperm processing

→ Anti-PG
→ Washing, centrifug
→ mucolytic
→ Caffeine, Kallikrein
→ Antibodies

C.
.OTA
.impotence

MESA
TESA

better to be combined with induction

IUI

A.I.

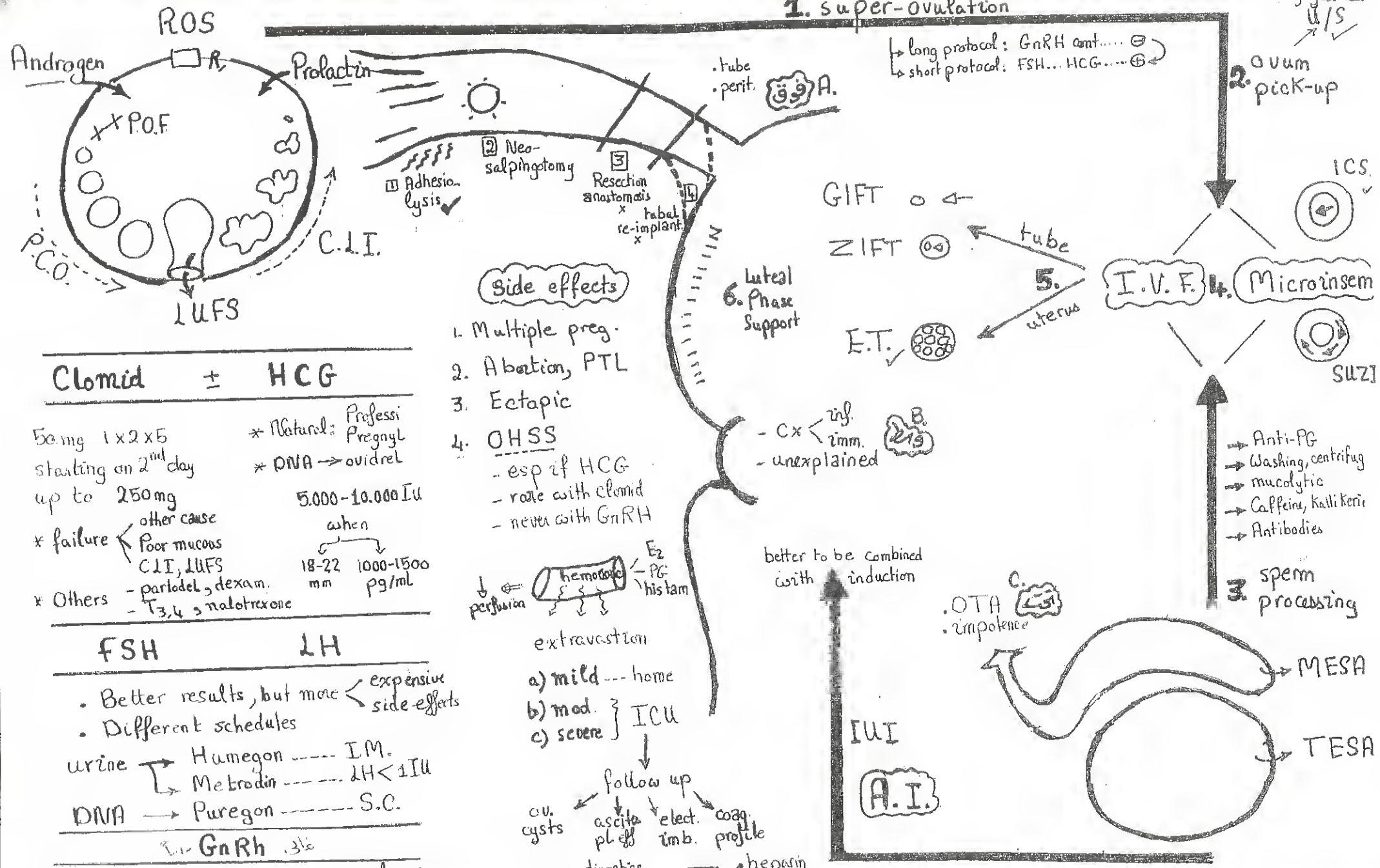

Clomid ± HCG

50 mg 1x2x5 starting on 2nd day up to 250 mg

* failure < other cause / Poor mucous / CLI, LUFS
* Others - parlodel, dexam. - $T_{3,4}$, nalotrexone

* Natural: Professi / Pregnyl
* DNA → ovidrel

5.000 - 10.000 IU when 18-22 mm, 1000-1500 pg/ml

FSH LH

- Better results, but more < expensive / side effects
- Different schedules

urine → Humegon ----- IM. / Metrodin ----- LH < 1 IU

DNA → Puregon ------ S.C.

GnRh

Only if given pulsatile < nasal spray / pump

	Gonorrhea	B. vaginosis	Chlamydia	Candidiasis	Trichomonas	HPV	T.B.	Lo.
Org	G-ve IP 3-7 days	- H.vag (Gard. vag) G-ve - mycoplasma - ureaplasma	virus → bact. DNA RNA Abs	spores, Hyphae, mycelia Albicans, Trop, Krusei	pus cell	DNA II > I 70 serotype	Mycobacterium tuberc. > bovis	Schistosoma haemat. > manso
Path	• Adult ... STD • child ... contamination من فوط أطفال • Neob ... وقت الولادة ophthalmia neonatorum	60% of valvovag. replacement normal flora e.g. lact. bacillus ALK. medium	15 serotype * ABC ... trachoma * D-K ... STD • col. epith. (G) ↓ • preg. ... سلبي • neoborn • male ... سلبي * L123 ... LGV	(20-40%) Normal habitant (50%) acidic + humid ↓ الحل -COC • certain media • ↓ resistance • loss of balance antibiotics alk. ↓	Preg. neoborn retention 2ry inf. 1ry → صعبة 2ry → خفيفة • fever ... -ve • L ... -ve • painful vesicle-ulcer	recurrence in 60% cr.cx 16, 18	• Blood borne ✓ • Peritoneal • lymphatic • descending with semen	through Recto-vagino-cervico plexus of veins
CP	spread FHC 2ry PID 1ry M.P. discharge	osis ✓ → discharge only → fishy excessive greyish itis ✗ → asympt. → 50% → No - PPdd - pus cells	edema → fibrosis → stricture L.N. matting fistula	pre ... Menst ... post PPdd odorless ... Disch ... malodorous curdy white ... yellow frothy red with adherent white patches ... O/E ... strawberry vagina Colposcope	6 ... 11 condyloma • accuminatum • flat (cervix) • inverted	100% ... c/P of ch. PID 50% 5% * Tubercles * Caseation * Polypi * ulcers	rare * Polyps ✓ * Sandy patch * calcif. * ulcers 100%	
Inv - Ph - Smear - C - & - S	(endocx) 1ry sites (rectum, pharynx) 2ry sites مين ؟ Thayer Martin New York city Elisa شرايط CFT, HAI	... > 4.5 ... Clue cells ... Whif test (10% KOH)	oil immersion field inclusion bodies + > 10 pus cells ... MacCoy ناخد وقت ... ELisa أسرع ... PCR دقيقة لكن أغلى	< 4.5 ... Ph ... > 4.5 +ve ... Gram ... -ve أوامت ... Fresh drop ... أوامت Culture Sabouraud NicKerson Diamond Feinberg Trichocle	eosinophilic IN inclusion bodies multinucleated giant cells * culture on choriallantoic membr.	vacuolated multinuclear cells Koilocytes malig. الشبه ∴ colposcopy, Pap stain biopsy	G. < chest x-ray, ESR HSG lap. Zeil Nelsen Low. J. G.P. inocul. biopsy	G. < urine, stool, ova - Biopsy - Endoscopy (Laparoscopy) - CFT
Tt	* Procaine penicillin 4.8 IM + 1 gm probenecid * Spectinomycin 2gm IM * Rocephin (ceftriaxone) 250mg if chronic → surgery 1. Barth. 2. cervicitis 3. PID	ليه نعالج ؟ Comp. = septic focus — Gyna & obst * Clind. 300 1x2x7 * Flagyl 250 1x3x7 Erythromy or Tetracyclin 500 1x4x7 esp. if ← + chlamydia	Azithromycin 1 g. single dose أي حاجة mycin	alkaline douche ← Prophylaxis → acidic douche Drugs L. 1) mycostatin 2) canestan 3) Gynodaktarin L. Flagyl 500 S. 1) Flagyl 2) Tenidazole 3) Ornidazole S. Diflucan, Sporanox Recurrence دور على السبب — طول مدة العلاج مانع التوعية — بلاش تتطنش	• painful ... sympt. • 2ry inf ... Abs • Anti-virals: Interferon, a/vata/fam cyclovir	1) Chem. cautery - Trichloro acetic acid 75% - Podophylin resin - Imiquimod 2) Cryocaut. 3) Surg. excision	• Isoniazid 5 • Rifampicin 10 • Ethambutol 15 * No tubal microsurgery	• Biltricide (Praziquantel) • Amblihar + surgical excision of vulval polyps

Etiology

1. Org.
   - Non-specific: staph, strept
   - STDs: monilia, TV, viruses, gon., chlam.
   - chr. gr. dis. TB
2. Pdf
   - obst. < labor, abortion
   - gyna < D&C, IUCD [↓ed by] Barrier, COC
   - S.I. < Backwg. flowing, Reviving
3. Route
   - direct
   - blood e.g. TB
   - ascending: lumen, lymph.
   - Perisalpingitis (nearby)
   - endosalpingitis (lumen)
   - interstitial salpingitis (lymphat.)

Pathology

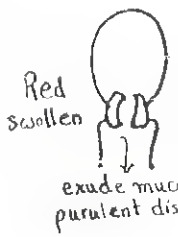

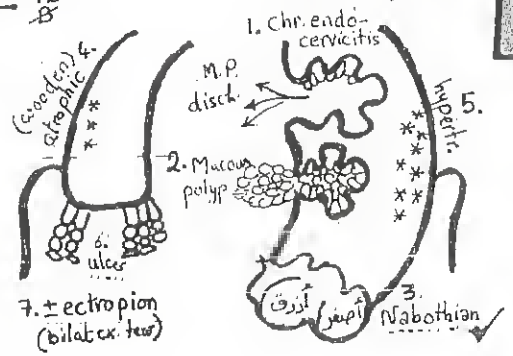

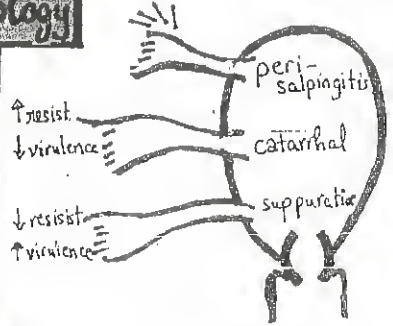

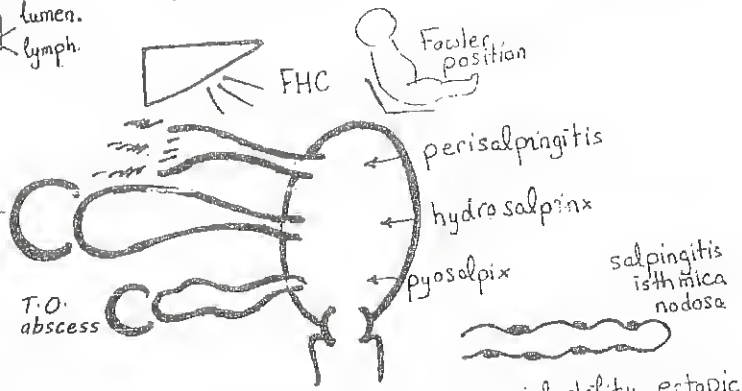

C/P

G.....
A.....
L.....

- FAHM-R
- backache
- discharge

- toxic look (usually asympt.)
- congestive sympt. < pain, bleeding, discharge
- tender mov. of cx ± any path. form

- FAHM-R
- Cong. sympt < pain (T, RT csp. 3cm above mid-ing. point), bl. disch
- tender mov. of cx ± tender adenxae

- toxic look, ill health
- ⊕ history of < infertility, ectopic, previous acute PID, TB, menst. irreg. ↑↓
- Cong. sympt
- TO mass (complex), fixed RVF

chronic (مقلب)
- Racemose glands
- no monthly shedding
- Glands are deep (صعب توصلها ال abds.)

chronic cx
- infertility: hostile cx mucous
- Preg.:
- Spread: septic focus < local, general
- Malig.: ?!

Comp.

chronic (مقلب) ..... comp

- 40% gonorrhea (زمان): more acute sympt ∴ early diagnosed
- 60% chlamydia (الآن): more asympt ∴ damage later on

comp:
- infert.
- ectopic
- spread

all 1 major ⊕ criteria ⊕ one minor

- lower abd.
- adnexal
- cx motion

- Temp > 38, ↑ TLC, ESR
- mass (PV, US)
- org ± pus (swab, laparosc.)

Inv.

- ↑ TLC, ESR, CRP
- cervical swab

- Post-coital (infertility)
- Colposcopy (malig.)

- ↑ TLC, ESR, CRP
- cervical swab < chlamydia ?!, gonorrhea ?!

- U/S → adnexal mass (& follow up! size)
- ✓✓ Laparoscope < if diagnosis is uncertain, if no response in 48 hrs
  - edema
  - hyperemia
  - sticky exudes

Ttt

proph. — medical — Surgical

proph.	medical	Surgical
1. A	1. A	Cautery: - electro, - cryo, - chemical, - laser
2. A	2. A	surgery: - conization, - amputation (لو فاتح), - hysterectomy (صعب)
3. A	3. A	

Proph.
1. A
2. A
3. A

medical
1. A
2. A
3. A
look

Surgical
- pelvic abscess → post-colpotomy
- small T.O. abscess → aspiration < U/S, laparosc.
- laparotomy
  - drainage: if pus
  - removal: if mass
    - old → TAH+BSO
    - young → adnexectomy → ICSI

Cervicitis

D. D. of Leuchorea

excess of ! N. disch
- phys : ⇑ H. Premenst, Pregnancy
- Path : any path → pelvic cong.

D. D. of contact bl.

CIN : الأخطر

- Cx
- vag

} inf. tumors

polyp

D. D. of barrel shaped cx

cx
- ectopic
- abolition

- cx fibroid
- cx cancer
- chr. hypertr. cx

D. D. of LGT ulcers

- Traumatic : episiotomy, pessary
- infl → STD
  - chr. gr.: TB, ⊘, ⊘
  - STD: herpes, LGV, chancroid, gr. inguinale
- Neoplastic

Cervical erosion (ectopy)

- Def. : Replacement of ! normal str. sq. epith. of ectocx by → columnar epith → bright red area
- etiology : chr. cervicitis; Cong. (rare); hormonal (common) < Preg, COC
- Sympt : leuchorrhea, contact bL.
- exam : flat ..... papillary ..... follicular
- Inv : colposcope .... smear .... biopsy (fear of malig.)
- tt : cervitis : Abs; hormonal : no therapy
  - mainly cauterization < electro, Cryo, Laser ✓

Vulvo-vaginitis

Normal flora

	G + ve	G − ve
Aerobes	Lactoacid., staph aureus, GBS, Ent. fecalis, Diphthemids	E. coli, Klebsiella, Proteus, enterobacter, Pseudomonas
Anaerobes	peptostreptococcus, clostridium, Gardnerella	Bacteroids, Bacillus fragilis, fusobacterium
	⊕ Candida	⊕ T. vag.

defensive mech

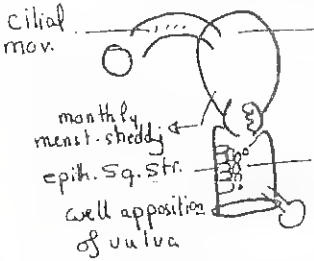

3 g lands are racemose to ⇑ its sec (humoral imm) < Barth., cx, tube

PH 3.8 - 4.2 ! main defense ✓

Pdf for inf.

1) M. → ↓ immunity < steroids, Anbcts

2) L. ↓ Acidic ph < Pre-pubertal, Post-menop. } vulvo-vag.

3) ext. < Sex. IC (esp. multiple part.), F. Body (tampoon, IUCD), vag. douche (alter ph)

P.I.D.

Congestive sympt.

1. PID (TB) ....
2. EØ .....
3. Fibroid ....
4. ov. mass ...
5. ectopic ...
6. Appdx ...

- menorrhagia
- Congest. dysm.
- leuch.
- dyspar.
- Polymen.
- Dorsal pain

CDC reccomend. for Abc. regimen in PID

Parentral	Oral
A	
2g IV/6hrs cefoxitin / 2g IV/12hrs cefotetan	levo-floxacin 500 → 1x1x14 or Ofloxcin 400
or Ampicillin / sulbactam 3g IV/6hrs	⊕ + 100 mg IV/12 hrs → Doxycycline 100, Metronidazole 500 } 1x2x14
B	
900 mg IV/8hrs Clindamycin	⊕ ceftriaxone 250 or cefoxitin 2gm } IM once
⊕ 2mg/Kg gentamycin (then 1.5 mg/Kg/8hrs)	

indic. for surgery
- no improv. for 72 hrs
- formation of abscess
- Diag. is uncertain

hospit. indic for
- ⊕ Nulliparity (affection of fertility)
- severe cond. (TO mass) — large ruptured
- Immunocompr.

if infertile
Removal of tubes (or clamping) via laparoscopy → ART is better than tuboplasty } مش مهم

	Physiolog.	Mech. & chemical	IUCD	C.O.C.	P.O.P.	Injectab.	Surgical	Emerg.
Types	Safeperiod * Calender * BBT * cx-mucous Lactational amenorrhea	15x3.5 0.02 0.07 non cont. benef. { * ↓ STD, * Ht of immun., * semen collecti. Vag diaph. Disadv. for all - F.R. 3-14 - Allergy - Difficult use - Better combined with chemical - Diaph. → cystitis cx. cap	Inert → 1. Aseptic endomet. ✓ 2. ⇑ PG e.g. Lippes Loop Medicated → Cu±Ag → ↓ ; Prog. (IUS) → ↓ as in POP * sperm * endomet * zygote → CuT380A → Multiload 1-2 / 0.2 . cheap . long use . reversible No local (I.C.) syst. effects . DUB . end. hyper	E. used → E.E. (mestranol) ✗ Norethindr / Norethisteron / Norgestrel P. → 1st → estrane / pregnane : MPA → 2nd ..... Levonorgestrel → 3rd .... Marvelon, gynera, cilest high dose / low dose Monophasic / Biphasic / Triphasic P. / E. / 0.1/tab / ↓PD / Bl. / Pain Side effect / Contraind. P. Headache, mood ch. - Migrane, epilepsy E. engorg. - lactation, Br. mass E: thrombo. - DVT P. Atheroscl. HTN - hypert., smoker, thyrotoxic N&V. ↑ eng. E. cholestasis & gall stones - acute VH, chr. liver I.R. - E+P - DM P. - weight gain ↓ hypomen. amenorrhea ↑ spotting, B.T.B. - undiagn. Bl. amen. Pregnancy * Relation of C.O.C. to tumors. * How to manage missed pill.	(Minipill) Micronor 300ug Microlut 30ug Exluton (Lynestrenol) (P) only . Taken daily . not delayed used in { main is by: mech. thick mucus } lactating ✓ CVS < old, smoker E. contraind. ✓ liver Disadv. . 1-2 / HWY . more ectopic . more spotting	3m DMPA 150 mg Norethisterone oenanthate 200mg 1m Cyclofem, Mesygyna E. was added to ↓ menst. side effects as C.O.C. used in + non-contr. benefits as in C.O.C. Disadv. X تمثيلة (*) not readily reversible (*) ↓ BMD (*) more menst. irreg. esp. amenorrhea	♂ bil. vasectomy - under local anes. - wait for 70 days till 2-ve semen analysis ♀ sterilization . Laparoscopy . Laparot. (Pomeroy) . Post partum ↳ C.S. ✓ ↳ V.O. ✗ indication Permanent social: . >35 yrs, . failed other methods medical: . v. weak scar, . serious illness Contra-indic. Young uncertain couple with marrital / mental probl. Disadv. ① Gyna Post-tubal ligation ② Obst 0.1 - faulty tech 0.4 - recanaliz. - was preg.	Mech. IUCD - Menst. aspiration Hormones * خلال ٧٢ ساعة (morning after) pill anti-emetic * 1] estrogen - EE 2 mg - CEE 2mg 2] POP 75mg (postinor) 3] COC ✓ oural 2 tab. يكرر بعد ١٢ ساعة 4] Anti-Gn danazol 5] Anti-Prog. mifepristone Post-partum c. . Br. feeding . Barriers . IUCD . Prog. only contracept. . Sterilization
Mech. of action	efficacy is ↑ed to 90% by * Amenorrhea * Reg. feeding * no extra-food	cervical cap ↳ for those with vag. prolapse	1. What are alerting symptoms 2. D.D. of pain + IUCD 3. How to insert an IUCD?					
F.R.	Pearl index / HWY Coitus int. / int.	Toxic day shock 24 hrs $ (+) Spermicidals Nono, Octo-oxynol 9 → 15 min < I.C. → I.C. within 2 hrs → No douch 6 hrs F.R. 30/HWY	Not in [Wilson] amen. bl. (+) undiagnosed PID 1.2.3. missed threads 1. perforation 2. intra, extra 3. ↓ expulsion Bl. Pain					
Adv.	No medical contra ind.							
Disadv.	1. high F.R. 15-30 2. limitation of I.C. 3. needs motivated couples 4. safe period (reg. cycles)							

1: no restrictions
2: generally used
3: not recommended
4: not used

Comp. of IUCD 7"P"

Perforation

غالباً السبب ثقة زائدة في الطبيب

- later on
- وقت insertion : severe persistant pain & bl.

- actinomycosis israeli
- septic technique, long threads

P.I.D.

قتل

missed threads

1. Speculum < short mucous
2. Preg : β-subunit
3. search for it
   - abd. (x-ray)
   - uterus (hysteroscope)

لولب

- intra (حسب القتل)
  - accessible : remove 25% ab.
  - not : Leave it 50% ab. (esp. septic)
- extra (ناس بيقولوا العكس)
  - infection
  - ↓ tube motility (if + Pr.)
  - ↓ intrauterine but not extraut. preg.

Expulsion

- الوقت .... inserted postpartum
- اللولب .... صغير / كبير
- الرحم .... مشوه
- السن .... young / NP

Bleeding

- Post-insertion → reassure
- مع الدورة → menorrhagia (exclude path.)

Pain

- ... exclude perf.
- .... sp. dysm. accepted (otherwise...?)

Alerting symptoms

- missed
  - period
  - threads
- severe
  - pain
  - bleeding
  - discharge

IUCD + pain : كل

- PID
- Preg < thr. ab. / dist. ectopic
- perforation

Insertion

- Push out ..... perforation
- Withdrawal .... آمن ✓

} threads are cut 3 cm

Post-coital contr.

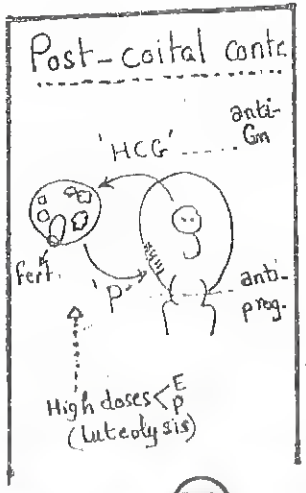

C.O.C.

Non-contraceptive benefits

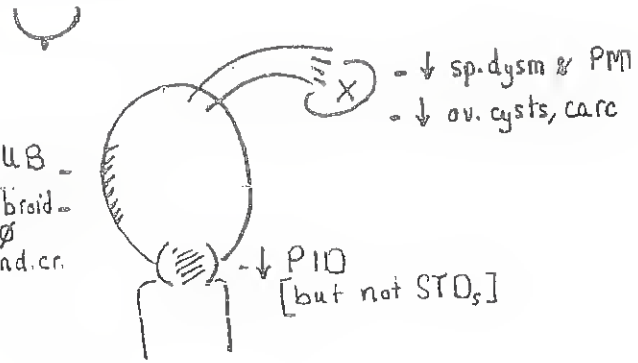

C.O.C. & tumors

↓ 3
- fibroid, end. cr, EØ
- ovarian cancer
- Benign br. lesions

3 ↑ (slight)
- cr. cx
- hepatocellular adenoma
- malig. br. lesions

Types of COC

= E P

50. high dose : oral 30. low dose : microoral 20	Px2	10 6 5
0 0 0 0 0 0 0 0 0 0	0 0 0 0 0 0 0 0	● ● ● ● 0 0 0 ● ● ● ●
mono-phasic	Bi-phasic = binovum	Tri-phasic = trinovum ✓

Missed pills

- نسيتي قرص .... خدي قرص .... وبعد كده قرص في ميعادك عادي (أول ما تفتكري)
- نسيتي قرصين .... خدي قرصين .... والمرة الجاية قطع خدي قرصين وبعد كده عادي + 14d back-up

1 Def.

Benign or Malig.

- → Invasion of B. memb.
- → Atypia : cellular / cytological



- Cx : CIN
- Vag : VAIN
- Vulva : VIN

2 %

1. endomet → ↑ed d.t. → estrogen (post-menop)
2. ovary → age, ov. trauma (any age but > 70)
3. Cx → ↓ed d.t. → HPV (35-55) < sex, smoking

Screen, Condom, vaccine

Sq. col. junc.

- Age ....
- Parity .... low → high : Cx

3 Etiology

Chronic irritation by ...

4 Path.

- Mac ... starts ... local → 1 2 3 → then diffuse / bilat.
- Mic → epith ... col → Adenocarcinoma ..... Sq → Sq cell cr.

5 Spread

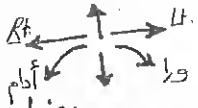

- endomet → direct
- cervix → lymphatics ..... systemic dis
- ovary → seedling (implantation) .... early 2ries
- sarcoma → blood

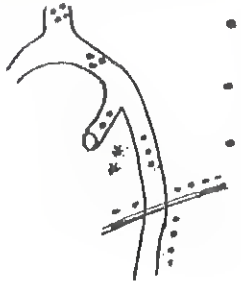

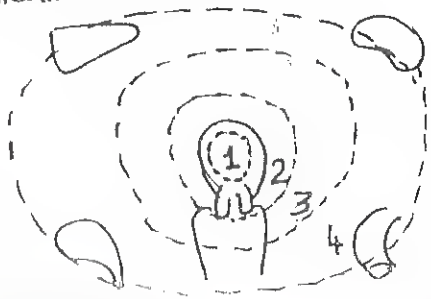

6 Staging

for < lines of therapy / Prognosis

may be
1) surgical : فوق
2) clinical : تحت

1 ... local
2
3
4 ... a : BL/R. ; b : distal spread

7 C/P

Sympt.

1. Bleeding < post : end cr, peri : fibroid, contact : cx
2. Swelling ↑ ↓
3. disch. .... leuck. .... purulent
4. Pain (rare & late)

Signs

- G. :- cachexia, anemia, metastasis
- A :- swelling, ascites
- L : < PV, Bimanual, PR ... rectum

* Cause of death

8 Inv.

	end.	cx.	ovary
Screening	TVUS	Pap	tum. marker
Diagnostic	D & C	.Leep .cone	Laparotomy & path.

Preop → HB%, chest x-ray, ECG, RBS

Spread → radiology ... endoscopy

9 D.D.

of < Bleeding, Swelling, pain

10 ttt

- → Prophylaxis — etiology
- → therapeutic "acc. to stage"
  - endomet → surgery
  - cx → radioth.
  - ovary → chemoth.
  - palliative : في الآخر
- → Prognosis "5YSR" — endomet ..... ovary

Path

SSSS
NM
CCC

No → solitary or multiple

Site
1. Corporeal 95%
   - interstitial
   - subserous
   - sub mucous } pedunculated polyps
2. Cervical 4%
3. extrauterine 1%

Supply
1. Capsule
   - Center ..... less vasc.
   - periphery ... more vasc.
2. Pedicle
   - tip

Shape → spherical

Size → mic. up to v. huge

Cut section → whorly

Caps. → pseudo. = compressed tissues

Consist. → firm
- * hard .... Ca^{++}
- * soft → deg. / malig. (v. soft) / preg.

Mic. → smooth ms + fibrous tissue

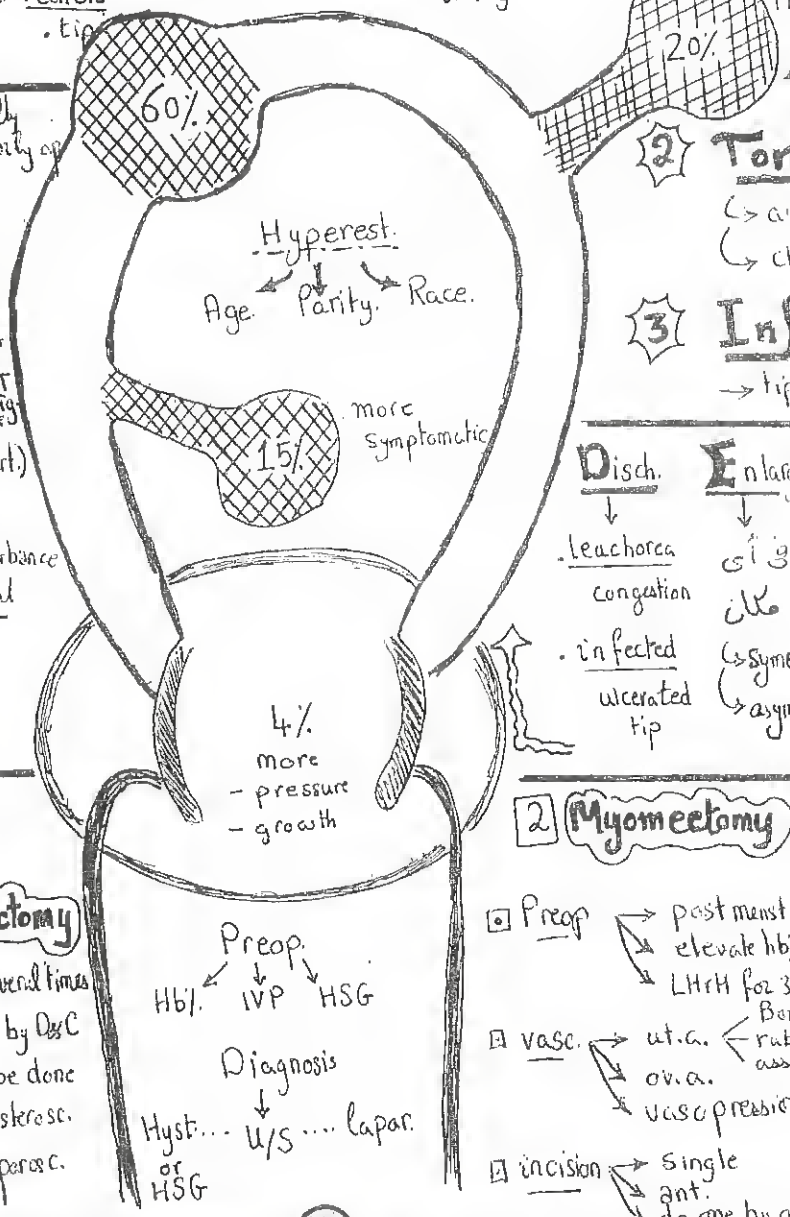

Comp

1 Degeneration. ← near menop. usually / all will loose whorly appearance

- Fatty change
- Ca^{++} = womb stone
- ✓ Hyaline (mgx.)
- Pseudo-cystic

- Red deg. في الحمل
  - → hyperceg. ← pain, vomit., fever
  - → conserve .... never surgery
- Atrophy بعد الحمل
  - → menop. except ← Ca^{++}, HRT, malig.

2 Torsion
- → acute: gangrene
- → chronic: parasitic f.

3 Infl.
- → tip of sub ← mucous / serous

4 Malig. ✗ 0.5%
- Growth ← rapid, post-menop
- Tumor ... painful, fixed
- Biopsy ← mic. / ← no MI / MM

C/P

ABCDE
3P

A acc. discov.

B Leeding
- * menorrhagia
  - ↑ed vasc. size
  - end. hyperp
- * metrorrhagia
  - ulcerated polyp.
  - cancer end.
- * Polymenorrhea

C Comp. (infert.)
- * functional — H. disturbance
- * Anatomical
  - tubes
  - uterus
  - cx

D Disch.
- Leuchorea — congestion
- infected — ulcerated tip

E Enlarg. → ج ي ج مكان
- → Symet.
- → asymet.

P r. → cx.

P ain → sp. dysm. / أكتر مع sub mucous
- Acute ← Red d. / torsion / infl.

P reg.
- * Preg. ← early: ab., ectopic / late: malpresent, PPH, pr. & pain
- * Part. ← 1st ... prolonged / 2nd, 3rd ... abstracted / retained
- * Peurp S_3

Ttt

acc. to
- Age
- bleeding
- size

No
- if acc. discovered [In] Young or Menop.
- [X] no Sympt

Mild ← bl. / small size
- iron
- est أعراض → Preg. dazcol/dimet / III Rh

Severe

1 Polypectomy
- twist several times
- followed by D&C
- could be done by ← hysterosc. / laparosc.

Preop. → Hb% / IVP / HSG

Diagnosis → Hyst. or HSG ... U/S .... lapar.

2 Myomectomy ← infert. / severe bleed. / large > 12 wks

- Preop → post menst / elevate Hb% / LHRH for 3m.
- vasc. → ut.a. / ov.a. / vasopression ← Bonney clamp / rubber catheter / assistant hand.
- incision → single / ant. / do one by one

3 Hysterectomy
- old ← age / completed family
- fibroid ← cx. / br. lig.
- malig. ← end. cr. / leiomyosarc
- myomectomy ← bleeding / reccurrent / multiple

Etiology

unopposed Hyper-estrogen.

Epidemiology

- Age
- Race
- Class

Etiology

- Menst. ccc
- Endogenous
- Exogenous

Association

"CCS"

- Obesity
- D.M.
- HTN

C/P

short period amen. → bleeding

Peri-menop. bl.

Post-menop. bl.

1. Bleeding
   إيه القاعدة:
   مين الـ Common:
   إمتى في سن صغيرة:
2. Pain
   إيه القاعدة:
   إمتى بيبقى فيه وجع:
3. Discharge
4. Swelling
   إمتى الرحم يكبر

Path.

large ↑ die ↑ إمتى

Prolif. endom.	
Cystic gl. hyper.	1%
± atypia	10%
Adenomat. hyper	3%
± atypia	30%
Adenocarcinoma	a
Adeno-acanthoma	b
Adeno-sq-cr	c
Pure sq. cr.	
Carcinosarcoma	

I

II

III

Spread

III A

- Simple
- Complex
- Atypical

III C

L.N.

إمتى تدي الـ inguinal?!

Direct

Blood

إيه أخبار الـ prognosis ☺

Inv

B

1. Screening
   TV-US
   4-5 mm
2. Diagnostic = Fractional D&C
   - إيه المتاح في العيادة
   - إيه أدق حاجة
3. Preop.
   - HB%
   - ECG, سكر
4. Staging.
   - radiology
   - endoscopy

Exam.

G. — السن

A. — إمتى

L. — slightly bulky

PV / PR

Tt

Prophylaxis

- screen by TVUS
- D&C for any PMB

Endomet hyper.

- BL. → Prog.
- inf. → ind. of ov.

D&C & follow up < U/S / D&C

Hysterectomy

Endomet. carcinoma

TAH + BSO

I [Surg.] + III

جراحة

- > ½ myom.
- grade II, III
- L.N. +ve
- Types

II ⊕

if becomes resectable

أشعة

III [Rad.]

- Radium, cesium
- ut. cavity, vag.
- Brachy, tele-therapy

Def.

Funct. end. glands & stroma outside the endomet. cavity

Etiology

↑E: age, parity, race

3. Halban (lymphatic): nose, lung

2. Meyer (metaplasia): g.bladder, appendix

1. Sampson ± immunolog. error

4. +++ implantation

Pathology

- extraut. → EØ
- intraut. → adenomyosis = Cullen diverticul.

extra-Pelvic

Pelvic:
- subtle lesions
- powder burn
- petichae
- plaques
- Large nodules [endometrioma] = chocolate cyst

• Macrophage → PG, Abs
• adhesions

D. pouch

D. 2ry spasmodic

D. → tube, Perit., ovary

D. → menouria (Yousef 8)

D. → menorrhagia, Polymenorrhea

D. → bl. per rectum

D. → 1. painful P.V.

2. thickened R.V. septum

3. Nodules in D.P.

4. fixed RVF

5. adnexal swelling

- Tender
- Thickened
- fixed
- Nodular

C/P

Triad: Pain, Bl., infert.

acute abd? ectopic? habit.? abortion

Inv.

[3] CA 125 ---- follow up

[2] U/S ---- gross lesions

[1] Laparoscopy ✓ — diagnostic (biopsy) ✓, therapeutic

• EØ size	mic	<1cm	1-3	>3
• adhesions	no	filmy	Partial	complete obliteration of D.P.

Min. I	Mild II	Moderate III	Severe IV

D.D.
1] Frozen pelvis
2] Choc. cyst
3] Symet. & asymet. enlarg. of ut.

ttt

↳ Prophyl.
- progressive
- reccurent

Genital: 1) ovary 2) DP

Extra-genital: 1) rectum, sigmoid 2) bladder, ureter

↳ Active

Est. أعراض

- given min. for 6-9 m.
- weak synthetic androgens

1. Progesterone
- Given by cont. manner 9-12 m → pseudo decidua → atrophy
- efficacy Known by occurence of amenorrhea
- 80 mg/m. 1st choice

2. Danazol: 200-400-800 mg/d.

3. Dimetriose: 1.25-2.5 mg twice weekly

4. LHRH: Zoladex = Decapeptyl S.C. /28 d.
- Cont. manner → pseudo menop.
- Add-back therapy to avoid osteoprosis

-ve

غالبين Side effects
- ↓ SHBG ... ↑ free androgen [1]
- O -ve ---- menop. Symp [2]
- liver dysfunc. [3]

Triad

- Pain --- anti-prostaglandins
- Bleeding < Progest. / COC
- infertility
  - a) if no masses ... induction of ov.
  - b) if there is mass or adhesions ... remove it 1st then induce

زمان كان فيه طفح إسمها Hormone supression قبل وبعد العملية

Masses

- electro-fulgration
- adhesiolysis
- ov. cystectomy

ventro-suspension

LUNA

By Laparoscopy ✓, Laparotomy

up to TAH + BSO in old age

GTN

V. mole [hydatid. mole] — β

Choriocarcinoma — M

Def.

Benign tumor of trophob. ccc by < + Tr. prolif. / hydropic deg.

A rare malig. tumor of troph.

Etiology

unknown. m.b. a 1ry oocyte error
- genetic & mut. (أكثر في جنوب شرق آسيا)
- immunological
- extremes of age

→ gestational → V.M. 50% ✓ / delivery 25% / ab., ectop. 25%

→ non-gest. (ovarian)

Types

1. Benign (ممكن يبقى)
2. Invasive (choriadenoma destreuns)
3. metastasing

Complete	incomplete
- 46xx	69 xxy
- common	rare
- malig. 5-10%	rare
- vesicles	+ fetus & placenta

Metastatic	Non-metast.
- lung (80%) = cannon ball	- locally invasive
- larger than 1ry	- Placental site troph. tumor
- regress after removing 1ry	

C/P

History --- of amen. ⊕ preg. sympt.

G — anemia ⊕ Comp < PIH, HG, thyrtox., DIC

A — • Swelling — uterus↑, ovary↑
• Pain — dull aching, cramp, sharp (إيش؟ acute)

L — irreg. bl ± vesicles

History of ..... recent TOP < V.M. / F.T.

G — anemia ⊕ cachexia ✓✓ lung, liver, brain — metastasis

A — • Swelling — ↑uterus, ↑ovary, perf. of ut., comp. cyst

L — • Pain — irreg. bl. after recent TOP. (قاطعة!!)

Risk factors

- β-HCG > 100.000
- duration > 6 ms

A (no) B (1) C (2)

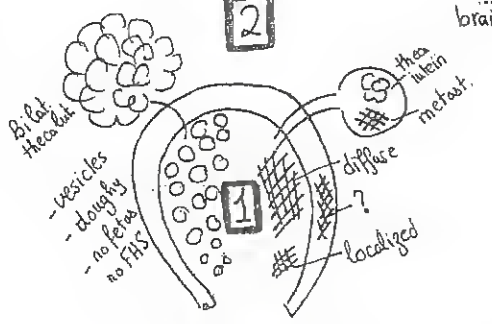

Inv.

- follow-up (progn.) diag. ---- β-HCG ---- >100.000 mIU/ml
- snow storm / (x-ray) honey-comb. ---- U/S ---- Doppler (intra-mural); x-ray, CT, MRI (metastasis)
- after evac. ---- Histopath. ---- D&C must be done for...
  - ↓ - troph. prolif. ⊕ hydr. deg. - avascular pattern of villi
  - ↓ - sheets of malig. troph. cells - Hgic ⊕ avillous pattern

Ttt

▣ Resuscitation ⊕ Surgery
- صغيرة: suction evac.
- كبيرة: hyst. in toto

- followed by < ecbolics / curretage
- No hysterotomy
- Risk of choric. 35%
- ovaries are not removed except...

▣ Methotrexate / Actinomycin D
= Single agent for ! low risk group
= 97% 5YSR (good prognosis)

OR MAC / EMA-CO
= Combined agent for ! high risk group
= 70% 5YSR (poor prognosis)

▣ Surgery — hysterect. < Chemoth. intolerance, Comp. e.g. severe bl., Completed her family; localized excision

▣ Follow up
- β-HCG titre
- irreg. ut. bl.
- evid. of metast.

rising / plateau / +ve after -ve

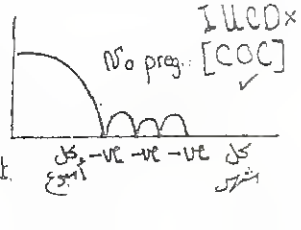

Etiology

- S.I. — 18 yrs — multiple — non-circum.
- Virus — HPV ✓ — HSV — HIV
- Smoking

Inv.

1. Pap smear
   - Ayre's wooden spatula
   - Techn.
   - timing — 1 yr → high risk — 3 yrs ! others
2. Colposcope
   - epithelium
   - vascularity
   - acetic acid
   - Schiller I_2
3. Biopsy
   - Punch — colposcopic
   - × Cone — ✓ LEETZ — السيل

Ttt

Ttt of inf. ← LG.SIL { HPV + I — 18 yr → Regress

HG.SIL { + II — stationary; + III — 30 yr → Progress — 40 yr

- Conserv.
  - Conization
  - Cauterization
  - LLETZ
- Hyst.

[+] Follow up → Pap, → colposcope — strictly — سى الحياة

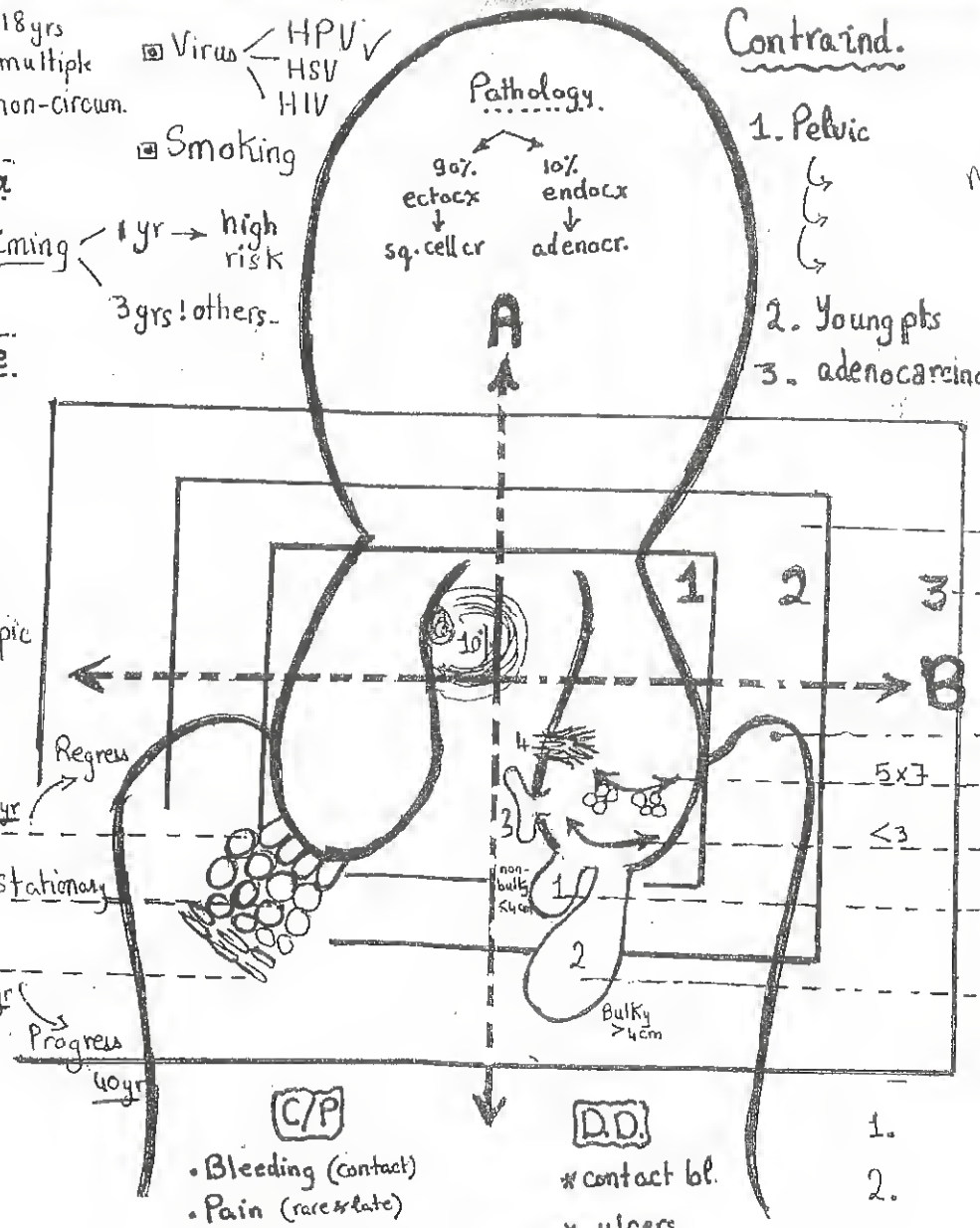

Contraind.

1. Pelvic
2. Young pts
3. adenocarcinoma

Adv.

less — M. & M.

Disadv.

- * Early → DNA dest.
- * Late → E.A.O

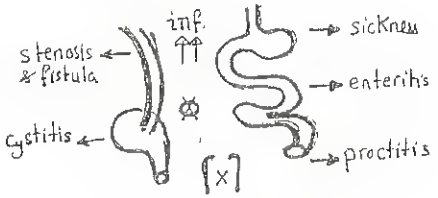

Radiotherapy

- II b
- III
- II a (Werthieme)
- Ia₂ (extended) — 5×7
- Ia₁ (simple) — ≤3
- Ib₁
- Ib₂

C/P

- Bleeding (contact)
- Pain (rare & late)
- Discharge (serosang.)
- Swelling
  1] nodule
  2] cauliflower
  3] malig. ulcer
  4] infiltrating

D.D.

- * contact bl.
- * ulcers
- * Polyps
- * Barrel shaped cx

Adv.

1.
2.
3.

Disadv.

- * Early — hge — inf. — injury : ureter
- * late
  - lymphocyst
  - wound dehiscence

"Ovarian tumors"

Non-neop

Functional ✓

follicular — C.L. cyst

- Anovulation
- < 6cm
- follow up ± COC

- of preg. ✓
- Halban dis. شبه ectopic

3. PCO
   - C/P of SOHA
   - U/S of Adam's
   - Inv. esp. LH/FSH ↑ Andr
- EØ
   - Pain ... 6ds
   - infertility
   - Bleeding ... cyclic
- PID
   - fever
   - pain
   - disch.
   - ⊕ fixed RVF
   - ⊕ tender adnexal swelling

3. • Paraovarian cyst
   - Wolfian remnant
   - pr. effect → excision
   - Theca lutein cyst
   - UM, Rh, OM, torn
   - charic., OHSS
   - Pregnancy lutoma حامل + دق
   - ↑ androgens
   - virilization of mother + ♀ fetus

Primary

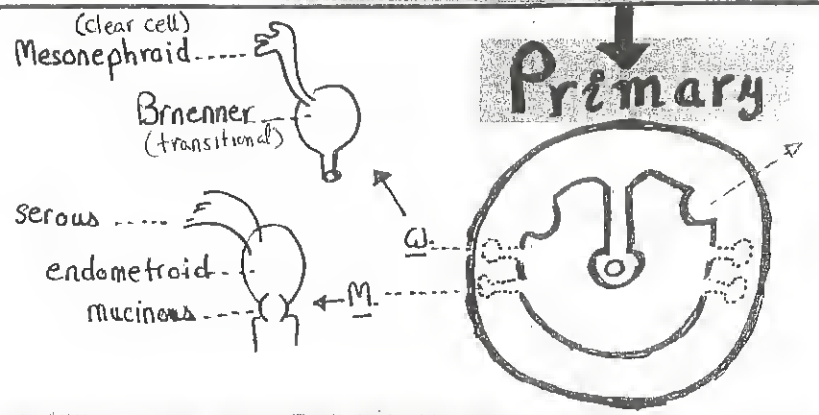

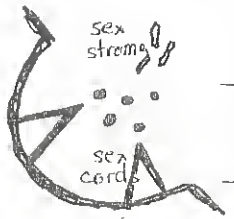

theca	Leydig
granulosa	sertoli
♀	♂

Common epith. 70-80% ✓

(Mullerian)

1. Serous
   - * small, unilac.
   - * psamoma bodies
2. Mucinous
   - * large, multilac.
   - * rupture → pseudomyx. perit.
3. Endometriod
   - * chocolate cyst
   - * post. in D.p.

- may be 20% B.. BLM ... M
- ! more malig.
- ! more :-
   - Mac.
     - Solid ± hge
     - bilat. 10%
     - papillae
   - Mic.
     - Stratificat.
     - Atypia <
     - invasion to stroma

(Wolffian)

4. Brenner ..... secretes "E" (coffee bean)
5. Mesonephroid ..... clear cell

Hobnail

Sex-Cord 10%

1. (Gran. theca)
   - ⊛ Gr., Gr. theca
   - ⊛ Pure thecoma
   - ⊛ Fibroma → Meig

   ↑E → pre-pub / child bearing / post-menop

   Pseudo-Meig $
   - Brenner / thecoma
   - multiple SSerous fibroid
   - OHSS

2. (Sertoli Leydig)
   ↑ "An." < defim. / musc.
3. (Gynandroblast) < 1/2 +

unilat, small, solid
Yellowish
Varying malig. potential
(Pure thecoma) (Fibroma)

Germ-cell 5-10%

1. (Undiff) (dysg)
   - ! commonest malig germ cell tumor
   - esp. in dysgen. gonads
   - secretes HCG → P.pub
2. (Poorly)
   - embryoma
   - Poly emb.
   - emb. cr.
3. (Well)

extra embry. — Embry.

Solid — immature
cystic — mature
monodermal
- struma ov. ... $T_{3,4}$
- carcinoid ... 5HT

choriocr. 'HCG' — EST — FP

Secondary

5-20% of malig. tumors

- ! ovary is a common site for metastasis
- they reach ! ovary by blood or lymph. spread

extra genital — genital — ✓75%

typical
✓ atypical
(Krukenberg)

Bilat ... solid ... tubular
mobile ... signet ring

(N.B.)

Any tumor with these ccc ... search 1st for the Primary : mostly Stomach — upper GT endoscopy
Ba-meal

A

* **Aging** 40 → 15, 60 → 35, 80 → 55 / 100.000
  - → familial (5%) esp. if 1st deg.
  - → Genetic < BRCA, Lynch II
* **Incessant ovulation** محمود فتح الله
  - ∴ ⇧ by..... ⇩ by.....
* **Exposure to:** asbestos, talk

C

acute abdomen ← [ALL] → laparotomy

T
- acute: gangrene
- chronic: parasitic

} adnexectomy but don't untwist ! pedicle

H → acute abd + shock + rapid ↑ size

R
- Papillary
- mucinous
- dermoid

- infected
- hgic
- malig.

I
- infection: antibiotics + deroofing
- incarceration: impaction in ! pelvis → pr.

M alig. ?! سؤال

P ressure manif.

R eproductive:- dermoid أشهر حاجة مع الحمل

- → 1st..... may be C.I. of preg. (esp. if < 6cm)
- → 2nd..... ✓ laparotomy (esp. if > 6-8 cm)
- → 3rd..... technical difficulty
- → labor.... VD if no obst: laparotomy within a week

General

* H. effect
* PL effusion (Meig's)
* Cachexia

Abd

* enlarged liver or Kid.
* Ascites, omental cake
* Sister M. Joseph

Local

* Mass
  - Pelvi-abd
  - adnexal
  - D. pouch.....
  - U.V pouch.....
* Nodules

↳ D.D.:-

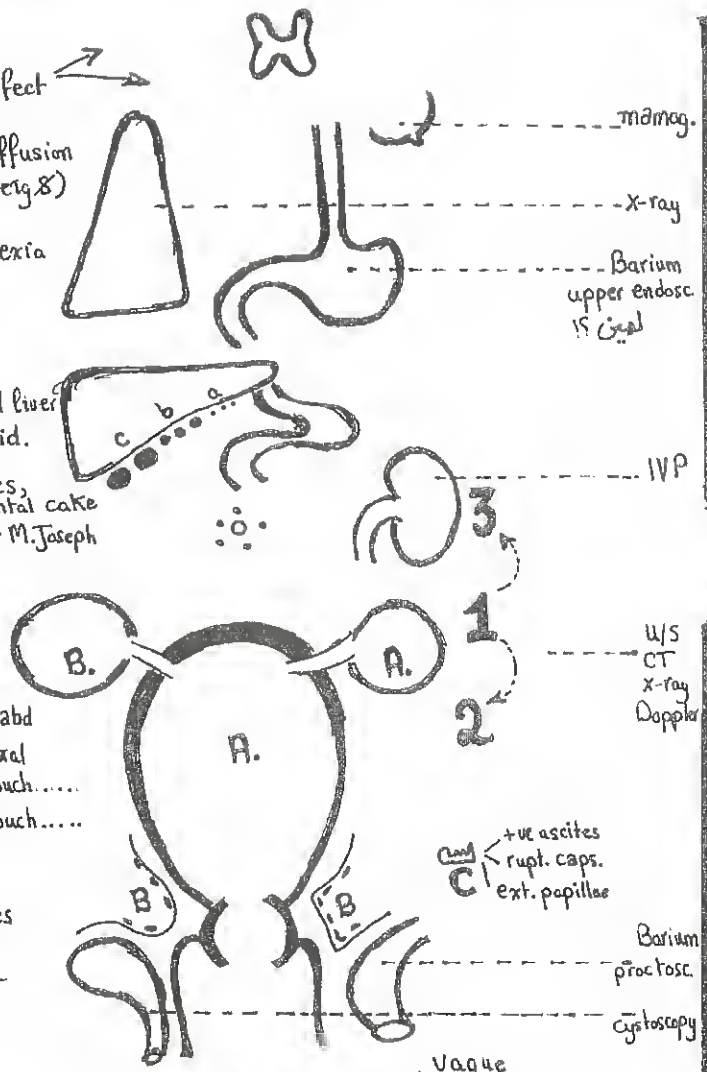

Symptoms

- Vague
- presented late

(1) **Swelling** ↓ Presented as 3d
- Distension
- Dyspesia
- Discomfort

(2) **Bleeding**
- → p. cong.
- → 2ries to ut.
- → functioning

OR → **Amenorrhea**
- → cachexia
- → bilat. destructive
- → hormonal

(3) **Pain** if comp.

(4) **Disch.** سائل

B

α-lab < CBC, Hb%, ESR; Tumour markers سؤال
- 1] Antigens — CA_{125} ..... epith.
- 2] Enzymes — الكبد ..... dysgerminoma
- 3] Hormones —
  - β-HCG, αFP ..... germ
  - estrogen, andr..... funct.
  - $T_{3,4}$, 5HT ..... monodermal

α-scan

α-scope: laparoscopy < staging, 2nd look ×

α-biopsy
- aspiration from ! cyst ×
- ! definitive biopsy is by ?!

D

- **Age** .... extremes < v. young, v. old
- **General** ..... cachexia
- **Abd** ..... Ascites, omental cake, enlarged liver, paraort LN
- **Local** ..... Bilat., fixed, tender, Rapid growth, Nodules in D. pouch
- **Inv.** ..... ↑ ESR > 100
  - +ve < markers, cytology
  - Doppler → high velocity ✓
- **Intra-op....**
  - as abd. & local ⊕ < papillae on outer surface; areas of hge & necrosis; large Vs on ! surface

Non-neop

Functional

follicular
- Anovulation
- < 6cm
- follow up ± COC

C. L. cyst
- of preg. ✓
- Halban dis. شبه الـ ectopic

[3] < PCO, E∅, TOA

[3] • Paraovarian cyst
- Wolfian remnant
- pr. effect → excision

• Theca lutein cyst
- VM, Rh, OM, twin
- choric., OHSS

• Pregnancy luteoma حامل دقن

Primary

Common epith. (70-80%)

Mullerian
- may be B.. BLM...M
- ! more malig. ! more :-

1. Serous
   - * small, unilac.
   - * psamoma bodies
2. Mucinous
   - * large, multilac.
   - * rupture → pseudomyx. perit.
3. Endometriod
   - * chocolate cyst
   - * post. in D.P.

Hist.
- Solid ± hge
- bilat.
- papillae

Mic.
- Stratificat.
- Atypia <
- invasion to stroma

Wolfian

4. Brenner ..... secretes "E"
5. Mesonephroid ..... clear cell

Germ cell (5-10%)

1. Undiff (dysg)
   - ! commonest malig germ cell tumor
   - esp. in dysgen. gonads
   - secretes HCG → P. pub.
2. Poorly
   - embryoma
   - Poly emb.
   - emb. cr.
3. Well

extra-embry.
- * choriocr HCG
- * EST ∝FP

Embry.
- Solid: immature, mature
- cystic: mature, monodermal
- • struma ov.... $T_{3,4}$
- • carcinoid ... 5HT

Sex-Cord (10%)

1. Gran. theca
   - Gr., Gr. theca, Pure thecoma } ↑ "E"
   - Fibroma → Meig = pl. eff & ascites
   - Pseudo-Meig < Brenner, thecoma, multiple S.S. fibr., OHSS
2. Sertoli Leydig
   - ↑ "An." < defim., musc.
3. Gynandroblast < ½ +
   - unilat, small, solid
   - yellowish
   - varying malig. potential
   - pure thecoma, fibroma: بطء

Secondary

"5-20% of malig. tumors"
- ! ovary is a common site for metastasis
- they reach ! ovary by blood or lymph. spread



typical
✓ atypical (Krukenberg)



Bilat... solid... lobular
mobile... signet ring

Proph.

1. Periodic exam.
2. Tumor markers
3. ✓✓ TVUS + Doppler

Removal in <
- > 6cm, persistent
- Hyst. if ≥ 45yrs
- High risk (familial)?!

B

1. Old >45 → TAH & BSO
2. Young
   - Cystectomy
     - uncomplicated
     - well demarcated
   - Ovariectomy
     - comp.
     - destroying ! ovary

M

Expl. laparotomy
1. mid line incision
2. perit. cytology
3. inspect & palpate ± biopsy
4. don't allow cyst to rupture

I ..... TAH + BSO + LN + Appendicectomy + infra-colic omentect.

II, III, IV
- max. debulking
- optimum cytored.

⊕ Chemotherapy
- epith..... CAP
  - carbopl. is less toxic > cisp.
  - Adriamycin m.b. removed
  - 2nd line → taxol
- germ ..... BEP

Age.

- childhood..... germ cell
- CBP < functional cysts, Dermoid
- Post menop..... epith.

S

- Benign..... Brenner, thecoma, fibroma
- Malig..... epith., dysgerm., Kruken.
- Functioning.... G-T, S-L

F

1. Sex cord stroma ..... feminizing or virilizing
2. Germ cell

	β-HCG	∝FP
• embry.	+	+
• choric, dysg.	+	−
• EST	−	+

3. Epith. ↳ Brenner

struma ovarii → $T_{3,4}$
carcinoid → 5HT

Vulval dystrophy —5%→ VIN —50%→ Invasive (4%)

VIN: 20-30 yrs; Invasive: 60-70 yrs

Etiology

- **C**hronic irritation
- **A**utoimmune/met. dis. e.g. DM, achlorohydria
- **L**ocal factors: chalones (↑ atrophy)
- **N**utritional def. e.g. Fe, folic, B-complex
- **E**nviromental & familial

Control ← **Skin** → irritation

D.D.: psoraisis ⇄ Lichen planus

1. Biological: candida, condyloma, LGV
2. Mechanical: pruritis vulvae (scratch)
3. Chemical: glucosuria in DM

Path

	Sq. cell hyperplasia (Leukoplakia)	Atrophic (Lichen sclerosus)
Mac.	Well defined, Raised	thin, dry, smooth, white ✓ رقيقة زي ورقة السلوفان
Mic.	• hyper-Keratosis • acanthosis • papillomatosis	• hyper-Keratosis • thin epith • flat pap.
± Atypia	*	* chr. infl. reaction
		مكرمشة Krausosis vulvae

Squamous → VIN I, II, III

- Postmenop (HPV-ve) .... unifocal
- Premenop. (HPV+ve) .... multifocal

Non-Squamous

- Paget (adenocr. in situ) → 1-2% adenocr. of apocrine sweat gland — sharply demarcated, eczematoid } cake icing
- Melanoma (5%)

Mainly lymphatics

1. L. majora
2. Clitoris
3. L. minora

} Sq. cell cr. Well different. ✓

infiltrating, malig. ulcer, Cauliflower

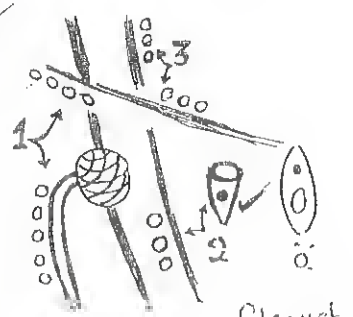

Cloquet ✓

Sympt. / Signs

- Asymptomatic ..... P-P-d-d ..... [+] Bleeding
- Change in color (white/pigmented) ..... change in contour (flat, raised) ..... [+] Mac. path. ← mass, ulcer, L.N.

Inv.

1. Etiology ← Swab, GTT
2. Diagnosis → colposcopy, acetic acid, toludine blue
3. Comp.... biopsy (definitive) ✓

Ttt

1. أول حاجة ..... symptomatic ± ! pdf.

local	local
- hydrocortisone 1%	testosterone 2%
- clobetasol 0.05%	

2. أوعى تنسى ..... follow up

Localized

* Wide local excision (with safety margin 5mm)
* local dest. ← 5% 5 FU, Laser, Cryo cautery

2/3 multifocal

25% recurence > خد بالك !!

Multifocal

Simple vulvectomy (skin only)

1. أول حاجة ..... prophylaxis → any.... biopsy

Surgery (radical)

- Butterfly
- triradiate

± S.C. fat
± ing. L.N.

Radiation

- adjuvant (postop.) ✓ → LN > 4 or Cloquet; tumor > 4 or Clitoris
- curative (min. role)

2. أوعى تنسى → prognosis: أسوأ Clitoris ?! (very vascular)

Staging of vulval tum.

	Tumor		Node	Met
I	T_1	< 2 cm	N_0	M_0
II	T_2	> 2 cm	N_0	M_0
III	T_3	٣ فتحات	N_1 (unilateral)	M_0
IV	T_4	اللى فوقهم	N_2 (bilateral)	M_1

Vaginal carcinoma

- *Secondary*.....more common ✓✓✓ .....esp ant. wall suburethral
- *Primary*..... upper ⅓ of post vag wall .....squamous cell carcinoma✓
  - ↘ Other rare
    - Adenocarcinoma → on top of Gartner duct (Wolfian remnant)
    - Clear cell adenocarcinoma → on top of vaginal adenosis (DES)

- Spread ➠ Lymphatic → upper ⅔ (like cervix).....lower ⅓ (like vulva)
- Treatment
  - ↘ Radiotherapy ✓✓ radium or cesium ± external pelvic irradiation
  - ↘ Surgery
    - *Upper* ⅔ → Radical hysterectomy + removal of upper part of vagina
    - *Lower* ⅓ → Radical vulvectomy + removal of lower part of vagina

D.D. of vulva

	ulcers	Swellings
Cong.		• Dermoid
tr.	!? episiot. ---> ulcerated	• Hematoma
infl.	T.B, B, Syph. + Herpes	• Barth. abcess
Neop.	- Sq. cell cr. - Basal cell cr. (rodent ulcer)	• Benign/malig.
Misc	• Aphthous ulcer • Behcet ✗	• other swellings apearing at ! vulva

- inguinal region [1.]
  - Hernia
  - Hydrocele of canal of Nuck
  - testis (T.T.S.)
- genital tract [3.] = prolapse
- [2.] Urethra – prolapse
  - caruncle
  - diverticulum
  - para-urethral (Skene's cyst)

Radical vulvectomy

* Complications: ✓mortality: 1-3 %
  - . Artery → hge & shock
  - . Vein → DVT & p.embolism
  - . Lymph → lymphedema of LL
  - - Nerve → parathesia of thigh
  - - Skin → infection & necrosis
  - - Bone → osteitis pubis
  - . Vulva → disfigurement
  - . Vagina → dyspareunia
  - . Urinary → UTI

Pruritis vulvae

General disease

- Liver .....cirrhosis, jaundice
- Kidney.....chronic renal failure
- Endocrine.....DM, ↑ or ↓ thyroid
- Blood.....lymphoma & leukemia
- Autoimmune.....achlorohydria
- Menopause.....senile pruritis
- Psychological.....scratch habit

Skin disease

- Eczema & urticaria
- Parasitic infestations
- Vitamin def

Local (90%)

- Vulvo-Vaginitis →
- Vulval dystrophy /neoplasia

Etiology

5-10%

Down-ward vertical dis-placement

1) Pdf.
- Cong.: RUF ..... AVF
- Acquired: weak ..... lig. ..... ms ..... est. ..... menop
  - nerve
  - bone

2) PPf.
- ↑ abd. pr
- ↑ size of uterus
- ↑ traction on ut.

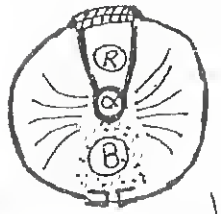

Types

1) Uterine (1, 2, 3)
2) Vaginal
   - ant
   - post
   - vault
3) Combined

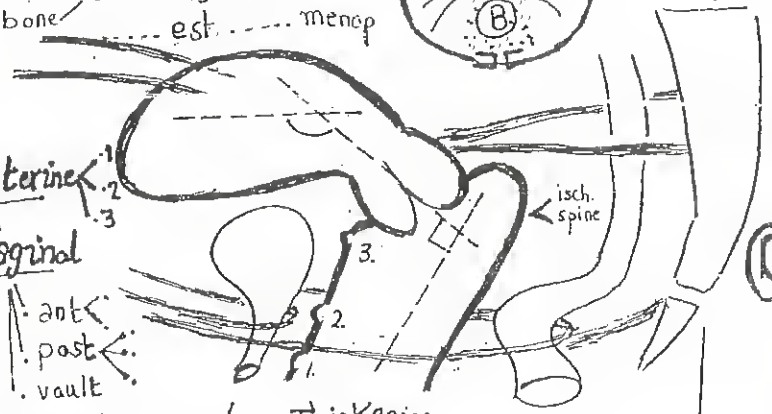

Pathology

= Kink

- Thickening
- Stretch
- infection (Tr. ulcer)

urethra: dysuria
bladder: inc. urination
ureter: hydoureter

vessels ⇓ congestion

rectum ⇓ dyschazia

Sympt.

urinary: ± SUI

Swelling

pain: 4 D

cong. sympt.
- Bleeding
- Discharge

rectal

Exam.

- General
- Abdom.

association / cause / result

Palp.
- Type
- degree
- comp.
- SUI

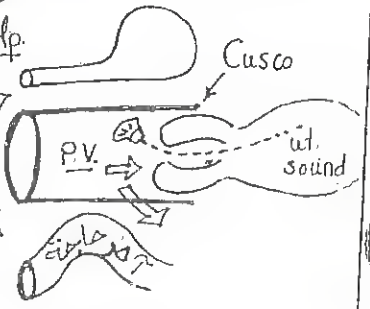

Inv.

- No need
- Routine preop.
- ± urine analysis

O.D.

Preg. ✓
- acute AVF
- R.V.F.
- inversion

..... ولد تنى
- → dextro-
- → Levo-

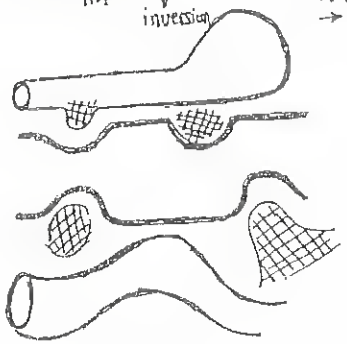

2nd° — Grip test — 3rd°

Supravag. elong. of cx. — cong. elong. — inversion — Prolapse — Polyp

Palliative

indic.
- Contraind. / refusal of surg.
- Congestion (preg., peurp.)
- trophic ulcer

methods
- 1) Pdf. (Smith Hodge)
  - Lig. ... pessary
  - ms ... physioth.
  - est ... ERT
- 2) PPf
  - ↓ weight
  - ↓ smoking
  - ↓ br. asthma

Surgery

1. Preop. care
   - vag. ulcer
   - UTI
   - antiseptics
   - Premarin cream
   - silver nitrate paint

2. Operations

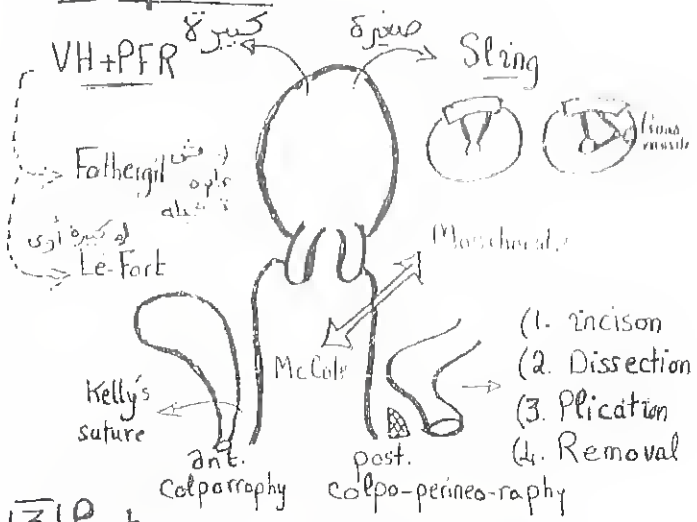

3. Postop. care
   - تحمل امتى؟ تولد ازاى؟

4. Comp. ..... General (hge, inf.) --- special injury

5. Reccurence 5-10%
   - Preop. ..... Bad
   - Operative ..... Bad
   - Postop ..... Missing

1 Prophyl.

proper care

Pdf

Ante-natal { AVF ..... Smith Hodge

Intra-nat { Lig. ..... pessary
Ms ..... physioth.

Post-natal { Est ..... HRT

PPF

Avoid ↑abd. pr.

after hysterect. ولا تنسى

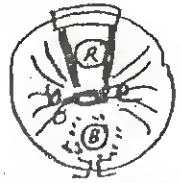

2 Palliative



Avoid ↑abd. pr.

* الحامل حتى
* المرضعة حتى
* المطلقة حتى
* الصغيرة حتى
* الكبيرة حتى

3 Surgical

Preop.
- G → anemia, chest
- L → trophic ulcer, UTI

Oper.
1. incision
2. dissect
3. plicate
4. removal

Postop
- G ... antibiotics
- L
  - vag. pack
  - No I.C 2-3m
  - No preg 2-3yrs
  - VD possible / CS preferable

Fothergill's — أنفضة

Le-Fort — v.v. old

Old — VH + PFR

Young — Abd. sling

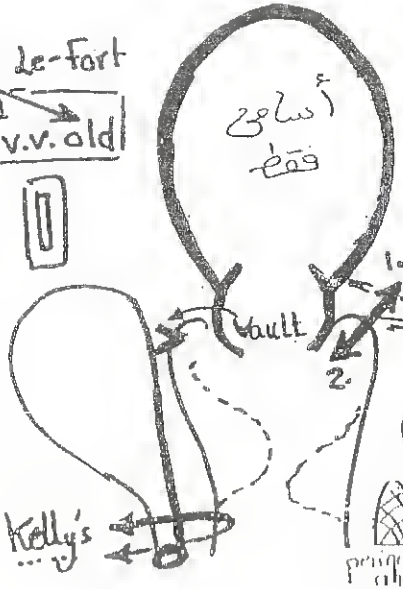

1. Moschcowitz
2. McCall's

Ant. colporrhaphy — Post. colporrhaphy

1. 2. Classical repair

Comp.

- Hge
- Inf.
- Injury

1) Sling → • int. obstruction • left LL pain • possible injury of

2) Fothergill → cx dyst. ← tear ← inf. → infertility; PTL → PIDs

3) Le fort → • difficult < IC / D&C

Reccurence 10% مرة جيدا

	Bad	Bad	Missing
Preop.			
Operat.			
Postop			

Normal

- involuntary loss of urine
- due to acts of ↑ed abd. pr
- when intravesical pr is > intraureth. pr
- In absence of det. cont. ✓✓✓

1. Bladder 0-20 [-ve] — Passive (compliance) / Active [-ve]
2. Post. UVA = 90-100°
3. Urethra 80-100 [+ve]

Etiology

SUI +ve — Bonney −ve → عملية واحدة : Prolapse
SUI −ve — Yousef +ve → عملية ؟ Prolap SUI

1. damage — intrensic sphincteric dam. (genuine SUI)
2. weakness — Anatomical urethral hypermob. — Acq. (− abst, − menop.) / Cong.

F. — backward Rot. descent
- Loss of PUVA
- هتبقى تحت leu dni

"SUI"

Hist → cough stress test → immediate spurt
Exam. → cystocele → +ve stress test → Bonney; −ve → Yousef
Special → Pad, Q tip (30°)

"DI"

idiopathic — inf. irritation: ✓ — Neuropathic

uninhibited detrusor contraction → urgency 'stream' few seconds after provocation eg. cough

Invest.

major social & hygenic problem diag by a → symptom → sign → urodyn.

electrophys. studies

TV.US, cystoscopy — see mov. by

أول حاجة C&S. urine analysis ✓✓

Confirm mov. by: Urodynamics
1. Cystometry ✓
2. Ureth. profilometry
3. Uroflowmetry

1st desire 150-200; Max. capacity 400; VLPP; urethral closing pr.

+ve spurt on cough; +ve

DLPP — stream interruption −ve; residual volume (<50)

+ve stream

DI → orgasm مع
SUI → penetration مع

Tt.

1. Conservative
   - M
   - M
   - M
   - Kegel's exc.
   - Faradic current
2. جراحة
   - vag. — Kelly (نجاح 50%); TVT (شريط — حديثة، غالية)
   - abdom — Bursch; MMK (ممنوعة)
   - combined (= Ureth. Sling) — فتحة، شرائط

ERT

paraurethral implants or art. sphincter

vag. cones

vag. pessary

! Key in sucess is proper resuspension. لو أكتر من كده → retention!

أدوية (stepping)
- anti-depressant
- anti cholinergic (Detrol)
- A.ch
- Ca^{++} blocker
- oxybutinin (muscular relexaïit)

ETIOLOGY

(1) **Congenital** (during division of uro-genital sinus)

(2) **Direct** — **Surgical** (إنجلترا) — **Obst** (مصر)

F F F F

Surgical: vag. / abd. ..... بالذات لو فيه

Obst: direct (في التو) / indirect (بعد أسبوع)

(3) **Inflam.**
- non-specific
- Chr. gran. dis.

(4) **Neop.** e.g. cr. ca

(5) **Irrad.**
- EAO أصعبهم
- Pedicle graft (تدرم)

[A] General

anemia, uremia > Bad g. condition ..... Psychological deprivation up to ....

[B] Abd

tender loin pain ..... Scar of previous op. <

[C] Vag.

Inv.

1 Preop

صحة ... CBC
+ نظافة: urine C&S ? <, IVP ± RFT

2 Diagnosis

→ EUA + methylene blue test (* قطنة في الـ vag; أزرق: vesico; مبلولة: uretro)
→ cystoscopy: شوفها بعينك
→ chromocystoscopy: تشوف الـ ureter

2 Operative

(نساء) محتاجة

* 3-6 month: إمتى

* من فوق (مسالك)
- High (inaccessible)
- Ureteric.
- Reccurent.

▲ Dedoublement (flap splitting) ✓
- Separate bl. & vag.
- Excise ! fistula
- Close both walls separately

▲ Saucerization (Sim's)
- Elliptical incision
- Excise ! fistula (fibrotic) ✓
- Close as a single layer.

▲ Latzko (partial upper colpoclerisis)
- if vault fistula.

3 Postop.

- No I.C. 2-3
- No Preg 2-3
- For healing: catheter (مهمة)
  - ..... left fa
  - ..... care by
  - ..... checked every
  - ..... removed by

C/O
- True incont. (Paradoxical if <)
- UTI (recurrent)

O/E
- see it ?
- feel it ?
- move it ?

أحسن بالي
- Sim's position (نايمة على جنبها الشمال)
- Metal click test (لا يعمل: أي كلام)

* Inflamation ± (P) (تورم)
- Excoriation
- Soreness

∴ apply
- Zinc O_2
- vaseline

* Offensive disch.
* evidence of p. tear

4 Failure

فشل في ..... نسبة عالية <1. 2. 3.

5 Prophylaxis

→ good obst. + surg. care
→ leave a catheter + proper bl. dissection

Diagn. 2
- Ba enema
- Charcoal
- proctoscopy

Preop. 1
- CBC. صحة + نظافة

Operative 2
- Colostomy
- Dedoublement
- small: Vernon David مش مهمة
- large: turn it into .....

Postop. 3
- No IC. 2-3
- No preg 2-3
- For healing

C/O
- incont. of flatus (stools if .....)

O/E
- see it
- feel it
- move it

أحسن بالي
- speculum
- P/R

Failure 4: فشل في ..... نسبة عالية 1. 2. 3.

Prophylaxis 5:
- > good
- proper manag. of perin. tear في الولادة

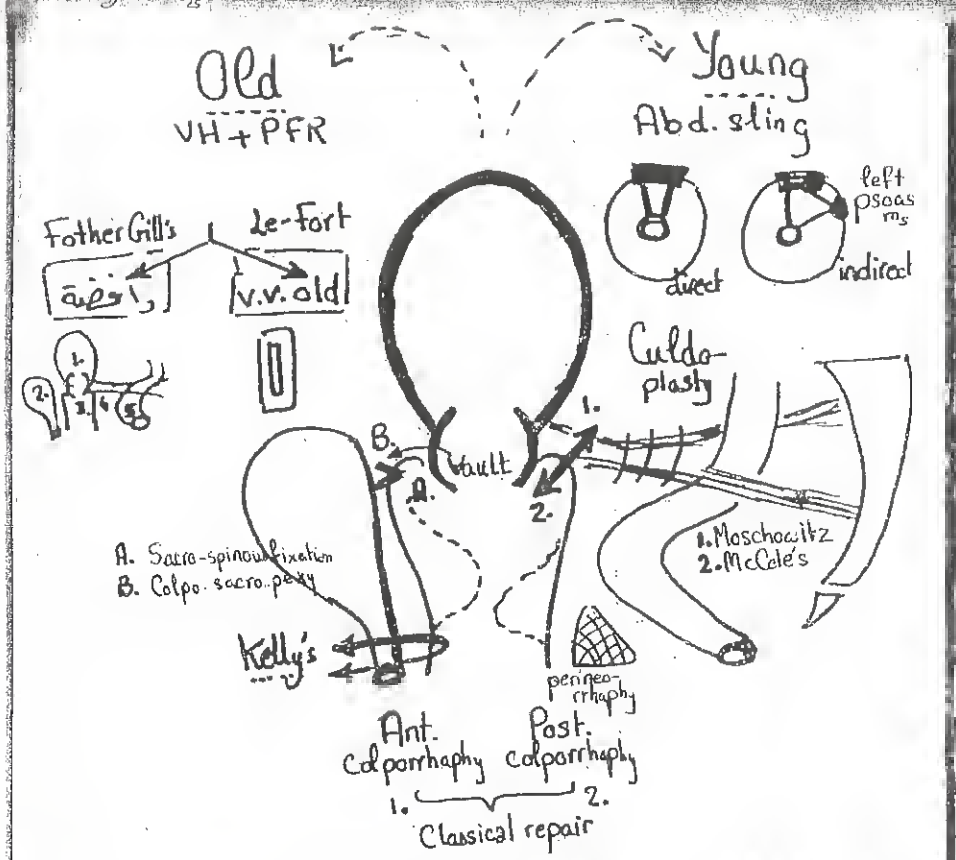

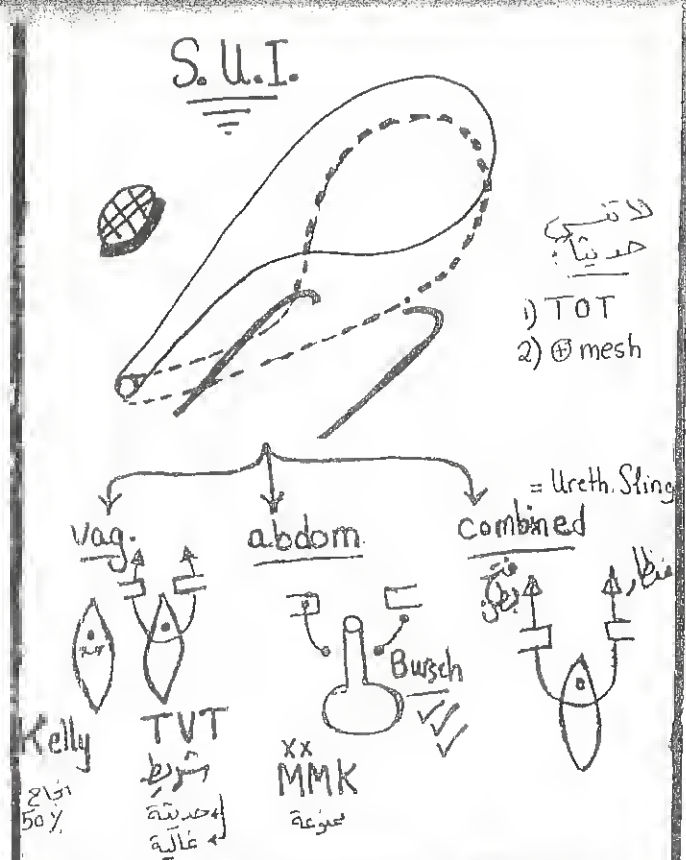

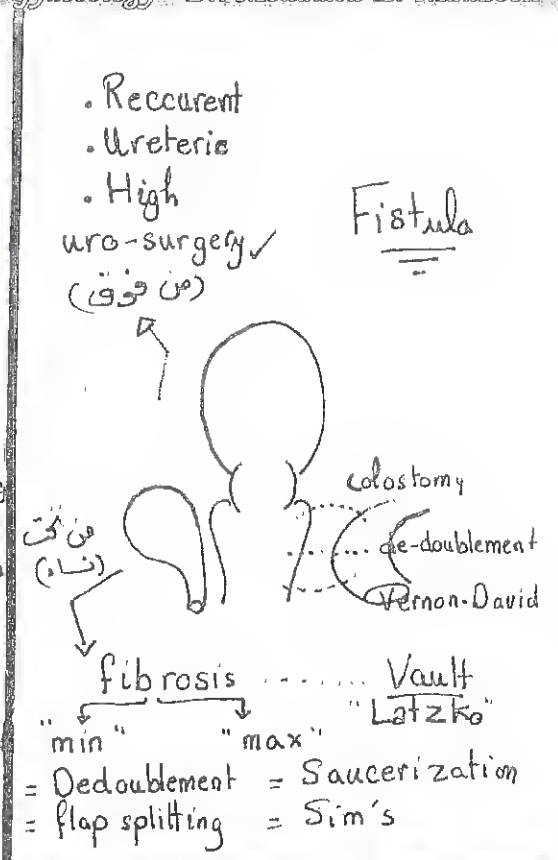

Complications

- Hge
- Inf.
- Injury
  - 1) Sling → • int. obstruction • left LL. pain • possible injury of - ureters - iliac vs
  - 2) Fothergill → tear, inf., infertility, exhaust, PTL, PIO
  - 3) Le Fort → • difficult < IC / D&C

Reccurence ↑ 10%

	Bad	Bad	Missing
• Preop			
• Operative			
• Post-op			

Alternatives (conservative)

for
- Mild
- Much
- Mixed

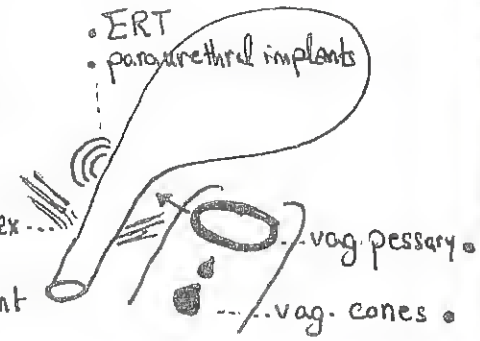

High failure (reccurence)

- Preop < الصحة ... CBC / الإقامة ... inf.
- Operative < proper dissection / proper haemostasis
- Postop < delay IC (3m) preg (3yr) / care of catheter

أهم حاجة prophy. إزاي
1) Avoid injury : anatomy
2) early detection
3) immediate repair
4) leave a catheter

Amenorrhea

	H. P. Ov. Ut	
	1ry	2ry
Cong	Cryptomen.	Pregn.
Tr.	1. Turner	1. PCO
Infl	2. Mullerian	2. hyperpr.
Neop	3. TFS	3. hyperandr.
Misc.		

general < deblitating dis. / drugs / أى عنده ↑↓

Diagnosis

T3,4 — HCG — Pr.
Proge → +ve = Ancv. / −ve
E+P → −ve = Asch. / +ve
LH FSH ↑ CV ↓ Hyp. Pit

علاقات

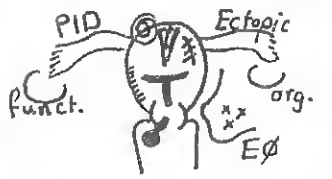

Bleeding
- CBP
- Peri
- Post
- contact

Amen.
- + swelling < Preg. / Crypt
- + D&C →
- + irreg. bl. → Ancv.
  1) PCC
  2) ↑ Pr
  3) ↑ Andr.

Swelling
- + infert < fibroid / EØ / PID
- + fever : PID
- + amen. < uterus : V. mole / adnex : ectopic

IUCD
- → Amen ... pain (ectopic)
- → fever ... disch. (PID)
- → pain

✓PID — قبل missed

BL. — pain

Bleeding

Organic — funct.

G — coag. f. — H↑

ovular — anovular

d
- Cong
- tr
- infl
- neop
- misc ... prolapse

Diagnosis
- lab
- scan
- scope
- biopsy

ttt
- E أعداد
- D&C
- Hyst.

Infertility

etiology	Assesment
cong tr. infl neop Misc	
5	u/s, Progest 21
PID .... EØ	HSG ... laparosc.
fibroid	حاجة
ch. cervicitis	Post coital
impot... premat. ej	Semen
ch. infection (Chlamydia)	20 ... million/ml
	30 ... normal forms
	50% ... forward mot.
1ry الاضاع / 2ry الإدارة	✓A B C D✗

Swelling

	Fibroid	1. EØ	2. PID	3. Ect.	Adnexael swelling
Age	CBP	CBP			
Pdf	⇧E	⇧E			
Sympt.	ABCDE 3P <	triad 1. 2. 3.	triad 1. 2. 3.	triad 1. 2. 3.	
Sign	بطاطس				كله يتفرق
inv	u/s	fixed RVF ↓ infert.	tender cx motion ↓ fever	↓ amen	u/s منظار
comp	Bleeding infertility				
ttt	Acc. to age < young / old				

	Endomet "1"	Cervix "3"	Ovary "2"
1. Age	>60 (related to E_1) < white, low parity	CIN 35-40 ..5-15.. inv. 50 (multipara)	أي سن 20% < 40 ..... 60 > 20% (low parity)
2. Etiology	unopposed hyper "E" ... menst ccc ... endogenous ... exogenous	• SI < 18 yr, multiple part., uncircumcised • STD < HPV, HIV •	* Aging يزيد مع السن * fam. & genetic BRCA ↔ Lynch II * ovulation ↓ by C.O.C.
3. Path (mac. / mic.)	simple 1% ... complex 3% ... atypical x10 → Adenocarcinoma or • localized • diffuse	Sq. cell cr. 1. Nodule 2. Cauli f. mass 3. ulcer 4. infiltrat. — TZ 90% — 10% → adenocarcinoma Nodule ... barrel shaped cervix	Non-neoplastic: Funct. + < 3° Paraov. cyst; 3 < Theca lut., Preg. luteoma. Neoplastic: 1ry < Common epith, germ cell, sex cord; 2ry = Kruker
4. Spread	• mainly direct spread • may be by lymphatics ⇐ ⇑ perforation ⇓ cx ⇒ malig. fist.	• mainly lymphatic: 1st relay ↓ cx, ureteric parametrial; 2nd ↓ iliac; 3rd ↓ Paraortic	mainly seedling = < implantation, transcoelomic
5. C/P (Sympt / G. / A. / L.)	Sympt: Post menop. bleeding (however < atr. end., polypi are commoner)	Contact bleeding	Vague 3d < dyspepsia, discomfort, distension; ± BL – congestion – secondries – estrogen; ± amen. – cachexia – destruction – androgen
	G. — CCS .... Obese + D.M. + HTN	— uremia	— H. effect < thyrotoxic, virilization, Meig's (fibroma)
	A. — only if .... pyometra or associated fibroid	— Pyometra	— Ascites ... omental cake ... sister M. Joseph nod.
	L. — small uterus ± myohyperplasia	— suspicious cx	— Adnexal ... pelvi abd ... U.V. pouch ... D. pouch swell.
6. Inv. (screen. / diagn.)	screen: TVUS .... 4-5 mm; diagn: Biopsy ..... fractional D&C, hysteroscope, Pipel	Pap smear (Ayre's wooden spatula); Colposcopy ... biopsy < punch, colposcopic; Cone, LEEP	difficult < Periodic exam., tumor markers < Antigens, enzymes, hormones; TVUS + Doppler; Exploratory laparotomy → 1. Surg. stag. 2. Biopsy 3. ttt
7. Cause of death	upward perf. & peritonitis	..uremia...	.... int. obstruction....
8. Staging & ttt	Surgical staging: I TAH + BSO; II ⊕; III Tele + brachy	Clinical staging: Ia1 ... simple hyst.; Ia2 ... extended; Ib, IIa .... Radical (Wertheime); Radiotherapy	Surg. < TAH + BSO, omentectomy, L.N.; ⊕ optim. debulking; Chemoth. → epith ... CAP, germ ... BEP; C = < rupture, papillae, +ve ascites
9. Prognosis	! best : early presented : Ia grade I		! worst : late presented : III stage

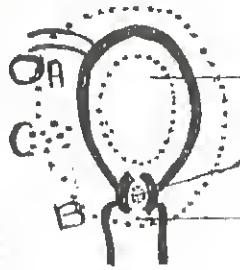

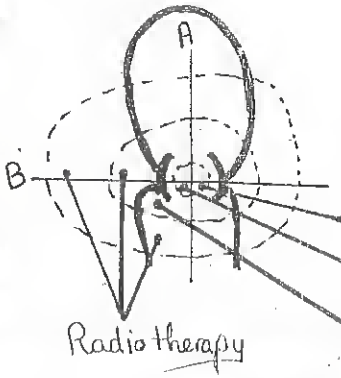

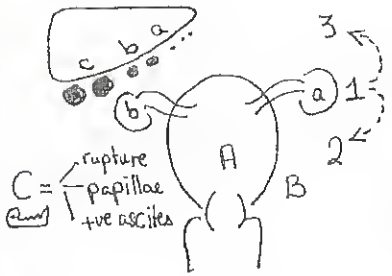

Swellings

Adeno-myosis

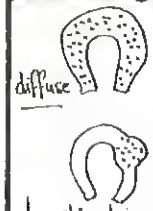

- Cullen's theory
- Deep glands (Horm. insensitive)
- Size < 12 wks
- C/O .... bleeding
- tt. < med. ✗ / surg. ✓

+ Amen.

- Preg / pseudocyesis
- uterus < cryptomen. / Pyometra, hematometra
- tube ... encysted TB perit.
- ovary ... cr. < ... / ...

+ infert.

- uterus .... fibroid, adenomyosis ?!
- tube ... PID, TB
- ovary < neop → Dermoid ?! / non-neop < EØ / PCO

Preg. + Swelling

- esp. Dermoid
- fibroid
- acc. hge, V. mole
- Polyhdramnios
- CPD < malpresent. / non-engaged head

Abd

- Non-symmet. < fibroid, chorio-cr., Adenomyosis
- Symmet. < Preg., Fibroid, Cryptom., Pyometra
- Neop. < Dermoid, Epith. (1-2), dysgerm., Krukenb.
- Non-neop. < Functional, PCO_2, EØ 1-2, PID (TB) 1-2, T-L cysts 2

Pelvic

- ...PID..., ...ectopic...
- ±
- Doug. pouch < RVF, Post. wall fib. / - ectopic, - PID / - P. abcess, - P. hematoma, - encysted TB / EØ, cr. ov., TB / Neop. non-neop. / Others < - ectopic Kid., - tum. of < Perit, sigmoid
- Cx < * fibr. (4% Large), * Cr. cx., * chr. cx
- LGT swellings < * Prolapse, * Polyps, * chr. inversion → Corp., Cx. ; 1) Abd. → ut 2) vag. → cx 3) sound.
- LGT ulcers < STDs ..... herpetic / chr. gr. dis < TB, ß, ∅ / tumors < trophic ulcer in prolapse, ectopy
- Ulcers
- "others" ..... swellings < inguinal → hernia; GT → prolapse, polyps; urethra → caruncle
- hypert. of clitoris — Cong; hematoma — tr. — infected episiotomy; Bartholin — infl. — STDs, chr. gr.; B/M — neop. — cr.; elephantiasis; misc; Behcet ∅

Pyometra

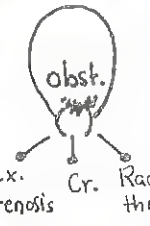

G....
A....
L....
1 Sounding → drainage
2 wks later → D & C

+ Bleeding

- Preg .... comp.
- uterus < fibroid / adenomyosis
- tube .... large TO complex
- ovary .... cr. <

+ pain

- Preg .... Comp.
- uterus .... Comp. fibroid <
- tube .... acute PID, pyometra
- ovary .... comp. swelling "THRIM-PR"

Preg. + Pain

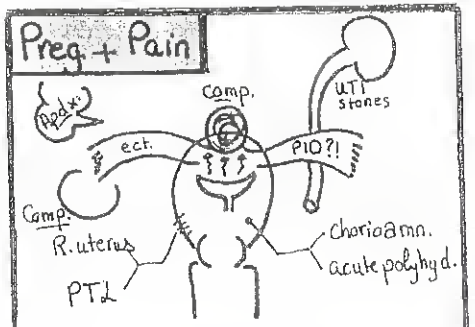

± others < Surgical ... cholecystis / non-surg ... DKA, MVO

Pre-menopausal bl.

- for investigations.....
- most propably.....

DUB

diagnosis of exclusion

أصل سألت عن كل حاجة وطلعت بال -ve

عرفت إزاي

History — No:
- أى أدوية تأثر على coag. أو horm.
- ضغط ، سكر ، مشاكل فى الكبد ، الكلى ، الغدد
- أعراض مشاكل فى الـ coag : تزيف عند الأسنان purpura
- أعراض أمراض النساء المشهورة الأربعة: Pain, bleed., swelling, disch.

exam — No:
- G ← ضغط ، قلب ، سكر — metastasis, jaundice, Wirchow
- A ← كبد ، كلى ، إستسقاء — pelvi-abd. swelling, sister M. nodule
- L ← No uterine/ adnexal swelling, cx is not suspiscious

إزاي تتأكد

inv. — كلها -ve

- general ← CBC, coag. profile; sugar; liver, renal functions
- local ← أهم — لا غنى عن الـ U/S
  - endomet ← D&C
  - cervix ← Pap
  - ovary ← T.markers ± Doppler

إيه العلاج

1] Medical
- Bleeding: - iron, anti-PG - Hemostatics - C.O.C. - أعلى الـ "E"
- Infertility → induction of ovulation.

لو فشل

2] D&C (both ✓)

لو فشل

3] Hysterectomy — آخر حاجة بعد ما كل ده فشل أكتر من مرة (إيه السبب ؟)

Fibroid

A. ✓
- Bleeding ..... menorrhagia / metrrhorrhagia
- Comp. ..... (1/3) infertility (functional, anatomic)
- Discharge
- Enlargement, Pain, Pressure, Preg.

G: anemia, rarely → polycyth.

A: Firm? Painless? Mobile?

L: swelling (pelvic, pelvi-abd.) (Symetrical, asymet.).

إزاي تتأكد

U/S
- إمتى تكون الصورة مش واضحة ↓
- إيه تانى ممكن أتأكد بيه ↓
- إيه تانى ممكن يتعمل قبل العملية

إيه العلاج

طالما محجوزة جراحة

(mostly hysterectomy in that age)

- What are other indications
- Is hyst. more difficult > myomectomy? Why?
- What are other alternatives

إزاى تسأل على النزيف ؟!

1) الدورة
- menorrhagia: دورة طويلة أو تقيلة
- metrorrhagia: دورة ملخبطة
- polymenorrhea: بتجى مرتين فى الشهر

2) النزيف
- Amount: تقرفها من عدد الفوط = napkins وأد إيه مع soaked, stained غرقانة
- Clots = severity
- Coitus = contact bl
- bl. from other sites = general cause
- effect on g. condition
- ttt received

Post-menopausal

abd. uterus →
فتحة cx →
Sound →



Cancer endomet

most serious 10% فقط

- Age > 60 yrs
- Parity: low
- Race: white

Risk factors

Sympt.

any PMB is considered cr. end. ← إمتى يبقى في سن صغيرة ؟

genital prolapse

if ± vag. swelling

?! الأوقع cr. ovary

Risk factors

p.pt factors ... ⇑ abd. pr.

RVF وراثي ..... AVF ..... الحمل
weak ..... Lig ..... الولادة
nerve ..... ms
bone ..... Est ..... menop
x تاد
common

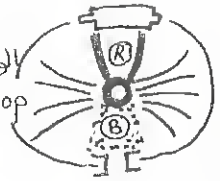

عرف إزاي

* History

* exam.

G. يسر ⊕ CCT.

A. except (small uterus

L. nothing

types
1] ut. 1. 2. 5.
⊕ comb. 2] vag Ant Post Vault

- thickening
- Stretch
- inflection (tr. ulcer)

urinary ± SUI

Sympt

D_s^6 : lig - Swelling - V_s: cong. sympt. = Kink

Rectal

إزاي تتأكد

1) Screening: TVUS 4-5 mm
2) Confirmatory
   - إيه الأكتر → D&C
   - إيه الأصح → Pipelle
   - إيه الأدق → hysteroscope

inv. No need

- type
- degree
- comp
- SUI

Palp

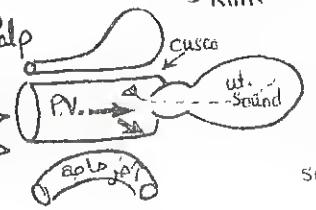

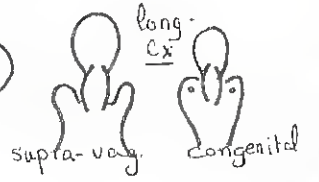

إيه العلاج

حسب ال stage

أحسن Prognosis

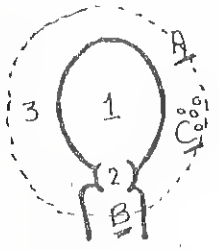

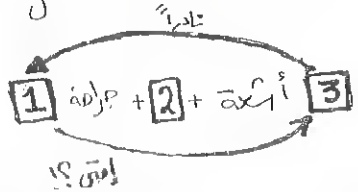

nodes +ve
½ myomet. } mac. | mic. < grade II, III / Papillary, serous

VH + PFR

كبيرة

صغيرة sling

Father Gill ← لو مش عايزة تتحمل ⊛

de-Fort ← لو كبيرة أوي ⊛

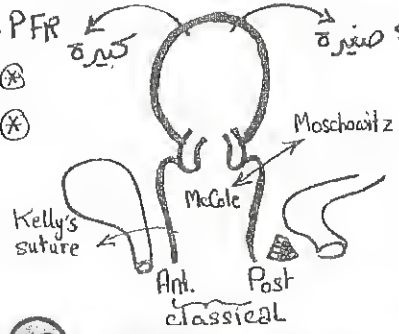

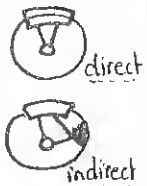

colporaphy =
1) incision
2) dissection
3) Plication
4) Removal

مش ممكن يكون السبب حاجة تانية ؟

↓

Yes

1) Dysfunctional نعم يا هوا !!
2) other tumors ..... cr. cx / cr. ovary
3) HRT
4) Atrophic v. vaginitis or/ senile endometritis ! most
5) Uterine polypasis

Corporeal	cervical
1. Fibroid	1. Fibroid
2. Adenomatous	2. Mucous
3. Malignant	3. Malignant
4. Placental	4. Granulomatous

* C/P for all
  - Bleeding
  - Pain
  - Discharge
* Ttt for all
  - Polypectomy ± D&C
  - send for histopath.
* How to differentiate bet. them
  - uterine sound
  - U/S
  - hysteroscope
  - HSG

Other tumors

Cancer cervix : CIN

if ± contact bleed.

HPV 16, 18
- sexual intercourse
- multiple partners
- esp. if at 18 yrs

Risk factors

Sympt
35-45 yr.

any contact bl. is considered cr.cx.

DD. → uterine polyps (cx / vag.) } inf. or malig

عرفت إزاي

History

Risk factors
- Age --- old age
- Parity ... low
- Race .... familial < BRCA / Lynch II

Sympt. → D. D. D. (non-specific)

exam.

uremia ⊕ G. ⊕ endocrinological / Meig synd.

A. → hydronephrosis ; → omental cake, sister Joseph Mary nodule

L. → suspicious cx < nodule, ulcer, cauliflower mass
- ☐ unilat. / bilat.
- ☐ mobile / fixed
- ☐ cystic / solid
- ☐ painless / tender

إزاي تتأكد

inv.

1. **Screening : Ayre's spatula** ↳ Pap smear < every 1 yr in high risk / every 3 yrs in others
2. **Confirmation : Colposcopy**
   - epith.
   - vascularity : punctate
   - acetic acid : white areas
   - Schiller I_2 : yellow areas
3. **Biopsy** (colp. guided)

Cone : زمان

LLETZ / LEEP : حديثاً

Bethesda classif.

- **L.G. SIL** → CIN I, HPV → follow up after 6m. & ltt of inf. → local dest. by cautery [tri-chloro acetic acid]
- **H.G. SIL** → CIN II, CIN III → follow up [illegible]

young < cautery, LEEP, cone

old : hysterect.

إيه العلاج

Ca ovary

germ, epith, sex cord, stroma

♀ f. gran. / theca — ♂ sertoli / Leydig

inv.
- lab : T. markers e.g. CA_{125} $CA_{19.19}$
- scan : Radiology — إمتى أعمل على الـ GIT ؟
- scope : endoscopy
- biopsy : by exploratory laparotomy — دي الحاجة الوحيدة الأكيدة ✓

therapy — إزاي تعرف الفرق ؟!

Benign
- ☐ cystectomy
- ☐ oophrectomy
- ☐ TAH + BSO

malig.

Optimum debulking = TAH + BSO, lymphadenectomy, omentectomy

⇓

Chemotherapy < CAP : epith. / BEP : germ

مش ممكن يكون السبب حاجة تانية ؟

↓ Yes → **"T.B."**

organism — Mycobact. tuberc. (human) > bovis

Route
- blood borne (lung)
- Peritoneal
- lymphatic
- ascending é semen

Pathology
- Tubercles
- caseation
- Polypi
- Ulcers ✓ 25

C/P
- * Night
- * Loss
- * cachexia
- * Pelvi-abd swelling

100% ... PID

50% menst irreg. < bleeding / amenorrhea

5% Polyps ... ulcers

Inv.
- G.
- chest x-ray
- ESR
- HSG .... laparosc.
  - Sausage, beaded
  - lead pipe, segment
  - everted fimbria
- D & C ....
  - Zeil Nelson
  - Low Jensen
  - G. Pig inoculation
- biopsy

ltt

1. Young & infertile
   - medical ltt 6-9 m
   - if failed → salpingectomy & ICSI (no tuboplasty)
2. Hysterectomy < old age, large masses, ulcers, fistula, irreg. bleeding

CBP

Anovulation

if ± كحة في الدورة

- hyper-androg. → Hirsutism
- ROS → SOHA, pre-menst. spotting
- hyper-prolact. → galactorrhea

All may lead to

Amen.

β-HCG → Prog. ch. → E & Pr. ch. → LH, FSH

T3 T4 TSH → prolact.

علاج السبب

1ry — لاتنى الانتاج

2ry — لاتنى الأكل

Bleedig.

organic: Gen. / Local — obst. gyna

funct.

Fe + Anti-PG

Horm. / D&C → Hyst.

infertility

1st
- exclude الزوج ✓
- then
  - Ovary: PCO... U/S, LH/FSH
  - Tube: PID... HSG
  - Perit: E∅... Laparoscopy
  - Ut: Ascherm... hysteroscope
  - cx: infect... C&S

induction of ov.

tubo-plasty / lap. ov. drilling → ART

fibroid

if ± swelling

عرض إزاى

* History
* exam.

إزاى تأكد

إيه العلاج

الشكوى ممكن تكون

- Bleedig: pain + bleedig → submucous
- Swelling: abd. / vag. — إحساس بالثقل
- infertility: بالذات → anat. / funct.

إيه أنواع الـ degen.؟

- حوه [2] * hyaline (myx) * Pseudocystic
- بره [2] * fatty * calcif.
- [2] * حمل: red deg. * أكل: atrophy

العلاج في السن دة أكيد

- Polypectomy D&C
- Myomectomy

How to ↓ bleedig.

قبل العملية
- raise Hb%
- LH-RH
- Post-menst.

أثناء العملية
- Arteries < ut. / ov.
- fibroid: vasopressin
- incisions: ant., midline

Bonney عمل إيه

1. clamp
2. screw
3. Hood operat.
4. elevation test (SUI)

إيه أسباب الـ amenorrhea

* Phys. <12 ... >45
* Path

True
- .Cong
- .Tr
- .Infl
- .Neop
- .Misc.

False = crypto → imperf. hymen

IV, III, II, I — ± general لاتنى

1] Uterus Absent
- Mulleri an agenesis
- Test. Femin. Synd
  - ♂ test. level
  - no hair
  - طويلة

2] Breast Absent
- E. = Hypogonadism
  - Hyper-Gn = Turner
  - Hypo-Gn = cong. ∅ Hypoth, Pit

3] Both present

Acquired causes
- PCO
- hypeprolact.
- hyper andr.

(±) cryptomen.

rare 4] Both absent — cong. enz. deficiency

CBP

PID

Org.
- Non-specific
- STDs < gon, chL / viruses / monilia, TV
- chr. gr. dis

Pdf
- abst < lab. abortion
- gyna < D&C / IUCD
- SI

Route
- Ascending
- Direct
- Blood

Acute ---------- Chronic

peri-salpingitis — Adhesions
catarrhal — TO cyst
Suppurative — TO abscess

criteria ⟵ Comp ⟵ الحالة

criteria: major (1) ⊕ minor

major:
- tenderness
- adnexal
- Cx motion

minor:
- fever
- mass
- org. ± pus

Comp:
- infert.
- ectopic
- spread

الحالة: gon. / chL — زمان 40% / الآن 60%

Proph — Medical — Surgical

1. A
2. A
3. A

1. A
2. A
3. Antibiotics → CDC recomend. ✓
   - الأول: Ampicillin / Gentamycin / Flagyl

laparotomy < if pus ... drainage / if mass ... removal

adnexect. : young
hysterect : old

Endometriosis

عوامل إزاي

History

Risk factors
- Age ... CBP
- Parity ... Loco
- Race ... Caucasian

Sympt
- Triad
  - Pain (6ds) ✓
  - Infertility — Phys. / Anatomy
  - Bleeding

Exam.
- G. ← toxic
- A. ← cong. (pain, bl, disch)
- L. ← tender, cx mov. & adnexae, ± masses, ± RVF

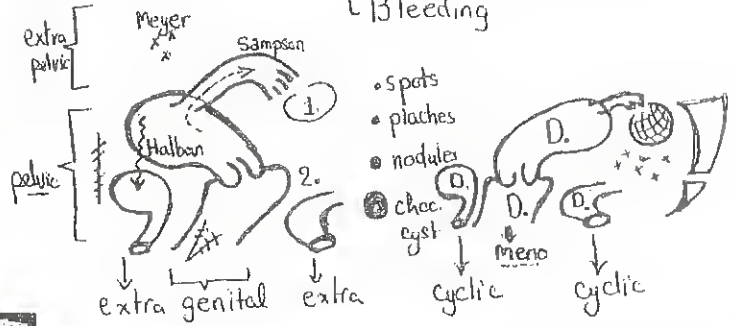

إزاي تتأكد

inv.
- ESR, TLC
- Swab
- mass. U/S
- laparoscope

laparoscopy < Diag / therap
الأساسي

nodules
adhesions

	min	mild	mod.	severe
ov.				
F.T.				
D.P.				

± U/S
± CA125 for follow up

إيه العلاج

حسب الشكوى
- Bleeding ... أعلى الـ est
- Infertility
- Pain

- Progest 10mg 1x3
- Danazol 200 mg
- Dimetriose 2.5mg
- LHRH analogue

Surgery — laparoscopy

زهقت
TAH ± BSO
كبرت في السن

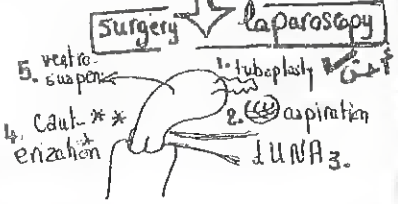

مش ممكن يكون السبب حاجة تانية ؟!

1] Cong. xx
2] Traum. ... IUCD
3] Inflam ... PID
4] Neop < B... fib, polyp / M.. CIN
5] Misc < Prolapse / Anovaulation e.g. PCO

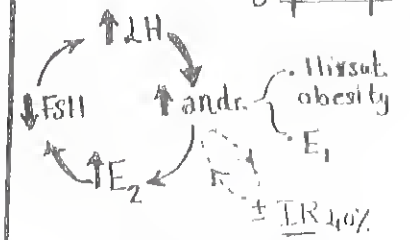

Rotterdam criteria
- C/P ... SOHA
- U/S ... Adam (necklace)
- Inv ... LH/FSH 3:1, Andr↑

ttt — العلاج حسب الشكوى

بس لازم weight↓ الأول

- hirsut → Flutamide / Finasteride ; ↓SHBG → derm xx
- Bleed → COC → D&C → Hyst
- Infert → Clomid ± HCG ± cidephage → Laparose. → IVF & ET ; COC → Ov.

Cases
Keyword: Amenorrhea

Amenorrhea

صغيرة

- Cyclic pain → crypto-menorrhea
- +ve br.
  - M. agenesis
  - TFS
- -ve br. → Turner

حامل

أول اختبار B-HCG (+ve)

Triad: amen. < Pain / BL

- ectopic
- abortion
- V. mole



كبيرة

- تحت 40 → Infertile → Anovulation
- 40 + hot flushes → POF
- فوق 40 + hot flush + Rt. pains → menopause

Miscell.

- Post
  - partum → Sheehan
  - D&C → Asherman
- 1.
- 2.
- 3.

- + Acute abd
  - acutely dist. ectopic
  - compl. ov. cyst (funct.)

- + bleeding
  - HPO axis → anovul.
  - uterus → حامل

- + swelling
  - Pregn.
  - crypto-menorrhea
  - ov. swelling

	صغيرة				حامل				كبيرة		
C/P	- Pelvi-abd swelling - Bluish bulging memb.	Normal looking ♀	. Tall . well develop breast . No axill. hair	- Short - Webbed neck - Cubitus vulgus	dist. → collapse + cx motion tend.	undist thr. → mild pain ⊕ spots	inevit. → severe colick + cx opened	- high FL - No fetal parts - bilat. T2 cysts	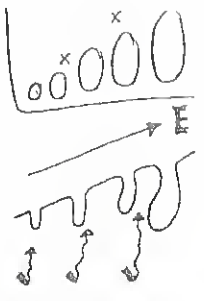	D i d C I A	(·)
Inv.	clinically diagnosed	U/S Absent uterus "T" normal 2-8 ng/dl male 300 ng/dl		Karyotype FSH ⇧ "hyperGn hypogonad"		serial . TV-US . β-HCG ± laparoscopy		. U/S snowstorm . HCG high . chest x-ray	Amen..... bleed. (short) P P I 1. PCO → SOHA 2. Pr. → galact. 3. Andr. → hirsut.	⇧ FSH DEXA LDL, HDL	
ttt	cruciate incision	vaginoplasty Surrogate mother ?! gonad-ectomy at 18yr		HRT "gonad-ectomy if mosaic"		laparotomy	D & C	Suction evacuation	Rotterdam criteria N: 2-20 N: 2-8 0.2-0.8	HRT versus . SERM . Tibolone (liveal) . Agreal . Bi-phosph. (fosamax)	

Amenorrhea

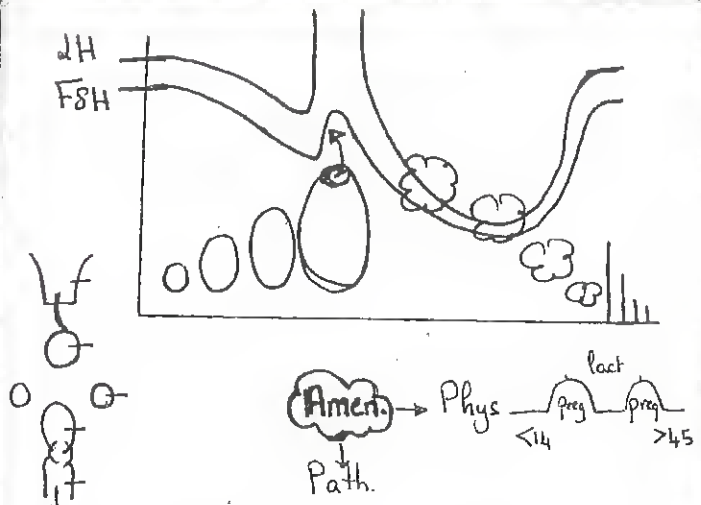

	H.	Pit.	Ov.	Ut
Cong				
trauma				
infl.				
Neop.				
Misc.				

1ry → true / false: crypto = imp. hymen

2ry → exclude preg
1. PCO
2. hyper pr.
3. hyperandr.

⊕ general < drugs, endocrine, gen. debilitating

evaluation

1ry
- inspect vulva
- inspect Br.
  - −ve: Turner (Karyotype)
  - +ve: M. agenesis (pelvic U/S)

2ry
- T3,4, TSH — β-HCG — prolactin
- Progest
- E + P
- obese → PCO; galact → prolact.; hirsut. → test. ± if

PCO

Def. It is a synd ccc. by SOHA

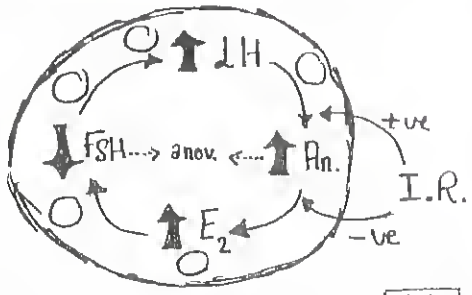

Diag. C/P + Inv. + U/S

C/P	Inv.	U/S
S.	. LH/FSH>2	. Necklace ap.
O.	. ↑ androg.	. Adam's ap.
H.	. IR	. N. in 25%
A.		

amen ← Anov. → Bleed.

↓ Infert.

Diagnosis

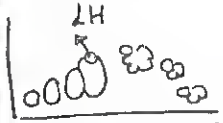

TV-U/S "folliculometry." (18-24 mm)

Progest "mid-luteal" < >10 ✓ / 5-10 ? / <5 ×

LH Kits in urine → predictive

Progest. effect
- G: ↑ BBT by 0.3°C
- L: PEB < sec ✓ / poor ? / profit ×

ttt

Clomid	±	HCG
Anti-E → ↑ GnRh & Gn.		Natural: بول الحوامل
Dose < 5 mg, 5, 5 – 5 يوم		Synthet: DNA recomb.
Side effect: . hot flush . toxins . OHSS		5.000-10.000 IU when "18-22 mm by TVUS"

FSH	LH
. Better results, but more expensive < si de eff.	
. different schedules	
Natural < HMG (human) بول الحوامل; purified FSH : LH 75 : 1 ??	
Synthet: Pure FSH	
×× GnRH الحقنة	

الحقن .... given in pulsatile manner

Bleeding

Organic

G] coag. f., Horm.

L] → obst. / → gyn. } Congest.
- cong: double ut
- tr: IUCD
- infl: PID
- Neop: ♂ or ♀
- Misc: - Contracept. - Prolapse

Dysfunct.

Diagnosis

- History
  - age
  - marital st.
  - menst < reg. / irreg.
  - contr.
  - Past
- Exam. G .... A L
- Inv.
  - lab: CBC, coag., tum. mark.
  - scan: U/S
  - scope
  - biopsy: tumors

ttt

- Drugs
  - medical < hemostatic, anti-fibrinolytic
  - hormones < anti-PG
- * meast. irreg — .... progest, COC
- * contr. .... COC .... mirena
- * infert. .... ind. of ov.
- * من الآخر < synth. andr.. danazol / GnRH in cont. manner
- minor surg < D&C ... تاني هارجع / hysterosc. end. ablation
- major surg: Hysterectomy

Anov.

14 funct. ov. cyst
20 meast irreg.
24 Infert.
26 PCO
30 unopp. ↑ E.
40 Peri. MB (DUB)
45 End. hyperp.
60 End. cr.

* fibroid * EØ * Polyps

⊕ Infertility

EØ, PID, fibroid, cx, PCO

20 → Ago
30 → OTA
50

if any ttt failed ⇒ ART

Amenorrhea

D.D.
- oligo-hypo ⇝ Bl < P, P, I
- Post < Sheehan, Partum, D&C, Asherman

etiology
- .PCO: ↑Andr, ↑LH, ↑E, ↓FSH
- .hyper-pr.
- .hyperandr.

← idiop. →
← iatrog. →
← ovary →
PiE. ←→ Adrenal

History
- S...
- O...
- H...
- A...
- Galact. ± PMT
- hirsutism ± viriliz.
- ↳ Anovul. ↲

Exam
- Bilat. adnexal swelling
- Squeeze ↓ breast
- midline sexual hair

Inv.
1] U/S
2] LH/FSH, ↑ Andr
3] Anov.
- Prolactin: 30... PCO; 200... CT brain
- testosterone: N... fam.; ↓↓c < PCO, tumor

ttt.
- Cidophage (oral hypog.)
- Parlodel (bromocrypt.)
- Androcure (cyprot. acetate)

→ induction of ovulation

Pain

- .EØ
  - extra-ut.: genital, extra genital
  - uterine → Adenomyosis
  - unopposed ↑E
  - ⊕ theories
  - Triad < Pain ✓✓✓, infert. ✓✓, bleed. ✓
  - .Tender, .Fixed, .Nodular
  - laparoscopy ± biopsy
  - masses, adhesions: +ve → surgery; −ve → induction
- .PID
  - TO complex + Adhesions
  - → Chlamydia ✓
  - → Gonorrhea ✗
  - - fever
  - - lower abd pain
  - - discharge
  - major: T., T., T.
  - 1 minor: G.... fever; A.... mass; L.... C&S
  - inf. → .TLC, ESR; .C&S.
  - mass → .U/S; .Laparosc
  - salpingectomy followed by "ART"

Swelling

- .Adnexal < Neop ✗; Non-neop. < EØ, PID, PCO
- .Uterine: Fibroids, Polyps
  - unopp ⇧E
  - ± disturbed phys.

A, B, C, D, E

3 < P, P, P

swelling < Pelvi-abd, adnexal, Br. lig., D. pouch

U/S ± < HB%, IVP

Myomectomy

Bleeding

- .Menorrhagia < EØ, PID, fibroid
- .Pre menst. spotting = C.L.I
  - LH, FSH → Formation [1] → [2] luteolysis → sec. end → [3] end. insensitivity
  - .EØ, .hypothyr, .hyperadr, .hyperpr

1 sympt ..... PM spotting

2 comp: habit ab., infertility

3 inv: BBT, Progest '3-12', PEB 'lag 2-3d.'

- .Progst in 2nd ½
- .HCG day 14
- .Proper induction

Discharge

- .lower abd: PID
- .backache: Cx
  - 1) Non specific
  - 2) STD < bact., virus, Chlamydia
  - 3) chr. granul.
  - - fever
  - - backache
  - - discharge
  - Cx. motion tenderness ⊕
  - inf. → .TLC, ESR; .C&S
  - infertilit → Post-coital te
  - Anti-biotics → cauterization → .AIH

Pain in Gyna

مع الكل
لا تنسى

1] Idiopathic
(psychogenic)

2] Non-Gyn
- urinary
- intestine
- Musculoskeletal

surgical أو medical

3] Early preg.
Comp. وهي كمشي عادية
e.g. ectopic

212 مهم جداً

Pelvic pain :-

Acute
THRIIM
- Ovary ... if complicated
- Tube .... acute PID
- uterus ... comp. of fibroid

Chronic
- cyclic < Dysmen., PMT, cryptomen.
- acyclic (causes of p. cong.)
  - Traum ..... IUCD
  - Infl .... chronic
  - Neop .... B ... M
  - Misc. .... prolapse

Low Backache
- uterosacral lig. على أي شد
  e.g. - Prolapse
  - cx esp. chr.
- mass أي في Douglas pouch
  e.g. - EØ
  - cx fibroid

Dyspareunia
- superficial : vulvag.
- Deep : lesions in D. pouch

nodules
masses

Genital tract traumas

1 Surgical
- Incision < dehiscence, Keloid, Burst
- Vs ..... hge
- Ns ..... Parasthesia
- Organ .... loss of funct.
- Viscera ... adhesions, fistulas

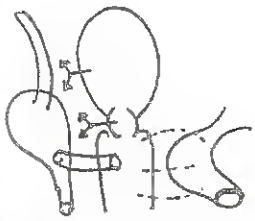

- Misc. ... missed towel

2 Direct
- القاهرة accidents < Burns, Stabs
- الساحل الشمالي — Foreign bodies
- الصعيد — Circumcision
  1) clit.
  2) + L. minora
  3) Sudanenese
  4) un-classified
- الخليج — sexual abuse
- لا تنسى
  contraception
  IUCD
  Ring Vag.
  Pessary
  if neglected

3 Obst (! Commonest)

Mother
- Rupture
- tears < Prolapse, fistula, incont.

Fetus
201 / 202 كلها جداً (سؤال نظري) متوقع

1) Head — لا تنسى المقارنة بين cephalhem. & caput succ.
2) Musculo skeletal fractures
3) Periph. nerve < Erb's, Klumpke's
4) Soft tissue ... Rupt. spleen

Gynecology = Dr. Mohamed El-Mahdy

Discuss Child "hood" Gynecology

Cong.

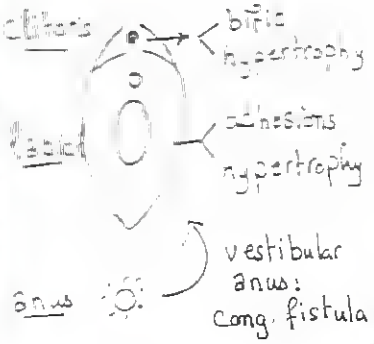

Cholest → 27 → 21 Progest → X → Cortisol
Progest → Andr. → Est.

Cong. Adr. hyperpl.
(Adreno-genital syndrome)

etiology: def. enz. < 21 hydroxylase / 11β hydroxylase
↳ deficient synth. of cortisone ↓
↳ hyperplasia ← ↑ ACTH
↳ ↑ synth. of androgens

Types: juvenille / adult
C/P: ↓ cort. ... neonatal shock ... Cortisone for life
↑ andr. ... ambig. genit. ... surgical correction
Inv.: ⇧ 17αOHP

Traumatic

- Sexual abuse
- accidental trauma (F. body)

circumcision:
- type I : clitoris
- type II : + labia minora
- type III : + labia majora (Sudanese)
- type IV : unclassified.

Inflamatory

Due to absent "E" < thin vagina. / decreased acidity.

1ry
- Cong. ... cong. fistula, ectopic anus → parasites
- infl. ... transmission from adults → STDs
- traum. ... acc. FB in vag. ✓ → non-specific
- neop. ... sarcoma botryoides

2ry
→ chemical irritation : diaper rash
→ poor hygiene : الجو حار وبارد

ttt
1) General : antipruritic
2) Specific : Abs acc. to C&S
3) if resistant → "E"
4) if persistant → x-ray [search for FB]

Neop.

Sarcoma botryoid
- Grape like
- occurs in 1st 2-3 yrs
- Aggresive

Germ cell tumors

- Dysgerminoma
  - malignant
  - esp. if dysgenetic gonad
  - secretes HCG ⇝ pr. pub.
- Endodermal sinus tumor
  - very < rare / aggresive
  - secretes α FP

Miscell.

Precocious

Types
→ incomplete
→ complete
- isosexual < true (central) / false (periph)
- heterosexual

Inv.
→ Horm. profile < Est., and LH, FSH / $T_{3,4}$, cortisol
→ Radiology < x-ray hand / CT brain / pelvi-abd U/S

ttt: acc to cause

Delayed

< 14 yrs without 2ry scc
< 16 yrs with 2ry scc
No menarche for 5 yrs after thelarche

	H.	P.	Ov.	Ut.
Cong.				
	HypoGn hypogonadism		HyperGn hypogonadism	NormoGn
	↓ FSH < 10 mIU/ml		↓ FSH > 30 mIU/ml	↓ U/S

Gynecology - Dr. Mohamed El-Mandoh

Manifestations of ♀ G.T. anomalies

⊛ Introduction

♀ GT is developed from various origins

- The ovary is developed from ! urogenital ridge
- The tubes, uterus, cx, upper 4/5 of vag. : Mullerian duct
- The lower 1/5 of vagina & ♂ vestibule : U.G. sinus
- The ext. genitalia < clitoris : G. tubercle; L. min. : G. fold; L. maj. : G. swelling

⊛ Classification

anomalies may occur in ! following organs

- → Vulva : Ambigious genitalia, labial hypertrophy, adhesions
- → Vagina : Absent (as in < M. agenesis, TFS), imperforate hymen
- → Cx : Patulous int. os, cong. elongation
- → Uterus : Absent, hypoplasia, fusion defects < septum, bicorn., unicorn., rudiment. horn
- → tube : Hypoplasia, accessory ostium, divert.
- → ovary : agenesis, dysgenesis (Turner ♀).

⊛ Manifestations

Gynecological

- Newborn : Ambigious genitalia
- Puberty : 1ry amen. < False : crypt. < imp. hymen, Tr. vag. sept., cx. atresia; true 1. Turner 2. M. agenesis 3. TFS
- Adolescent : Menorrhagia, Sp. dysmen. } Bicornuate
- CBP : - infertility < ov. dysgenesis (Turner), Mullerian agenesis, tubal anomalies; - dyspareunia < vag. septum, cong. elong. of cx
- Old age : tumors < Dysgenetic gonads : Dysgerminoma; Vag. adenosis : DES
- Association : Renal 30% ---- IVP ✓; Skeletal 15% ---- X-ray

Obstetrics

Most anomalies are asympt. & its 1st presentation may be during pregnancy

* Early preg
  - → Habit ab. (± PTL) < cx : Patulous os; ut : sept., bicorn.
  - → Ectopic < tubal anomalies, rudimentary horn
* late
  - Malpresentations (Breech, Tr. lie) due to abnormal ut. cavity → altered accomodation
* labor
  - Prolonged, Obstructed } malpresent.
* PP
  - Atonic :- رحم مترهل
  - Retained pl :- pl. accreta.

Gynecology - Dr. Mohamed Elsamook

OBSTETRICS

1. **Def.**
2. **%** 1 ..... 10 ..... 50 90
3. **Pathophys.**

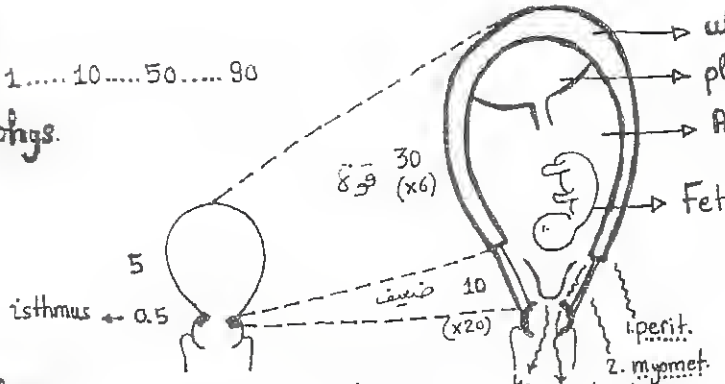

- uterus < PTL .... tocolytics; Post-term .... ecbolics < PG, oxyt.
- placenta ..... bleeding <
- A. fluid ..... ⇧ poly ... ⇩ olig .. # PROM
  - infection ← علشان كده بيفرقع في الولادة جي عند ٣-٤ سم
- Fetus
  - حجمه ↓ IUGR ↑ macr.
  - شكله < مشوه: CFMF; بورم: H. fetalis
  - عدده

4. **Etiology** ..... idiopathic ..... iatrogenic
   - >50% — أدوية
5. **Types** — Mother ..... fetus ..... local
6. **C/P**
   - G: anemia / shock
   - A:
   - I: P.V. < not done if < ROM, bleeding; done mainly at 37 wks (to assess labor)
   - → Palpation; Auscultation: FHS

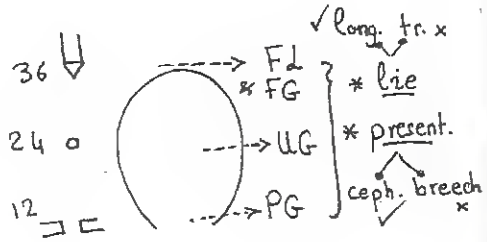

7. **D.D.**
8. **Inv.**
   - A: Etiology
   - B: في الآخر → FWB → 1. History: fetal Kicks; 2. Exam: FL = amen.; 3. Inv :- مهمة →
   - C: Comp
   - D: Diagnosis
   - E: في الأول → routine

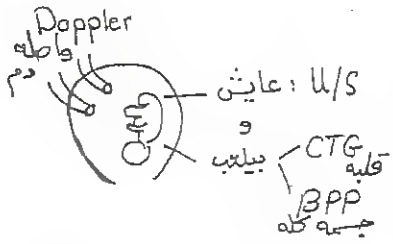

9. **Comp**
   - **M**
     - 1. Preg. (حروف "م")
       - PET
       - Pyeloneph
       - PL. previa
       - Polyhydr.
     - 2. Part.
       - 1st stage: Prolonged; PROM < inf., cord prol. — كلها نتيجة إن الرأس مش لابسة كويس على الـ cx ← unengaged; نتيجة في ← malpresent
       - 2nd stage: Prolonged & obstructed
       - 3rd stage: PPhge
         - ms fibres ..... atony
         - intact ..... traum.
         - ut. empty ..... retained pl.
         - Coag. syst. ..... DIC
     - "S" 3. Puerp.
       - Sepsis
       - Subinvolution
       - Secondary PPhge
   - **F** (حروف مشهورة)
     - CFMF
     - IUGR
     - PTL
     - IUFD
10. **Mt**

Conserv.

- mild ← المرض
- not in labor ← الأم
- not distressed ← الجنين
- → control < hospit., ANC
- → الكمن ..... comp < inv., drugs
- ..... maturity: تحسين بالـ steroids — Amniocentesis (L/S ratio)

TOP

- V.D. ✓
- AROM ✓
- ± oxyt ✓
- [if cx is unripe → local PG]
- cx is fit u induction
- no fetal/mat. distress
- no assoc. obst. cond. → e.g. contracted pelvis, placenta previa

الكمن **C.S.**
- LSCS ✓
- USCS ×

General Obst outlines

- Lie: longit.
- attitude: flexion
- presentation: ceph.

الحل ↑ **Accomodation** ↓ الولادة

كل الحكاية إن راس الطفل نازلة بالعرض لكن لازم تطلع بالطول

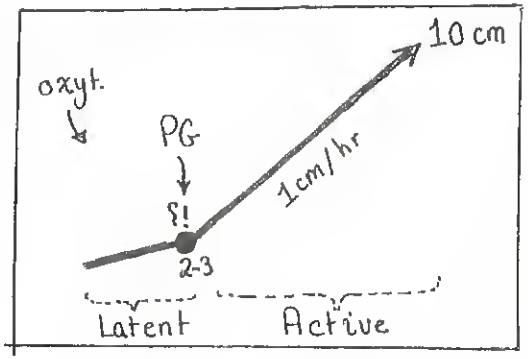

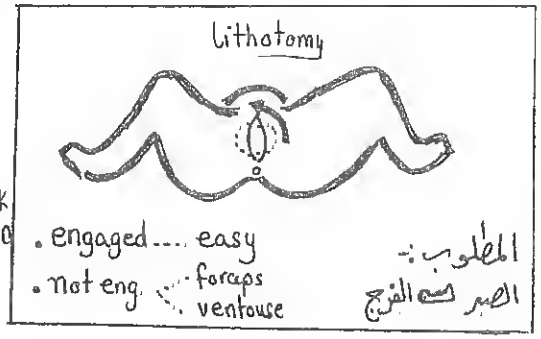

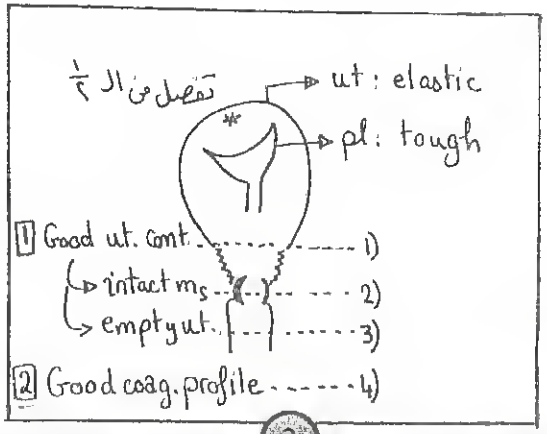

1st stage

- cx dil.
- S.ROM } فترة طويلة

المطلوب ↓ المراقبة

M / F } = Parto/gram

أصلاً الولادة على ورقة مسجلة

2nd stage

* descent
* engagement
* int. rotation

تلف الرأس

levator ani

3rd stage

Guard against PPhge

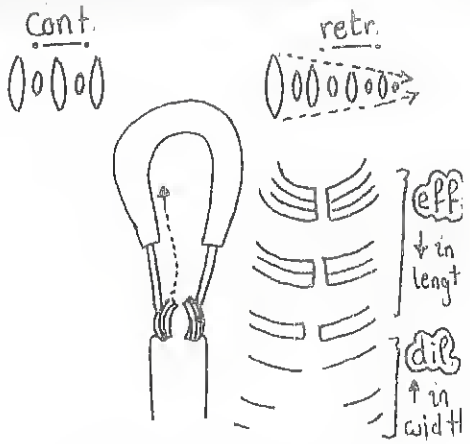

بس لازم الأول يكون الـ cx
↳ soft .... Ripened: PG ✓

Ut.

* Conserv. < فين: البيت / المستشفى
  إيه المتابعة: أدوية ▣ FWB ± steroids

* Termin
  1) إمتى
  2) إزاي
  - V.D. ⇒ AROM 1hr ..... oxyt.
  - no CPD { good ut. cont.
  - C.S. ⇒ LSCS > USCS
    - fit for induction
    - no f/M distress
    - no ass. obst. indic.

Inv.

3. واصلة دم
1. عاش
2. ويلوب

- Doppler: bl flow < umb. / uterine
- U/S < placenta: Ca^{++} = > 32 wk / Amn. fluid: AFI = 5-20
- CTG & BPP



Comp

1 Preg.

M] حروف ال P s

F] ٤ حروف منتورة

2 labor

1st stage < Prolonged / PROM

2nd stage --- prolonged/abst.

3rd stage < PPhge / P. sepsis

5 F

Diagnosis 1st trim

① Symptoms
- Amenorrhea (not a sure sign)
- Morning sickness
- frequency of mict.
- Breast symptoms
- Appetite changes
- Mood changes

② Signs
- Breast signs
- Genital signs
  - Jaque-Meir
  - Chadwick
  - Goodell
  - uterus → Palmer contract. / Hegar sign (6-12 wk)

③ Investigations
- Preg. test
  - Latex 500 IU
  - Elisa 50 IU
  - RIA 5 IU (imp.)
- U/S
  - TU → 5
  - TA → 7
  - Sonicaid → 10

Endocr. glands

1] Pituitary
↑ size (esp. ant.)
↑ prolactin ↓ FSH LH

2] Thyroid
- slight enlargement (↑TSH) & C toxicosis ↑ thyrotropin
- ↑ thyroid hormones (but free level remains free) as TBG ↑

3] Parathyroid
↑ parathormone to ↑ Ca++ abs.

GIT
- 1. longing (picka) الوحم
- ↑ salivation
- morning sickness

Breast
- 1st weeks → tender, tingling
- 2nd m. < 1st areola pigment / Montgomery tubercles
- 3rd m. → Colostrum
- late months ↳ 2ry areola

GIT
- 2. Heart burn
- 3. cholestasis, ↑ globulins
- 4. ↓acidity, delayed emptying

4] Supra-renal
↑ free & bound corticosteroids

Kidney
(↑ size 1-1.5 cm)

RBF ↑ → GFR ↑ 50%
- ↑ clearance < crea., urea, BUN, glucose, a.a., H2O sol. vit. } ↓ plasma level
- ↓ renal threshold

Ureter
- dilated أكتر على
- Pyelonephritis

Bladder
- Displaced up
- Frequency of mict. < 1st trim. / last month علامة من علامات الـ ....
- SUI ?!

CNS
Mood: elevated / depression
Sleep: over / insomnia

Skin
- 1] chloasma gravidarum < E may have MSH like activity / chronic MSH / ↑ placental & adrenal steroids
- 2] striae gravidarum
- 3] linea nigra
- 4] Diviarication of recti
- 5. constipation & piles

Resp. (d.t. progest.)
↑ < dyspnea → Pressure effect
- min. O2 uptake
- min. resp. volume
- tidal volume

Heart
- ↑ C.O.P. 30-50% (SV x HR)
- displaced (with ESH)
- Sounds → split of 1st / S3 / soft syst

blood
- Pressure ↓ in 2nd trimester
- Volume ↑ 40-50% (30-34 wks)
- RBCs ↑ 18-30% (phys. anemia)
- WBC ↑ slightly
- Coag. ↑
- ESR ↑

C.L. of preg.
(till 10-12 wks)

- weight 50gm → 1 Kg
- shape Pear shape
- Parts < IUS (Ring) / LUS (Hegar sign)
- Cont. < Palmer / Br. Hicks

Goodell
Chadwick
Jacque Meir

- Body weight :- 9-12.5 Kg
- Proteins :- +ve N_2 balance (1 Kg protein)
- CHO :- diabetogenic
- lipid :- increased < lipids / cholesterol
- vitamins :- ↑ fat sol. ↓ H_2O sol. فيتا
- minerals :- ↓ serum iron → الحاجة الوصية

↑ مشاكل تحدث يا ميتى الحامل :-

- الأكل * caloric intake 2200 ± 300
- النوم * Rest < ليلاً 8 / قيلولة 2 — على الجنب → ↓ A-C compression / مريحة → ↑ pl. flow
- بالعقول * Exercise * Clothing: loose للحب الطالع → lordosis
- " * Travel → long flights < تمشى / تشرب } DVT
- يا رب * Bathing → tub bath حمام قدم

Diagnosis 2nd trim.

① Symptoms
- Amenorrhea
- ↑ Br. symptoms
- Quickening
  - PG: 18-20
  - MG: 16-18
- Progressive abd. enlargement

② Signs
- Breast
- Genital
  - Braxton Hick's
  - uterine soufle
- Fetal
  - Ballottement
    - internal 16-28
    - external > 24

Sure signs of preg. ↓ + U/S
- Palpation
- inspection or palpation of movement
- Auscultation of FHS or umbilical soufle (funic soufle)

③ Inv.

Abortion

Def. TOP < period of fetal viability < 20 wK / 28 wK

% 15-20%

Etiology
1. M
2. L
3. F.

Pathog.

C/P.
1) Sympt.
G.
A.
L.
2) Signs
G.
A.
L.

Inv.
A
B
C
D
E

Comp.
Hge
inf.
injury

ttt
1) conserv.
2) termination

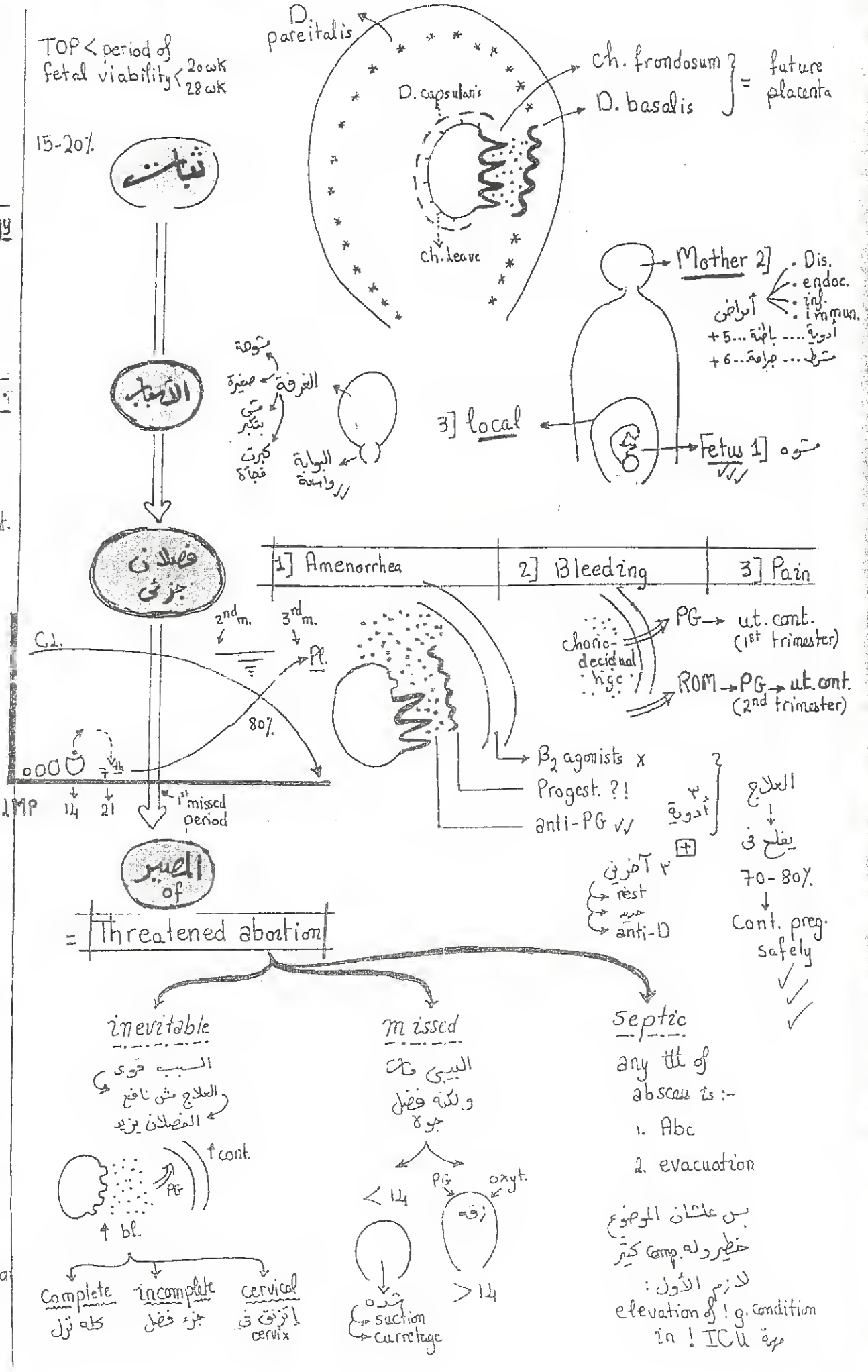

etiology

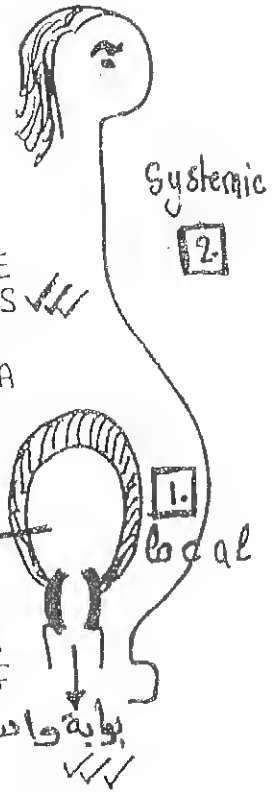

- endocrine
  - CLI ✓✓
  - PCO ✓
  - DM, thyr.
- Immune
  - Auto < SLE / APS ✓✓✓
  - Allo < Rh / HLA
- thrombophilia
- Infection

Systemic 2.

1. Local
  - عيوب خلقية
  - Fibroid
  - Cong. anom.
  - Aschermann
  - Fixed RVF
  - بطانة واسعة :- ✓✓✓

Cong
- ↑ ms fibres
- ass. é ut.
- DES

acquired
- obst.
  - Forceps
  - vent
  - Br. ext
- gyna
  - D&C
  - Ampul.
  - Coniz.

3. fetal

أخر ولادة

4-10%

mainly structural

Assesment

History

- * Personal
- * C/O
  - >3 successive
- * HPP
  - Abortions
  - Comp. ؟
- * Menst
  - ↓
  - ↑
  - PMspotting
- * Obst
  - time
  - order
  - abortus
  - special ccc
- * Past
  - medical
  - surgical < obst / gyna
- * Family

Exam

General
- med. dis.

Local
- ut (fibroid)
- cx (tear) PIOs.
- preg: < U/S better T.V.
- non-preg
  - HSG
  - Hysteroscopy

Fetal
- Post-mortem
- Karyotyping

Inv.

- Progest. 21
- LH/FSH
- PPS
- $T_{3,4}$ TSH
- ANA, $C_{3,4}$
- ✓✓ ALA, ACA
- Rh

ttt

General

- Reassurance
- more rest
- vit., Fe
- stop smoke, alcohol

Specific

* PIOs



* APS
  - Baby aspirin 75mg
  - ⊕ heparin 5000 u/12 or LMWH 30-40 mg

idiopathic 50%

↓

imperical
- Progest
- folic acid
- Aspirin ± heparin

Cerclage

indication
- PIOs
- Septum, bicorn
- triplet

Timing

% of ab. ist ↑ < 11-13 > possible ROM

Post-op.
- → Antibiotics
- → Progest, profenid
- → ↓ I.C.

Comp.

ruptur → inj.
early → inf.

Removal
- 2-3 wks < EDD
- Permanent = Abd. cerc.

Ectopic

1-3 % (increased nowadays)

inf. : أشهر سبب
أشهر مكان : عين = زايدة

Def. implantation any where outside ! endomet. cavity (! normal site).

Sites

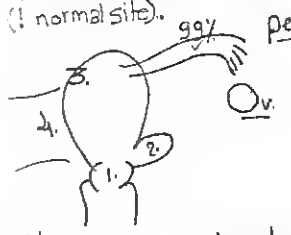

uterine : extra-uterine ✓
(XX)

Etiology

تضييع وقت
'7d'

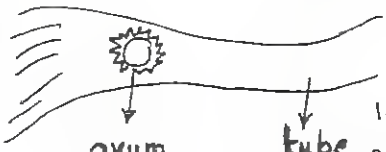

- early disapearance of zona pellucida
- early development of ch. frondosum

1. Cong. بطيء
2. Trauma
3. Infl. (chlamydia)
4. tumor (stretching tube)
5. Others
   - endometriosis
   - prog. contrac.
   - IUCD ✓

Fate

1 Undisturbed 2%

Rare > 12 wk
- thin tube
- poor decidua
- poor bl. supply

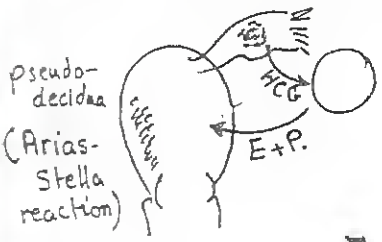

C/P

صعبة

- slight tender swelling
- no shock
- Diagnosed by suspiscion

Inv.

صعبة

أحسن حاجة
Combination
if HCG is > 2000
& U/S is empty
∴ → ectopic
(discrimination zone)

1] TVUS
- may see fetal echo at adnexae
- may be still small
- may be misleading

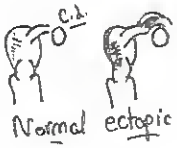

2] β-HCG
- doubling : intrauterine
- subnormal rise < 66% : ectopic
  - ↳ may be aborting ?!

If no one is conclusive
- follow up serially
- laparoscopy ✓

ttt

صعبة

* Laparoscopy (or laparotomy)
* Conservative medical ttt

if
- Sac < 3cm
- β-HCG < 3000
- Hemodynamically stable

1. → methotrexate 50 mg/m² I.V.

2 Disturbed usually at 6-7 wk

Intra-tubal

Extra-tubal

نادرة
- abd. preg.
- Hge

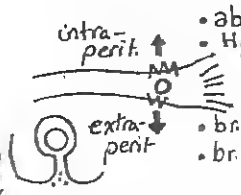

- br. lig. preg.
- br. lig. hemat.

acute abd ↳ shock. — Acute ..... IPhge
مدروسة — Subacute .... peritub. hemat
pr. sympt — Chronic ..... pelvic hemat. in D. pouch

1. Amen.
2. Pain → acute
3. Bleeding

آخر حاجة بسيط

no need : clinical diagnosis

1] G..... shock (variable degree)

2] Abd ... ( ) T. R. RT.
± Cullen's
± shifting dullness

3] PV ... jumping sign
صعبة

resuscitation أول حاجة ✓✓

مشكلة!
laparotomy

- tube
  - 1) Salpingectomy ✓✓
  - 2) Salpingotomy صعبة
    - if ممكن
      - low parity
      - mild cases
      - one tube is present
- ovary
  - Conserve
    - ↳ Hormone production

no
- milking
- fimbriectomy

Vesicular mole

1/1000 (1/500 جنوب شرق آسيا) < previous U/L, extremes of age

Benign tumor of trophoblast < trophoblastic prolif. + hydropic deg. of ch. villi + No formation of implantation villi

Normally

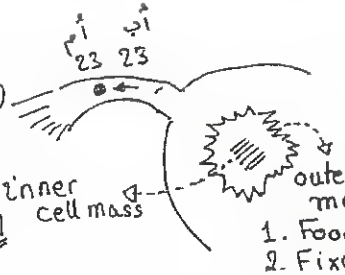

46 both ♀ + ♂ (23 ♀ + 23 ♂)

1. Food
2. Fixation
3. Funct. unit

Etiology

?! abnormality in fertilization — immun. – genetic – nutritional

→ 23 (يختفي) ..... → (ينقسم) → 46 xx (only paternal)

or

→ 23 (يختفي) → 46 xx

(Androgenesis)

Types

بطيخة + برتقالتين

complete — common — 46 xx

partial × — rare — 69 xxy

Patho-physiology

< no mat. chr. ..... no fetus
< only villi ---- 2mm–2cm

1] **Food** (جزيئات) — avascular villi, hydropic degener. — X no fetus ..... U/S (snowstorm)

زمان X-ray: (Honey comb) Y. (no fetal skel.) (chest X-ray مرة)

2] **Fixation** (تثبيت)

3] **Function** (زيادة) ... HCG ---- > من مئة ألف very high [الطبيعي 50,000]

Symptoms

1. Amenorrhea ⊕ excessive abd. enlargement ..... Fund level ↑ > طبيعي { no < fetal parts, FHS (doughy) مجرد عجينة
2. Bleeding (± vesicles) ..... passage of vesicles is diagnostic
3. Pain ↓
   - Dull aching (stretch)
   - colicky (expulsion) ..... Bilat. theca lutein cysts
   - sharp (perforation)
   - * acute abd if < torsion, rupture

Signs

+ general comp.

Complications

أخطر حاجة يقلب choriocarcin. — 5–10% — rare

General

Due to ↑ HCG
1- PIH < 20 wk
2- H.G.
3- thyrotoxic.

Due to ↑ IUPr.
1- invasive mole (chorio-adenoma destruens)
2- metastasing mole (pulmonary embolism)

Local

- Hge & inf.
- Reccurence 1-2%
- Perforation

ttt

1] Young

Suction evacuation (شفط)

followed by < curretage (to ensure completeness) / ecbolics (to ↓ hge)

No... hysterotomy < weak scar / disseminate vesicles

2] Old > 40

- Hysterectomy in toto
- As risk of choriocr ↑ to 35%
- Theca lutein cysts are not removed surgically ---- they will disapear spont. after 2-3 months (why?)

3] Follow up by B-HCG

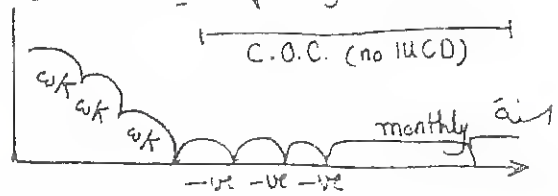

B-HCG < irreg. bleeding, evidence of metastasis — Methotrexate

Choriocr.

1. Pathophysiology

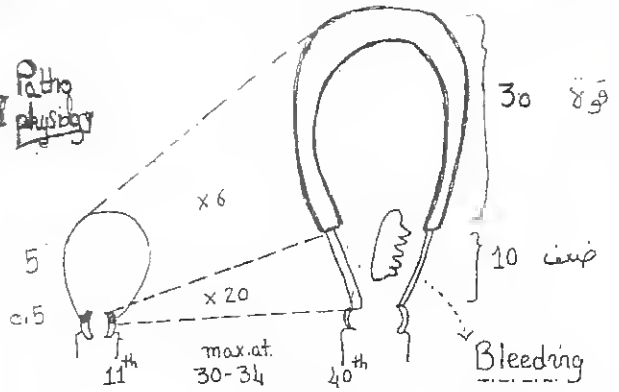

Stretch
- gradual → reccurrent
- Physiolog. → causeless
- LUS → painless
- near ! vag. → fresh bl.

} الشكوى

1. Pathophysiology

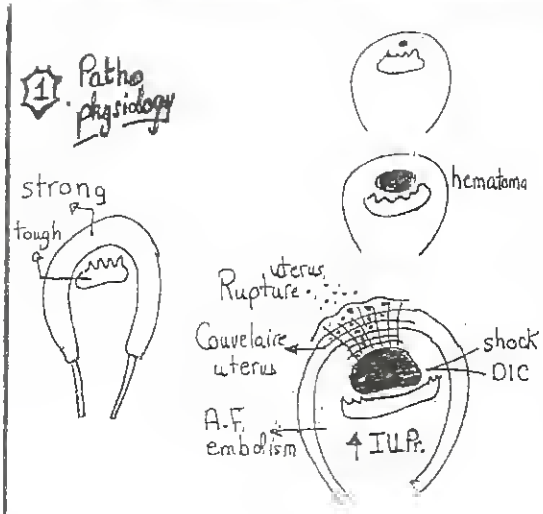

الشكوى
P.E.T. 1
⇓
acc. hge
⇓
D.IC 3
الثلاثية المشهورة

2. Etiology

إيه اللي خلاني أحط عليه فالجيم ؟ وما حصش فتح ؟

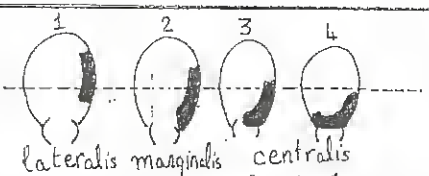

lateralis, marginalis — minor 90%
centralis — major 10%

3. C/P

- G: anemia
- A: palpation, auscultation عايش
  - F.L. ..... عادي
  - F.G. } soft
  - U.G. }
  - P.G. ..... عالي
- L: مجموع قاعدة

4. Inv.

- U/S → detect exact site
- FWB
  - U/S
  - Doppler
  - CTG, BPP
  - } تقصي steroids
  - } تكتشف amniocentesis

5. Comp.

M
- Preg. .... PTL
- Parturition
  - 1st ..... prolonged, PROM
  - 2nd .... malpresent → obst.
  - 3rd ..... PPhge
    - atonic
    - Retained "accreta"
    - traumatic
- Puerperium 3 S ..... sepsis
  - subinvolution
  - secondary PPhge

حروف ال P.

F → C.F.M.F, IUGR, PTL, IUFD

6. ttt

- Conserv. غالباً
- TOP

المرضى	mild bl.
الأم	not in labor
الجنين	no distress

لو إتغيرت

✓✓ A Anti-shock

B Delivery
- V.D. — mild bleeding, minor degree
  - 1st ..... cont. monitor – M & F
  - 2nd ..... prolonged, obst.
  - 3rd ..... guard against PPhge
- C.S. غالباً — severe bleeding, major degree
  - not fit / failed induction
  - F/M distress
  - Associated obst. indic.

C Care of ... mother, neoborn

2. Etiology

إيه اللي خلاني أشوف حاجة ؟ vessel يقرقع ؟

PET. 50%

concealed 10% — revealed, mixed ✓ — 90%

3. C/P

- G: shock
- A: palpation, auscult. تعجان ← ميت
  - F.L. ..... عالي
  - F.G. } rigid
  - U.G. }
  - P.G. ..... عادي
- L: مجموع قاعدة — إلا بعد

4. Inv.

- U/S → to exclude p. previa
- proteinuria (PET), FDPs (DIC)

5. Comp.

once occured → automatic ext. → شاكل severe

M
- Hematoma
  - Shock ..... APhge
  - DIC — PPhge
    - atonic
    - traumat
    - DIC
- ↑ IUPr
  - Couvelaire & rupture
  - A.F. emb.

F → IUGR, PTL, IUFD

6. ttt

- Conserv. ✗
- TOP غالباً ✓

المرضى	severe bl.
الأم	in labor
الجنين	distressed

A Antishock

B Delivery
- V.D. إحتمال — كلمة الـ AROM — ..... ↑ IUPR + well engaged head = easy delivery
- C.S. ..... if F/M distress — الواقع ✓ — بس لازم تطلع الـ DIC

C Care of ... mother, neoborn (PET, DIC)

©Obstetrics & Dr. Mohamed Abdel Wahab

Bleeding stops by:-

1) Contraction
   - intact ms
   - complete sep. of placenta
2) Coagulation

Types:-

- 1ry (within 24hrs)
  - Atonic ✓
  - traum. (extrapl.)
  - Retained (3rd st. hge)
  - DIC (coag. failure)
  - acute inversion ×
- 2ry (>day ... perip)
  - ! commonest
  - ! most serious
  - 3S: Sepsis, subinv., submucous polyp
  - others: local, general

Bleeding is known by

* shock
* > 500 cc.
* ↓ Hct > 10%

1ry PPhge

if placenta not delivered ½ hr.
⇓
1 Retained pl. (3rd stage hge)

History of etiology

Phys. — failure of
1. separation ... Ret. adherent < simple (atony) / morbid (nutabuch مفتوح) — types of: accreta, increta, percreta
2. Descent .... Ret. separated < atonic, rupture, cont. ring, full bladder — complete, partial (أجزاء), not

Diagnosis

clinically: shock ⊕

fundal level above umb.
⊕ signs of pl. separation (علامات الانفصال) .... descent

ttt < good anticipation, proper manag. of labor; anti-shock (إكمال)

1. Active manag. of 3rd stage [Brandt Andrews]
2. Manual separation under anesth.
   - const. ring
   - rupture ut.
   - simple adherence
3. Supra-vag. hyst ⇒ morbid. adh.

---

if placenta is delivered
⇓
True PPhge esp.
2 Atonic (90%)

*[Preg.] (رحم تعبان)
- 2 dis. <
- 2 hge <
- overdistended ut. <
- tocolytics لفترة طويلة

*[labor] (رحم مجهد)
- 1st: ..... prolonged ....
- 2nd: ..... over ....
- ..... excessive ....
- ⊕ full < B. R.
- ⊕ chorioamn.

*[uterus] (رحم مشوه)
- fibroid
- cong. malf.
- G.MP

lax, soft, large
F.L ⇑ — full of blood

- massage + ecbolics
- EUA < exclude .... / evacuate ....
- Bimanual comp.
- Laparotomy < conserv. (intramyom. PG ⊕ ut. & I.T.A lig) / supravag. hyst.

إيه الجديد: - B lynch - B alloon - B ilat. emb

---

if not atonic
⇓
EUA (fundo-perineal)
3 traumatic

- Rupture ut.
- cx tears
- perineal tears
- vaginal tears
- genital hematomas: vulval, para vaginal, Broad ligam.

Types
- more in MG?
- Complete
- incompl.
- P
- P
- P
- unilat. / bilat. / stellate
- 1) skin
- 2) ms
- 3) sphincter
- 4) rectum

etiology
- Preg. < spont. .... scar (مع باقي الجنين) / trauma ... ECV
- labor < spont. ..... obst. ✓ / trauma ... forceps
- Power كبيرة
- Passenger كبير
- Passage ضيق cx dystocia
- overstretch
- rapid stretch
- rigid / soft
- iatrogenic

comp. shock
- if hyst. .... infertile
- if repair ... rupture في الحمل الجاي
- injury ... ureter
- cx dyst. → Hge → inf. & fibrosis
- PIO & PT ← infert.
- Hge & rig ... 1
- Prolapse 2
- incontin. 3
- fistula 4

Scar (silent)
- impending: mild < pain, spotting
- Frank rupture

G A J — obst. — T. — -ve — left

- cx. tears:
  - 4 ring forceps
  - Sim's retractor
  - Auvard self retaining retract.

.... **Rupture:** SUH (طبعا) — هو الأساس
∴ prophylaxis
- Scar
- obst.
- forceps
- GMP

... **Perineal:** Past. op (صعوبة)
* interrupted sutures
* vicryl > chromic
* from above down
* Avoid rectal mucosa (inverted Lambert)

---

4 acute inversion

Spont. ×
- p.p.t. labor
- + short cord

iatrogenic (3rd st. عنف)
- Crede's method
- manual separation
- cord traction

1 2 3

- shock < hypovolemic / neurogenic ✓
- PPhge may be min. if < Placenta attached / Kinked Vs.

- G.E.A → repositioning 1st
- Then manual sep. of placenta
- followed by < packing / ecbolics

---

5 DIC

is diagnosed by suspicion < etiology / paradox

- لفترة < PET / acc. hge / A.F. emb.
- أجزاء < missed ab. / septic + induction of ab.
- ut. < incompat. bl. / excess bl. dextran

! most common → PET
! most rapid → A.F. emb.
! chronic is → missed ab.
occurs in any → prolonged < hypoxia / infection / injury

(كثرة الـ thrombopoietin)

- Paradox of < bleeding / thrombosis
- Bed side test (Weiner)
- Coagulation profile (تحاليل)

- ttt of ! cause ⇒ TCP < V.D. .... safer / C.S. ... faster
- Replacement therapy:- fresh blood, FFP, fibrinogen.
- No < heparin / antifibrinolytics

Types Of HTN

1. P. Ass. H. — الضغط موجود قبل و بعد الحمل — 1st or 2nd

2. P.I.H — 5-10% أشهر مرض في الحمل — 20 wks } failure of 2nd wave of inv.

3. P. Agg. H. (= 1+2) — = super-imposed PET

Def. Of P.E.T.

• PET	اسم غلط
• E Ph gestosis	- edema مش مهم - ممكن يبقى HTN Pturia = gestational (Mirror ?)
• PIH (in 1 2nd ½)	ممكن في الـ 1st ½
• usually in a PG	ممكن في MG

Etiology

theories

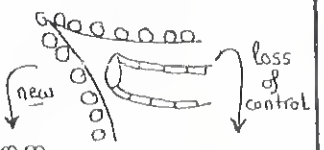

imm.
Ag-Ab reaction
(genetic predisposed)
علشان كده غالباً PG

1. PG
↓ PGE_2, nitric
↑ $PGF_{2\alpha}$, fibronectin

2. Renin-Ang. sensitivity

Pdf

large Ag. amount
• Twin
• H. Fet.
• Polyhyd.
• V. male
+ APS

Pt ccc
PG
abese
+ve FH
<20 >35

dis. affecting vessel
• D.M.
• SLE
• Kid.

old theories

* ANF... a result
* ut. dist. .... pr. on renal vessels
* الأكل
* الدم

Pathology

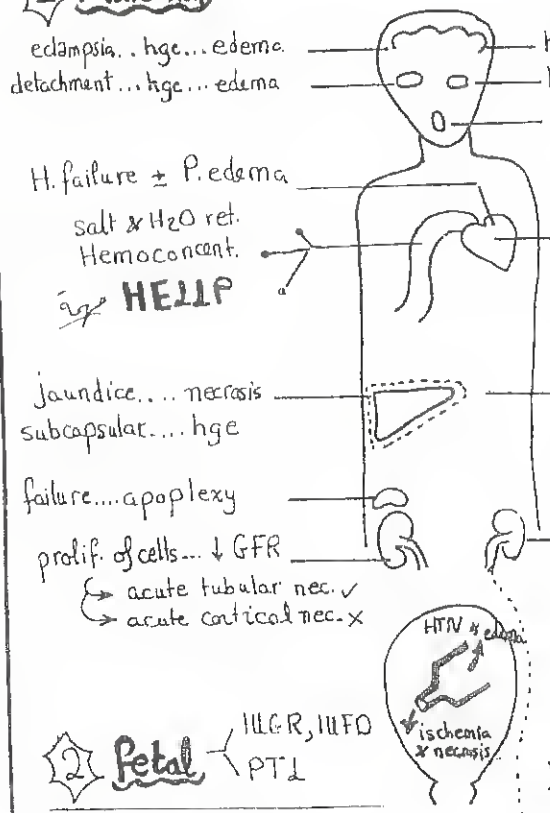

Comp.

1 Maternal

- eclampsia.. hge... edema
- detachment... hge... edema
- H. failure ± P. edema
- salt & H_2O ret. Hemoconcent. — HELLP
- jaundice.... necrosis, subcapsular.... hge
- failure.... apoplexy
- prolif. of cells... ↓ GFR
  - → acute tubular nec. ✓
  - → acute cortical nec. ✗

2 Fetal — IUGR, IUFD, PTL

C/P

1 Sympt

- headache, blurring, N&V } neurolog. sympt.
- sympt of comp.
  - HT failure
  - Pulm. edema
- epigastric pain (stretch of Glisson caps.)
- Oliguria <400, anuria <100

2 Signs

- Pturia (non-selective)
  - loss of -ve repulsion
  - sig. → if >300 mg/L
- edema ← HTN, ↓ ptn., cap. damage
  - occult
  - manifest
  - dry ✗ أنواع
- HTN
  - >140/90
  - >30/15

* false pturia كلوت
  - → MSU (clean catch technique)
  - → catheter ✗
* inf.
* orthostatic مع الوقفة

Bilat : unilat
* Phys. | * DVT
* Anasarca | * VV
* endoc. | * lymphedema

Inv.

- fundus
- CBC, coag. profile } HELLP
- liver funct.
- Kid. funct. (1st → ↑ uric acid)
- FGB
  - CTG
  - BPP

Screening (early detection)

- Doppler ✓
- Roll over
- Cold imersion
- ⇧ fibronectin (plasma)
- ⇩ Ca^{++} (urine)

ttt

Prophylaxis

- ANC esp. for those (pdf)
- Aspirin 75mg



Mild

- mature : TOP
- immature : conserv. ± steroids

Severe

1. sympt.
2. signs < Htn, pturia
3. Comp. < clinical, biochem.

or → fulminating + hypereflexia

or → eclampsia + fits

⇩

1. TOP ∴ V.D. C.S.
2. anti-fits ($MgSO_4$)
3. anti-HTN

PET

Etiology

1. **PET** :-
   - endoth.: ↑ vasoconstrictor, PGE2, Prostacyclin, nitric ox. ; ↑ F2α, TXA2, endothelin
   - ms: Renin ang. → vasc. perm. ; haemostasis
2. **Gest. HTN** — PIH — Htn in 2nd ½ without pturia
3. **Chr. HTN**

Pathophys.

حزينة للبيبي

أنا عايز ☺

* إزاي ؟ — invasion of media of spiral vs

* إمتى ؟ — second half

* ليه ؟ ☺

* فين ؟ — PET > 20 wks, d.t. loss of such mech: acute atherosis of vs / chr.: plac. infarcts

* بالتالي — Pt. acc. → PG, obese, extreme of age, +ve F. history

Post hist. — DM, renal

C/P

Sympt

- neurolog. sympt.: headache, blurring, N&V
- sympt. of comp.
- epig. pain
- oliguria

Signs // موجودة قبل الأعراض

1] **HTN** (A.N.C.) > 140/90, > 30/15

2] **Pturia** → late sign > 300 mg/L (+1)
- تقاس ؟ — urine strips (+ve), 24 urine
- exclude — false pturia, UTI, orthostatic

3] **L.L edema** → مش مهمة
- occult / manifest
- تقاس ب — foot, tibia, vulva, abd. (peau d'orange), puffy lids, papilledema
- exclude — phys., genital, unilat.

Pathology

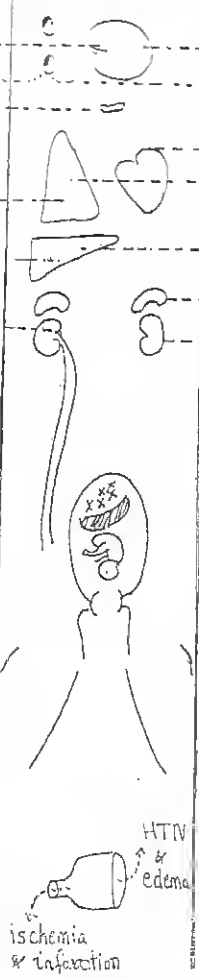

Comp

- hge, eclampsia
- edema, detachment
- H.F., atrophy
- Pul. edema
- failure, rupture
- Addison
- Renal necrosis — tubular, cortical
- Acc. hge → DIC → H.EL.LP synd.
- IUGR
- PTL
- IUFD

later on → recurrence / persistence

Inv.

1] **Comp.**
- fundus
- ↓ FTs
- RFTs (uric acid) — أول حاجة بتتأثر
- CBC ... ↑Hct, Hb%
- Coag. profile: PT, PTT, fib.

2] **Etiology** = screening
- Doppler
- CTG (non-stress)
- BPP
- U/S

3] **Diagnosis**
- albuminuria

Types

Mild

Severe
- * sympt. (pathology)
- * Signs: BP 160/110, alb. ++ > 5gm
- * comp.: M. F.
- * inv.: M. F.

Eclampsia
- Premonitory ½ m.
- Tonic ½ m.
- Dome ½-1 m
- Coma ... variable

ممكن تحصل: Ante 70%, Intra 20%, Post 10%

1] Pre-conceptional Care

Prophylaxis
- early detection by regular ANC
- Aspocid 75 mg for high risk

PGF2α ⇩ — irreversible ⊖ (anuclear) → reversible inhibition (nuclear) → PGE2 ⇧

2] Conservation "Hospital"

mild PET ؟ فين *

إيه الهدف ؟ *

1. early detection of comp.
   - daily: العمل والضغط والإدراك
   - weekly: الأحذية والمعامل والوزن FUB
2. Control of HTN
   - bed rest
   - diet
   - sedative
   - antihypertensive
     - ✓ α-methyl dopa (250 mg 1×4) — doesn't stop progress, may ↓ fetal flow, if case is mild
     - with caution: β-blockers, Ca++-blockers

* لغاية إمتى ؟
- maturity (± steroids)
- Comp. لو حصلت إيه — severe: مناه قلب

3] TOP

إمتى ؟
1. mild (if mature)
2. Severe
3. Eclampsia

إزاي ؟
- induction of labor (AROM ± oxyt.)
- C.S. (only if ليه) — Done 2-4 later

Action
- sub-cortical depression
- diuretic
- MNJ

toxicity
- coma
- Ht ⊖
- Resp. ⊖
- يفرز منها
- Knee ⊖ reflexes

إطمئنان
- ↓ RR
- uop
- Knee

MgSO4 4-6 gm slowly then 1-2 gm/hr

fits → في ال eclamp room

HTN → **Antihypert.**
- ✓ hydralazine (direct V.D.)
- labetalol (α, β blocker)
- Nefidipine] dangerous
- * No diuretics except in H.F.

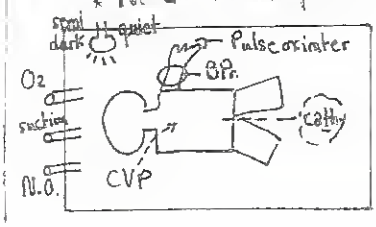

4] Post-partum Care

- Neoborn
- lactation
- contraception
- Continue MgSO4 24-48 hr
- الحمل اللي بعده ↓ Screening لأن نسبة الـ recurrence عالية

Diabetes Milletus

Etiology

1. GDM — 80%
2. IDDM — 10% — type I — juvenile — get pregnant
3. Non-IDDM — type II — Maturity — have got pregnant

Acc. to stage
- Potential
- Latent
- chemical
- established (overt)

Path ophys.

خدوة للبيبي

أنا عاز ☺

إزاي ؟ *
- anti-insulin hormones
- pl. insulinase

إمتى ؟ *
Second half (biphasic gluc. control)

ليه ؟ *

دة معناه *

Complication

On D.M.

1. Potentially diabetogenic
2. worsens — established D.M. / pre-existing comp.
3. Hypoglycemia may occur at:-
   - * Preg. — renal / alimentary / fetus starvation
   - * labor
   - * puerp.

On Preg.

1. Mother "P"
   - Preg — PET, Polyhyd., P. previa, pyelonephritis (25%)
   - Part. .... Prolonged, PROM
   - Puerp. .... P Phge, P. sepsis
2. Fetus
   - CFMF ↑3x Abortion
     - CVS, CNS
     - sacral agen.
     - hypoxia
     - hyperglyc.
   - IUGR (20%) ..... macrosomia (40%) ✓
   - PTL (yutopar? steroid?)
   - IUFD ..... esp. sudden
3. Neonate
   - ⇩ hypoxia, hypoglyc., hypocalc.
   - ⇧ RBC, bilirubin, viscosity
   - ⇒ trauma, CFMF, PNMR, sh. dystocia

Inv.

1. Etiology = screening
   - Not in urine?
   - 1 hr. gl. [glucola]
     - Booking (high risk)
     - 24-28 (all others)
     - obese, > 35 yrs
     - +ve fam. history
     - previous macr. baby
2. Diagnosis = confirmatory
   - if 1 hr > 140 ⇒ 3 hr. GTT

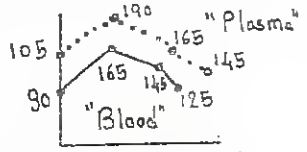

- DM ≥ 2 قراءة غلط
- IGT ≥ 1 قراءة غلط
- renal ..... +ve at peak in urine
- alimentary ... +ve at 1 hr.
3. Comp.
4. Previous control — HB A_{1c} / fructosamine = CFMF

Classification

* Recent clinical
* Priscilla White

1. GDM
   - A_1 < 105 (low risk)
   - A_2 > 105 (high risk)
2. IDDM without EOD
   - B > 20 < 10
   - C 10-20
   - D < 10 > 20 ± BDR
   - (stable, not stable)
3. IDDM with EOD
   - F
   - R
   - H
   - T

1 Pre-conceptional Care

- No oral hypoglycemic
- No preg. if comp.
- CFMF → HB A_{1c} > 12% [normal] = 5-8%

2 Conservation "ANC"

- تحليل بول *
- تحليل أدرار *
- البروتين بول *

2 wks (3 in GDM) till 32 then weekly

1. Early detection of comp.
   - clinically .... السكر والحمل
   - investig. ..... routine السكر

	GDM	IDDM
(US) شكله	38	18-20 .... serially
(FWB) صحته	34	32 .... يكون سبب الحالة

2. Control of D.M.
   - Diet ± exercise (A_1)
   - insulin (الباقي)
     - 7 am: 2/3 — 1/3 R, 2/3 NPH
     - 5 pm: 1/3 — 1/2 R, 1/2 NPH
     - short + intermediate
     - 0.6 ..... 0.7 ..... 0.8
     - check up: 3 hrs بعد الوجبة الفاطرة — 2 hrs بعد الوجبة الغداء

علشان أحياناً هاتيجي *
- 4 C → Hospit. — control, calculation, complications, confinement

لو ظهرت المشاكل دي : TOP

3 TOP

* القاتلة
  - not allowed to pass dates
  - previous unexplained sudden IUFD قبلها بـ 1-2 أسبوع
* GDM — A_1 → 40 wk.
* الباقي
  - controlled ..... 38 wk.
  - not controlled ..... 37 wk. (or as soon as mat. is documented)
  - comp. F. M. < 37 wk. في أي وقت

إمتى ؟

إزاي ؟
- C.S.
  - macrosomia > 4 kg
  - previous unexp. IUFD
  - غير كده ممكن V.D.

الولادة
- قبلها .... no insulin
- أثناءها ... 5x5x5x5
- بعدها .... no insulin
  - يتعمل سكر ٤ مرات
  - ويعطى إنسولين حسب التحليل
  - 5 units SC / 50 mg%
  - فوق الـ ..؟
  - لغاية ما السكر يرجع عادي

4 Post-Conc Care

- Neo born → expert neonatologist عنده مشاكل كتير
- Lactation كويسة ومفيدة
- Contraception
  - COC ×
  - IUCD ×
- prognosis
  - reccurence 2/3 في الحمل الجاي
  - later on 50% type II D.M.

Heart disease

Etiology

1. RHD 93%
   → MAT esp. MS
2. CHD
   → more in developed countries
3. IHD
   → rare

Pathophysiology

- Neck v.
- edema
- Rt. hypoch. pain

signs of SVC

- puls.
- water hammer p.

signs of hyperd. circ.

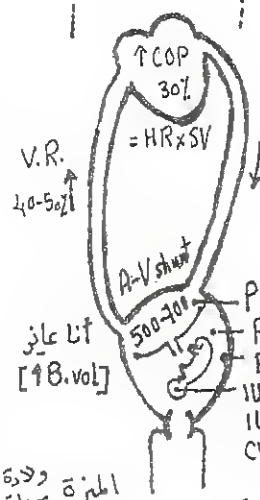

C/P

Personal history
- Age
- Address, occupation
- Habit

• HPI

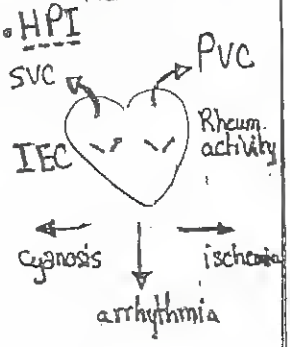

• Obst H.
previous HF in preg.

• Past H.
- medical: Rh.F.
- surgical: valve repl.
- drugs: anti-failure, anti-coag.

Comp

On heart
Deterioration 1 degree up to heart failure
esp. at 1. Preg. 2. labor 3. rd st.

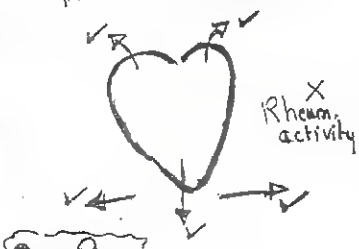

On Preg.

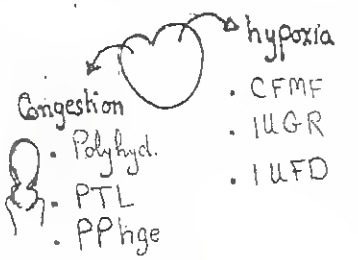

Inv

- X-ray ??
- ECG
- Echo
- Rh. fever (ASO titre)

Classific.

functional capacity (dyspnea)
- Class I → No
- Class II < mild, mod.
- Class III → seven
- Class IV → rest

[NYHA]

---

1. Pre-Conceptional control

* No Preg. if:
- Class III, IV
- Eisenmenger
- Severe AS or P^{++}
- History of H.F.: 2 yr. [Rh. activity, IEC]

2. Conservation "ANC"

- مع مين
- كل أد إيه
- الرد إيه

1-2 wks till 32. then wkly

① early det. of comp. e.g chest inf.
② Control of HD → digitalis, pen.

لازاي؟ (مفيش داعي) → C.S. → severe < AS, P^{++}; Eisenmenger; Marfan

علشان أحياناً هاضطر → TOP (only in 1st trim.) / 30-34 Hospit.

3. TOP

1st stage: V.D. / O_2, No, No, epid

2nd: easy ± Forceps

3rd: avoid methergine ± Lasix

4. Post-partum Care

- Neonate
- Lactation
- Contracept
- اللي معدة → reccurence

Valve replacement عمره

1. Mix.



2. Heparin على طول → adv.: doesn't cross placenta; short acting (2-4 hrs); have antidote (protamine sulphate) ..... disadv.: bl. tendency; thrombocytopenia; osteoporosis
3. OAC على طول → less risk of bl.; reversible by vit K, FFP ..... disadv.: pass placenta

Heart disease

N.Y.H.A. I, II / III, IV

- Rheumatic 93%
- Cong. 7%
- others

History

* Personal
  - age < صغيرة: cyanotic / كبيرة: ischemic
  - residence → damp non-sunny
  - smoking
* C/O: → she is well known to have MVR & is referred for control
* HPP

المعلومات	مشاكله	المرض نفسه
1. للمرض E.C.G, echo 2. للمشاكل G. / L. سونار - تسمع - دوبلر	1. General 2. Local بيلعب ... عيل تزهق ... مشية كبرت ... ميه فقص ... رحم	1] إزاي إكتشفتاه؟ - هي عارفة - من أعراضه 2] من إمتى؟ 3] إيه العلاج إتغيرت؟ - الأدوية - الجرعات

take care: common sympt. < dyspnea, palpit. / LL edema / malar flush

* Menst.
* Obst..... PTL, easy vag. delivery
* Contr..... no IUCD ?! ... no COC ?!
* Past..... medical (Rh. fever), surgery, drugs

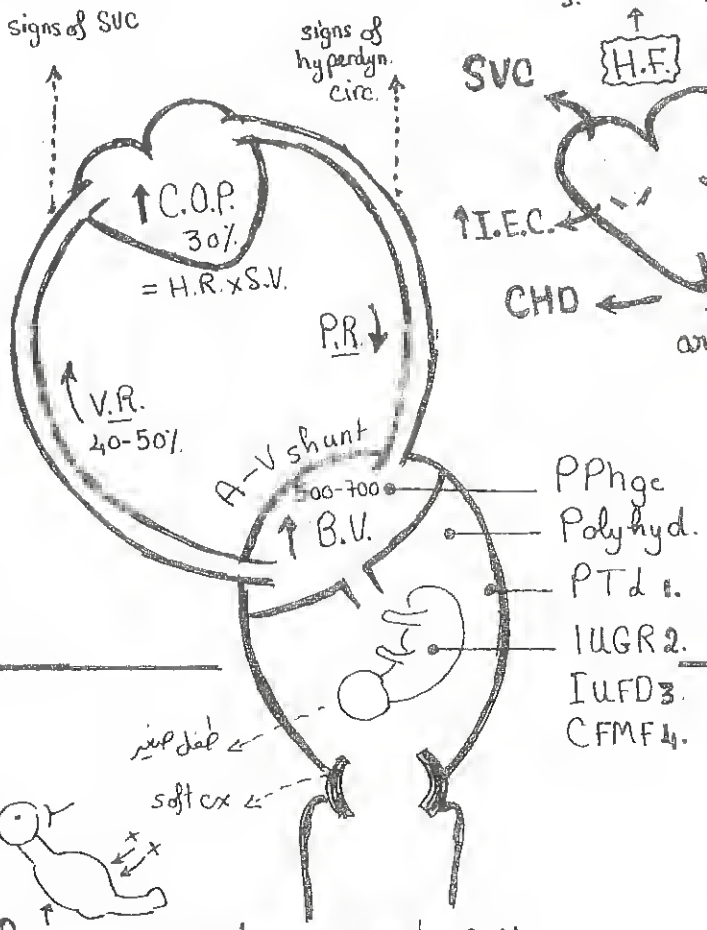

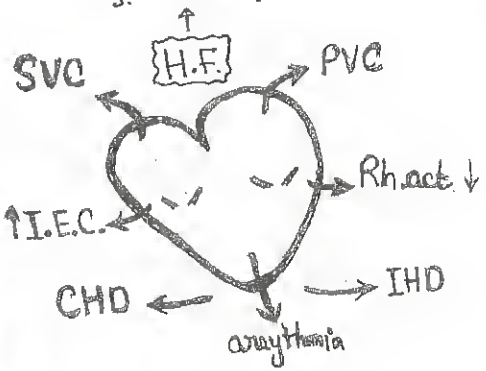

Examination

- General
  - Pallor, cyanosis
  - Don't forget < back / LL edema
  - Heart

peripheral	central
- SVC 1) N. veins 2) enlarged liver 3) LL edema	- splitting 1st sound - 3rd sound - soft syst. murmur < 2/6
- Hyperd. circ.	

- Abd. IUGR ± polyhyd.
- P.V. ما بلاش أحسى!

management

1. Preconceptional
   - Class III, IV
   - severe AS, P+
   - Eisenmenger
   - History
     - H.F.
     - IEC
2. ANC — Rest, diet, hospit
3. TOP

Therap. TOP is only allowed 1st trim.

After that TOP is more hazardous than continuing preg. ∴ Cardiac pts are left for spont. onset

V.D. — ولادة

C.S.
- A.S.
- P++
- Eisenmenger
- Marfan

Diagnosis

full ✓✓

Name, 32 years, P_{1+2}, 34 wks, cephalic, not in labor, IUGR, RHD, MVR, on heparin, compensated (acc. to NYHA) < I, II / III, IV

Valve replacement

Heparin → الميزة: easy control < short ½ life, has antidote / العيب: bleeding

OAC → الميزة: less bleeding / العيب: passes placenta

الحكاية

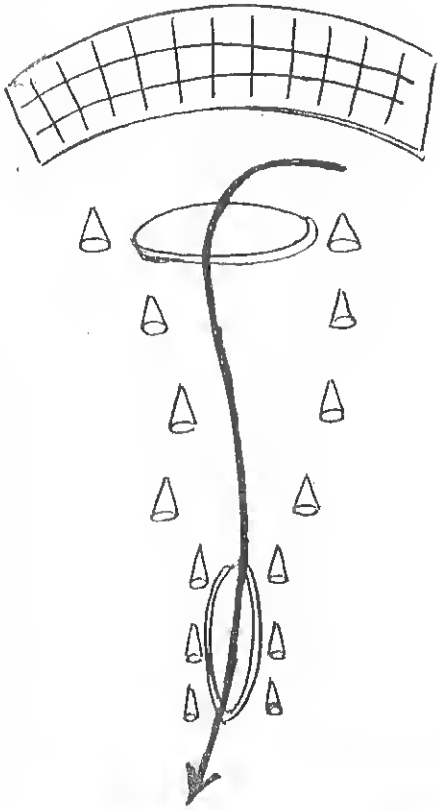

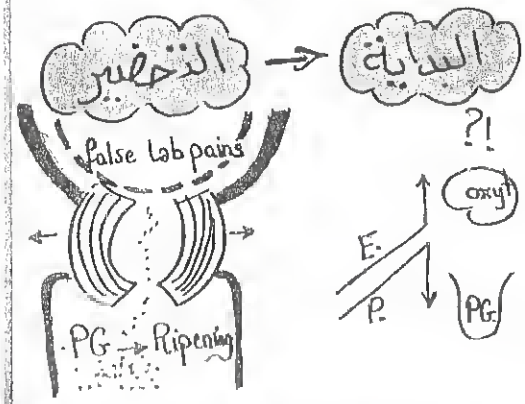

المقاسات

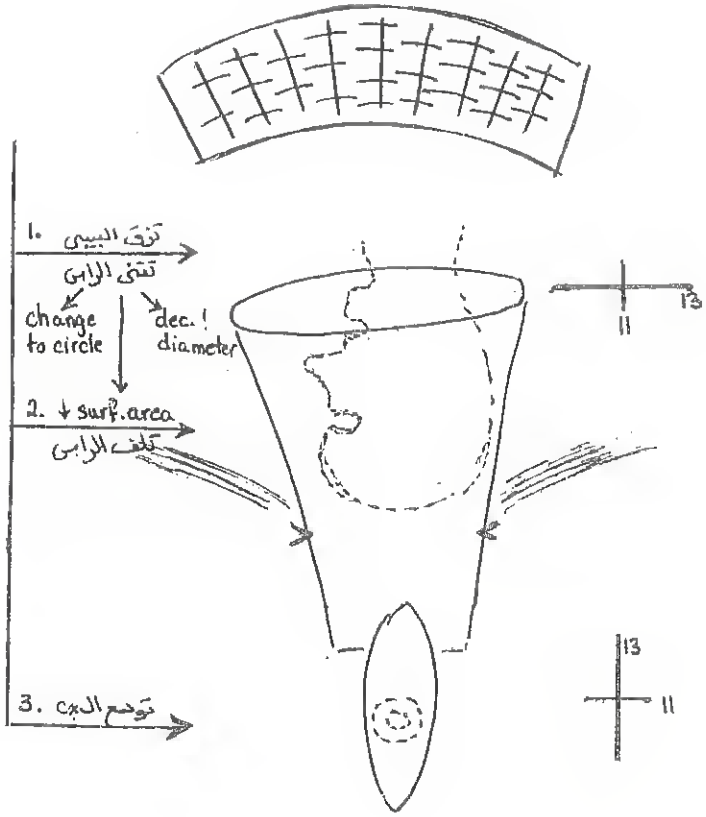

Diameters

- الرأس
  - ?! 9.5 × 9.5 لازم
  - بالطول
  - بالعرض
- الحوض 11,12,13

	AP	oblique	Tr.
inlet	11		13
cavity		12	
outlet	13		11

القوانين

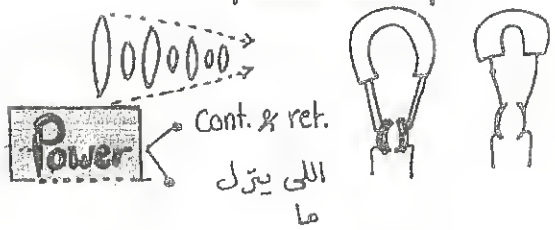

Inlet = engagement
- أدخل بالعرض
- الطويل ف الطويل
- و ال ف ال

Cavity → يلف
- ?! بسبب 1.

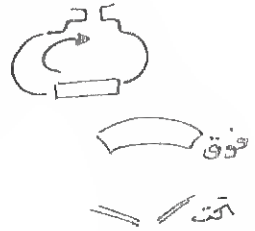

2. lev. ani قانون ال
- لكل فعل رد فعل ...
- كلما قلت ال .....
- كلما زادت قوة ال ...
- كلما زادت درجة ال ...

* تخطى خبطة جامدة ←
* تخطى ½ ½ ←
* ماتخطيش خالص ←
* تخطى بالعكس ←

Outlet = crowning
- أطلع بالطول
- أدور على مفصلة

} Accomodation

التعريفات

Passenger

1. Lie



long 99.5%
Tr. 0.5%
obl. rare

"a matter of accomodation"

2. Attitude

generalized flexion
why ?!

3. Presentation

96% Cephalic
Breech 3.5%
Tr. 0.5%

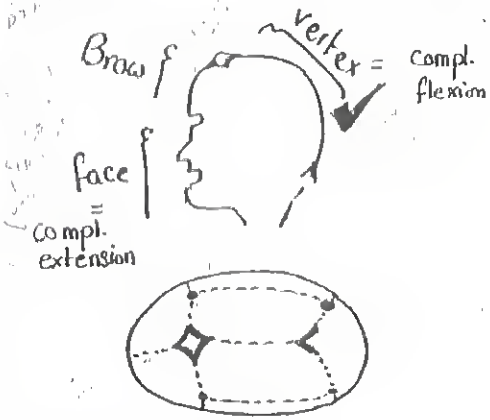

4. Denominator

[presenting part] جزء [علامة] بروز

Presentation	Denominator
Vertex	Occiput
Face	Mentum (chin)
Brow	Frontal bone
Breech	Sacrum
Shoulder	Acromion

Passage

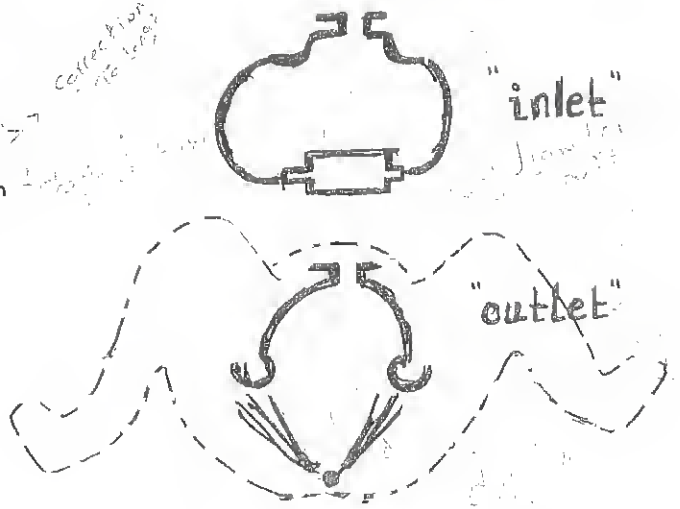

5. Position

= relation ship bet. denom. & inlet

= 8 positions e.g.

Ceph.

breech

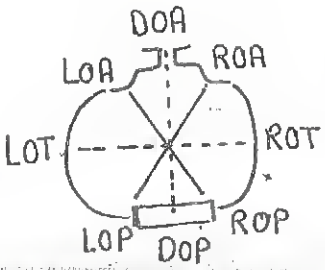

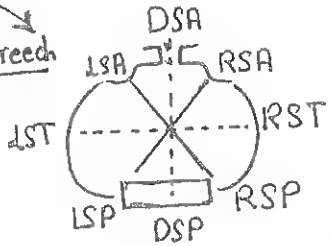

Power

A Main = uterus

cont. & retr.
C.P.R. i.e
Coordin. + ++ ++ + −
rhythmic
involuntary
effective
1st cx dil
2nd fetal desc.
3rd pl separat.
4. prevents PPhge
5. helps involution

100%

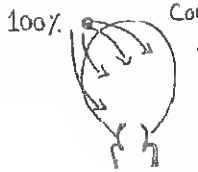

أعراض
"تحدد بداية الولادة"
= true lab. pain

prog. ⇧ ← frequency 3-5/10 m
duration 40-60 sec.
amplitude 40-60 mmhg

B Auxillary = bearing down

- voluntary جزئيا
- involuntary: d.t. pressure of fetus on pelvic floor (lev. ani)

Diameters

Head ← → Pelvis

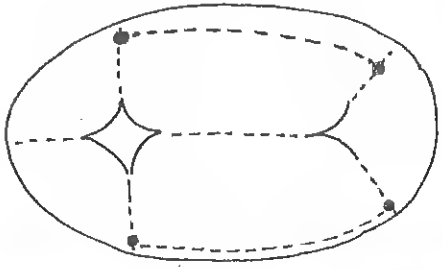

	A.P.	Oblique	Tr.
Inlet	11 (10.5)		13
Cavity		12 (12.5)	
Outlet	13		11 (10.5)

Transverse

Biparietal 9.5
Bitemporal 8.5
Bimastoid 7.5

9.5cm: Synclism: 25%

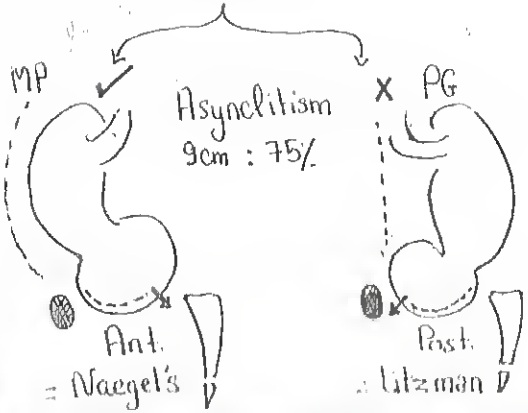

Longitudinal

1.	O.A.	fully flexed	Sub.....	bregmatic	9.5
2.		not	" "	frontal	10
3.		O.P.	" "		11.5
A.	Face	fully extended	Sub.....	bregmatic	9.5
B.		not	" "	vertical	11.5
C.		Brow	" "		13.5

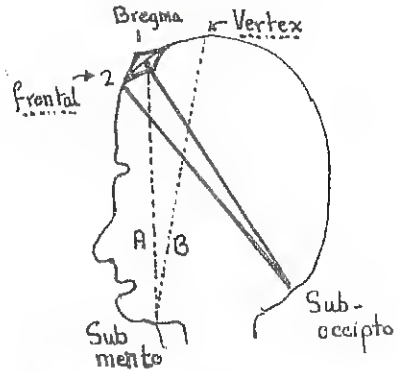

Inlet

- A.P. (conjugate)
- Tr.
- Oblique

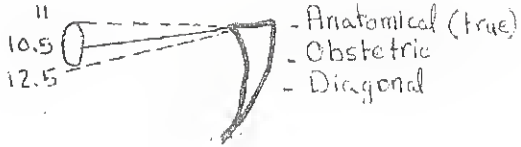

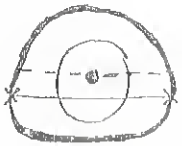

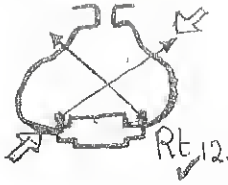

Cavity

12.5 x 12.5

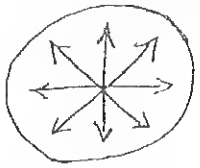

Plane of greatest pelvic dimension

Outlet

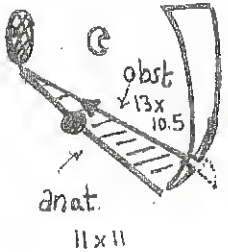

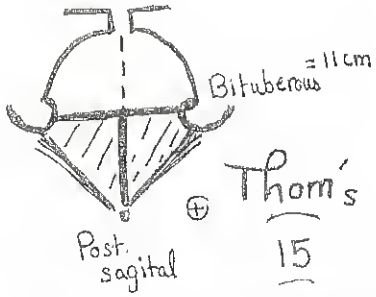

⊕ Thom's 15

Def.

- 2 M < spont. / natural passage
- 3 Dr. < reasonable time / no interference / no comp < M, F
- 4 F. < Single / Alive / Ceph. (vertex : OA) / Mature ≥ 37 (38)

Theories

الآن — زمان

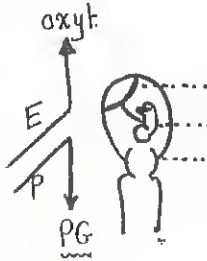

Diagnosis

- الأكيد: lightening, Shelfing } engag. — 36-37 PG, MG ولادة
- الإنتباه: true lab. pain — show
  - Progressive in fr., ampl., durat.
  - Fundal hardening
  - ↑ by enema & not ↓ by sedat.
- المخاض: cx. eff. & dil. — bulge of forth. (membranes); Ripening mat. occur pt

co-ordinated prog. — Rhythmic

C P R — Cont. — retr.

L. involuntary
e. effective

1] Lie
2] Attitude
3] Present. 1/300 — 3.5%
4] Position 1/2000 — 96%

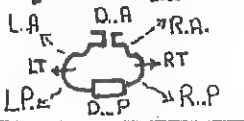

Power

- O.A { fully Sub.... bregm. 9.5 / not " " (front) → O.P ✗ " "
- Face { fully Sub.... bregm. 9.5 / not " " (vert.) → face ✗ " "

Asynclit. — 9 cm — Sub-suprapubic

Bi { parietal 9.5 / temporal 8.5 / mastoid 7.5

Passenger

Tr. — long.

	AP	Obliq	Tr.
. inlet	11 (10.5)	↑	13
. cavity		← 12 →	
. outlet	13	↓	11 (10.5)

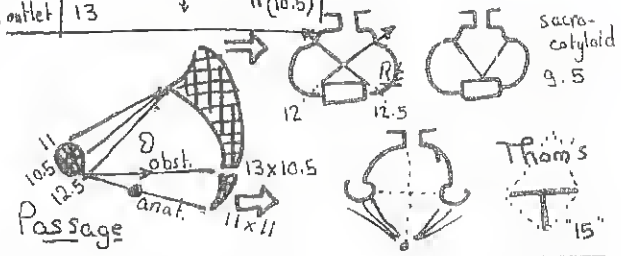

Passage

Normal mechanism

1st stage — PG 12-16, MG 6-8

2nd stage — PG 1-2, MG ½-1

3rd stage — PG 10-30, MG 5-15

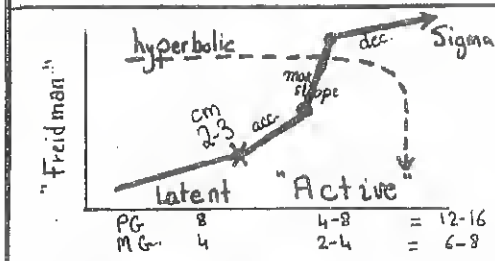

1. Descent
2. Engagement { sympt d/S — Abd. ⅕-⅗ / signs — vag. ---> isch. spine
3. ↑ed flexion → 5. Extension (D.O.H.)
4. Int. rotation (داخل بالعرض / طالع بالطول) → 6. Restitution (L.O.R.)
7. Ext. rotation → L.O.T.
8. Delivery of should. { ant. / Post

Cont. & ret. — 1. separation 2. descent

Types — Shultze 80% ✓ — Duncan 20% ✗

Management "conduction"

- المرضية: انتشى و امشى
- الممرضة: A sepsis, A nalgesia
- العاملة: B., R.
- الطبيب: observ. Inv.

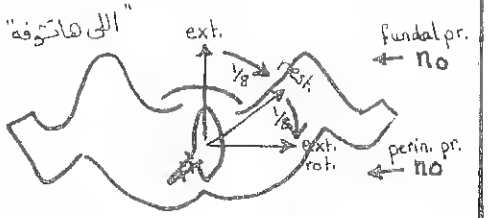

"Ritgen" Allow! head to gradually extend inbet ut. cont. only after crowning ± episiotomy

- Conserv..... wait 4 pl. sep. → encourage strain → ecbolic
- Active ✓ Ecbolics 1st & Massage then →
  - ✓ Brandt's Andrews — contr. cord traction
  - ✗ Crede's — Painful, inversion, prolapse

Active managem. ≤ 12 hrs

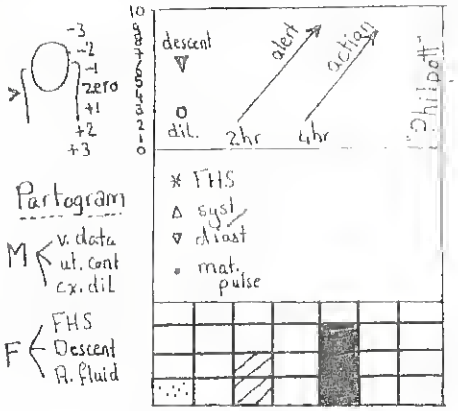

Partogram
- M < v. data / ut. cont / cx. dil
- F < FHS / Descent / A. fluid

→ Admit pts only in active phase
→ immediate ARAM 1 hr. → oxyt. Dehyd. G. < full bl. / sedati. / L. P

if • → Alert ..... Correct
if • → Action .... CS.

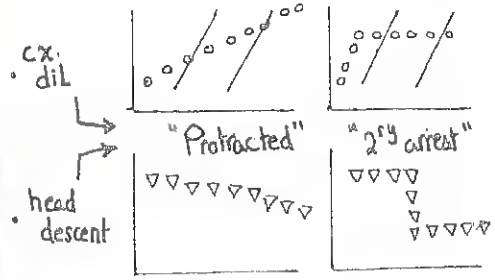

Malpresentations..... 7 x 7

1 Definition

- **Lie** ⇨ longitudinal → 99.5 %.....Transverse → 0.5 %
- **Attitude** ⇨ *General flexion*
- **Presentation** ⇨ *Cephalic (96 %)---Breech (3.5 %)---Shoulder (0.5 %)*
- **Denominator** ⇨ Relation between the denominator (a certain point on presenting part) to maternal pelvis

Presentation	Denominator
Vertex	Occiput
Face	Mentum (chin)
Brow	Frontal bone
Breech	Sacrum
Shoulder	Acromion

- **Position**

There are 8 main positions:

Left ant. '1'	Lt iliopectineal eminence	**Right post. '3'**	Rt sacroiliac joint
Direct ant.	Symphysis pubis	**Direct post.**	Sacral promontory
Right ant. '2'	Rt iliopectineal eminence	**Left post. '4'**	Lt sacroiliac joint
Right lateral	Mid of iliopectineal line	**Left lateral**	Mid iliopectineal line

2 Incidence

why OA, MA, SA

3 Etiology

	Passage	Passenger	Power
* General	1-Soft tissue obst. e.g. → pelvic tumors	1- Fetus → PT, twins, CFMF 2- Placenta → P. previa	1- Main → CMF of uterus e.g. septate
* Idiopathic (10-20%)	2- Bony obst. e.g. → contracted pelvis	3- Cord → short, around neck 4- A.F. → Poly or oligo	2- Auxiliary → pendulous abd (GMP)

* Special....

4 Clinical Picture

➥ **In pregnancy**

* *Inspection* - Normally the back is anterior
  - Fetal movements are hardly seen on both sides of midline
* *Palpation*
  - Fundal level → higher (d.t. to failure of engagement)
  - Fundal grip → .....
  - Umbilical grip → Limbs, back → felt easy or not ?
  - Pelvic grips → .....
* *Auscultation*- (normal = OA → midway between umbilicus & ASIS)
* *U/S* → confirms *diagnosis*, detects *etiology*, excludes *CFMF* (TOP)

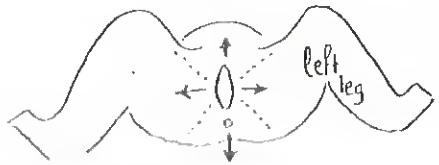

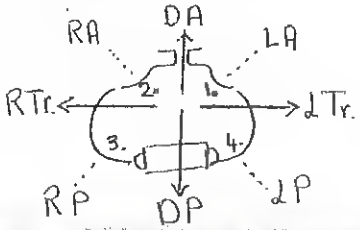

➥ **In labor (as in pregnancy + PV)**

* *Early* due to imperfect application on cx ⇨ slow dilatation of cx ⇨ large bag of forewater → PROM (cord prolapse ± infection)
* *Late* ⇨ **the exact *presenting* part, *denominator* is felt**

	Cavity	Bones	Diagnostic ccc
Face	Mouth	Chin + 2 maxilla	Alveolar margin + suckling
Breech	Anus	Coccyx + 2 ischial tuberosities	Meconium + abd. examin.
Shoulder	Axilla	Clavicle + acromion + humerus	Feel the ribs
Brow	Frontal bone, no chin, no posterior fontanelle (by exclusion)		

- Take care from
  - ▸ Caput.....false impression of low station, masks the denominator
  - ▸ Meconium...fetal distress (normal in *breech, oligamnios, postdate*)

5 Mechanism

depends on
- Inlet (engagement) ⇨ Power.....improvement
- Cavity (rotation) ⇨ Passenger.....rotation
- Outlet (crowning) ⇨ Passage.....adequate

} if there is no CPD

6 Management

First stage ⇨ guard against

Inertia	PROM	Sepsis
- Evacuate bladder & rectum - Correct dehydration - Avoid excess sedation	- Avoid excess PV - Patient should lie in bed - Avoid strong enema	- Prophyl. antibiotic Avoid PROM Avoid excess PV

☞ **Observation is done by the partogram**

* *Analgesia*, *ARM*, ± *oxytocin* augmentation may be needed
* Indications for CS
  - **Fetal distress** (over-power or fetal stores are already depleted)
  - **CPD** (known by examination from start or by *partogram*)
    - ▸ Prolonged (protracted).....dilatation or descent
    - ▸ Secondary arrest of.....dilatation or descent

Second stage ⇨ delivery is allowed for 1–2 hr in PG (½-1 hr in MG)

Third stage ⇨ guard against PPHge & care of newborn

7 Complication

MATERNAL			FETAL
1st stage	2nd stage	3rd stage	
1- Prolonged labor → F & M distress 2- PRCM → cord prolapse + infection	Obstructed labor → instrumental delivery → trauma (rupture uterus)	- PPhge. - P. sepsis	1- Trauma 2- Infection 3- ICHge 4- Death

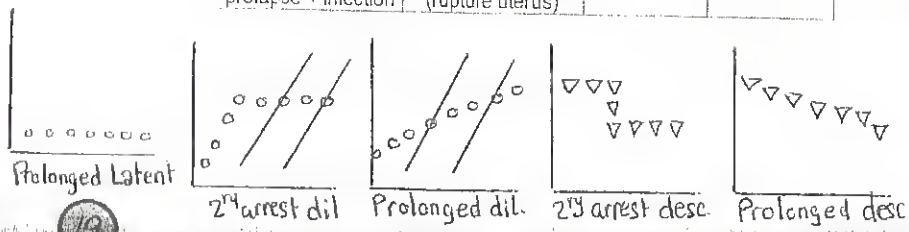

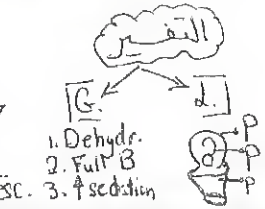

O.P. (20%) — face (1/300)

etiology

- 1ry (in preg.): fetal anomaly
- 2ry (in labor) ✓: after OP.

Mech

1. Descent
2. Engag.
3. Ted....
4. int. rot.
5. الكلى
6. Restitution
7. Ext. rotation
8. Deliv. of sh

vertex: 80% → O.A.; 20% → O.P. → 90% → Slight ← 40% ← M.P. ← 20%; M.A. ← 80% ← face

Slight → 3/8 → 1, 2, 3

C/P

* Preg ....
  1) FL
  2) FG
  3) UG
  4) PG
  FHS
  U/S
* Labor ....
  - early
    1) slow dil
    2) PROM
  - Late

Mild → DTA (1%) ← DTA; non: CS; engaged M. ^ F.

Mod → PMP (3%) ← POP; engaged M. F. V. → Rotation

Severe → DMP (6%) ← DOP → C.S. (18 cm)

C.S. ← non; CS. 50%; face 2 Pubis 50%

Mang

1st st.
- Partogr
- Guard against → inertia → PROM → ing.

2nd st.

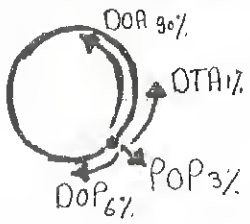

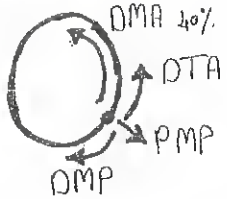

88%

V.D. 93%

C.S.
* Face to pubis in 50%
* POP / DTA if
  - not engaged
  - failed rotation

* All MP → ✓✓
* Wait for rotations ?!

Breech 3.5% — esp. PT = 35%

Complete / incomplete — Frank, Knee, Foot

why ! baby is cephalic
- → accomodation → failed (كبيرة → الرأس; صغير → الأرداف)
- → fetal mov. → interference
- → amniotic fluid → poly / oligo

Preg. → **E.C.V.** (ما تيجي تلفه أحسن)
1) ↓ ! diameter
2) Rotate in direction of limbs
→ Success 75% but may recur

labor

	Uncomplicated			Complicated
	1. Spont	2. Assisted	3. Extraction	
Buttocks	✓ (حوض) Bitroch. 10cm	✓	* Bring down a leg * Groin flexion	Power, Ter, Pyc
Shoulder	✓ (حوض) Biacromial 12cm	* Bring down an arm * Lovset maneuver		
Head	✓ (حوض) 11.5 cm Occipitofrontal	* Burns-Marshal × * Mauriceau-Smellie Vict (jaw flexion & shoulder traction)		
	القانون → for exit: diameter (كل ال) AP ← يعدل نفسه Hinge (ع	* Forceps (Piper's) * Kristeller's		حوض ضيق (Bone, cx) < Alive / Dead; راس كبيرة (extended أو لفوا)

Comp

High perinatal:
* Mortality
* Morbidity
⇓
C.S. ✓ esp
- PG
- A+B=C

V.D. / **C.S.**

	V.D.	C.S.
Parity	MG	PG
Previous br.	✓	
Type	Comp., frank	foot, Knee
Age	34-40	Preterm, Postterm
Weight	2-3.5	<2 >3.5
Head position	flexed	extended
Disp.	×	✓

U/S → e.g. Hydrocephalus, Cong. Anomalies

why < 34 wks, 2 Kg → C.S.

* Sliping of ! small sized fetus & arrest of ! head in ! incompletely dil. cx
* Rapid compression-decompression on head → ICHge (fragile cap.)

Abnormal uterine actions

Hyperfunction

= e' out obst Precipitate labor = e' obst. obstruct. labor

see later

Def. Rapid delivery in < 3-4 hrs.

Etiology
- Power — strong cont.
- Per — small fetus
- Pge — Roomy pelvis

غالباً =

C/P Diagnosed by rapid progression in Partogram.

Comp.
- M.: • PPhge < atonic, traum., acute inversion
- F.: 5F. < dist.?!, IChge?!
- • P.sepsis

Manag.
- Proph. early admission if +ve history
- Labor < 1st .... sedation (nit. oxide); 2nd .... episiotomy
- > lab exam. of both < M., F.

Hypofunction

Hypotonic uterine inertia

weak ineffective ut. cont. in all its charact. < freq., amp., duration

1ry — في بداية الولادة: رحم كثيف / رحم جيد → ضعف، تزيف، dist.

2ry — تعب بعد شوية → رحم أجهد في الولادة = abst./prolong. = CPD < fger, pge.

غالباً: • GMP • elderly • dyst. dyst.

- M.: • PPhge < atonic, retained pl.
- F.: 5F.
- • P.sepsis

- Proph. → Proper manag. of lab. / Proper detection of etiology
- Labor exclude CPD → Partog.
  - 1st .... ARM → oxyt.
  - 2nd .... wait for 1-2 hrs < not eng. → C.S.; eng → F., V.
  - 3rd .... massage, ecb. ..... manual sep. of pl.
- > lab. guard against PPhge

Cx dystocia

failure of cx. dil. inspite of good uterine cont.

1ry: funct. spasm — ولو في الكلام → Prolonged dil. → fetal distress → C. section.

2ry: fibrosis — may be felt as hard rim

Incoordinate

Cont. — ret.
C — P — R i.e. involuntary, affective
Coord — rhythmic

N. — ULS + / LLS − في جميع الحوامل — 3-5, 10 m, 40-60

Colicky uterus — abd. pain

Tonically cont. ut. — severe pain + fetal distress

Hypertonic LUS — lower abd. pain + backache

Prolonged lab. → PROM → slow dil. cx. → Comp < M., F.

ولو في الكلام

Contraction "constriction" Ring

جدول مقارنة Ret. ring

- improper use of ecbolics
- repeated / rough manipulations esp. under light anesth.
- CPD & malpresent.

1st st.	2nd st.	3rd st.
bet. ULS & LUS	around fet. neck	around placenta
Prolonged	obstructed	retained
• Sedatives (Pethidine) or nit. ox.	• G.E.A. (or amyl nitrite)	Anesth.
then • Proper man. by ecbolics	then forceps (if failed) → C.S.	then manual removal

hour glass

Types

(*) Normal

- 50% Gynecoid
- 20% Android 'funnel'
- 25% Anthropoid
- 5% Platypelloid (flat)

commonest type is ...

(*) Abnormal

contracted inlet

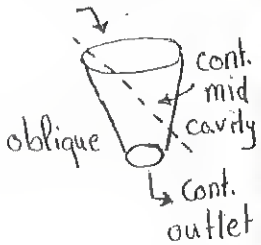

G. contracted

Etiology [factors affecting bone growth]

1. Cong. - familial, racial

- G. cont. pelvis < android, anthr., platyp.
- one alum. - Naegel's → oblique
- both ala - Robert's
- High / Low assim. → cont. outlet
- Otto / Split

2. Acquired < nutritional, mechan., hormonal, disease

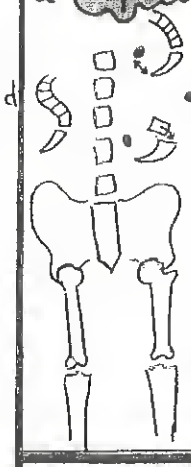

- Kyphosis → c. outlet
- Scoliosis → oblique
- Spondylo. → c. outlet
- Rickets → flat
- osteom. → triradiate
- fracture / amput. → oblique

Comp

F.	M
Labor	Preg.
1.	
2. 1st → non-eng.	1st → ant. sacc.
3.	
4. 2nd → abst.	2nd → UTI
5. 3rd → S3	3rd → Pend. abd.

Assesment

لو الوزن زاد على الـ sacrum

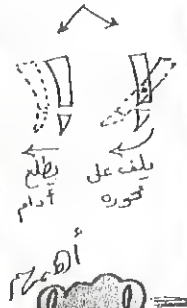

1. Local

2. General

- Appearance
- <150 - Height
- Gait
- Head
- Back

3. Abd.

- Pend. abd.
- Non-eng.

4. History of

CP* ⟶ CPD ✓

Anatomical

[↓ by ≥1cm]

- 1. Mild (10-9cm)...
- 2. Mod. (9-8cm)...
- 3. Severe (8-6cm)
- 4. Extreme (<6cm)

Obst.

[↓ to ! extent w' interfer w' labor]

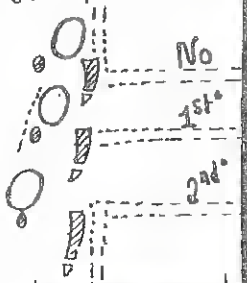

Pelvimetry

1. Clinical

External ✗

- Inlet
  - ext. conj 20
  - inter-spinous 25
  - inter-cristal 27.5
- Outlet
  - Bituberous 11
  - Thom's "15"

Pinard — دكتور واحد من فوق

Muller — فوق وتحت ٢ دكاترة

Internal ✓

- Subpubic angle ✓✓
- Ischial spines ✓✓
- Diagonal conj. 12.5

Kerr's — فوق وتحت دكتور واحد

2. Radiological

obsolete ×××

lat. view — واقف

Brim view — semi-sitting

Pubic arch view — قائمة و وطيئة

Special tests

Management

Def. is changed from CP → CPD
↳ large babies could be delivered from a larger pelvis والعكس صحيح

- Nothing
- Trial of labor
- C. section

why?
- Power → m.b. effective
- Per. → async., moulding
- Pge → pelvic give

power.... / per.. who? / pge.....
- PG, healthy, young
- vertex, OA., normal CTG
- 1st° CPD, no cont. outlet

How?
- 1st stage (partogram) < guard against < AROM, oxyt, analg
- 2nd stage < engaged: F., V. / non-eng: C.S

	Causes	Mech.
1. Generally cont. p.	- inlet: ↓ engag. - cavity: ↓ rotation - outlet: ↓ exit	C.S.
2. Cont. inlet (flat p.)	• Simple كلاب → C.S. • Rachetic inlet بس → assynel.	
3. C. outlet	- Andr., Anthr. - Kyph., spond. - High asym.	Thom's rule
4. Oblique	• Naegel's • Scoliosis - lower limb	in ! other oblique diam

Anteparturn FWB

(*) Symptom → Fet Kicks
- Cardiff count to 10
- Normal > 1 FK/hour (> 32 wK)
- abnormal → if > 10 hrs or double norm
- subjective (not suitable for HRP)

(*) Sign →
- General: ↑ weight
- Abd: progressive ⇧ in
  - FL = gravidogram
  - circumference = abd. girth

✓✓ (*) inv

a. Doppler واصله دم
- earliest detection before pathology e.g. PET, IUGR
- S/D ratio, resistence, pulsatility
- 1st → diastolic: ↓ ... stopped ... reversed
  finally → systolic: stops

b. U/S صاحي
- abd 1.5 Mhz
- vag. 7.5-15 صغر لكن أوضح



- site, grading (Cu++) 0, 1, 2, 3 ✓
- life, site, no, CFMF, biometry (BPD, TAD, TTD, FL, HL)
- turbidity, index $\frac{a}{b}$ (5-15)
- anomaly, fibroid
- dimensions (patulous os)

c. CTG وبيلعب
> 32 wks مهمة

FHR
- 160 ↑ tachy ← stress, fever, inf, drugs
- 120 ↓ brady — most dangerous
- B_2B كويسة ↓ صراع في الـ CNS
- frequency
- amplitude

العلاقة مع حركة الجنين
- Acceleration (NST)
  - -ve • reactive > 2/20 m.
  - +ve • non " < 2/40 m.

العلاقة مع حركة الرحم
- Deceleration (CST)
  - -ve .... no dec.
  - +ve ... dec. > 50%
  - suspicious ... dec. < 50%

✓ neuro حلوة — type I
✗ metab وحشة — type II

كويس 8-10
½½ 6-7
وحش < 6

CTG (Meyer-Mink) ⊕ → BPP (Manning) ⊕

	0	1	2
1. FHR	< 100	100-120	120-160
2. amplitude	< 5	5-15	> 15
3. Freq.	< 2	2-4	> 4
4. acc.	no	1	2/20 m
5. dec.	> 50%	< 50%	no

	0	2
✓ 1. CTG	< 2	> 2 acc./20 m.
2. f. breath.	less	cont. for 30 sec.
3. f. mov.	less	3 mov./30 m.
4. f. tone	-ve	opening/closing hand
✓ 5. AFV	< 1x1	1 pocket 1x1

Antepartum

1 FWB

Etiology

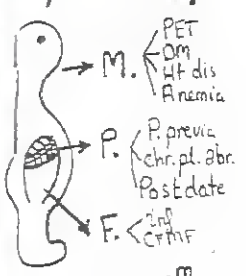

- M. < PET, DM, Ht dis, Anemia
- P. < P. previa, chr. pl. abr., Post date
- F. < 2nd CFMF

Both causes < M. / P.
↳ = Pl. insuffic.
↓ O_2 & nut. to fetus

1. Redist. of bl (Br. sparing) ↳ Assym. IUGR
2. ↓ pl. & renal bl. flow ↳ Oligohyd.
3. ↓ f. Kicks (to preserve energy)

Assesment

A] History < of risk factor / ↓ daily FMC (العادي ١٠ في ١٠)

B] Clinical < G: ↓ weight / L: ↓ abd. girth

C] Inv. (surveillance):-

CTG

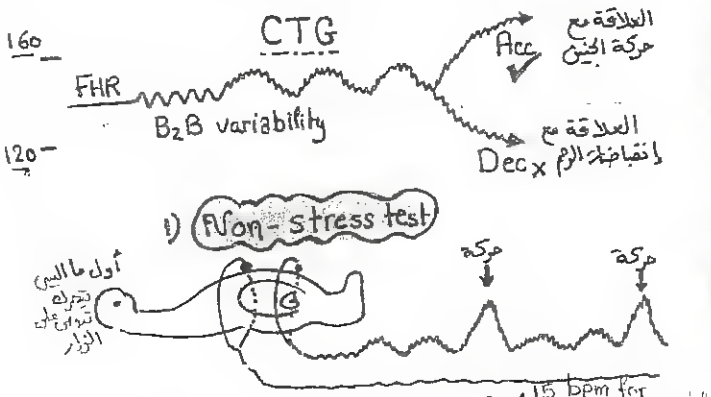

Reactive rise of FHR < 15 bpm for 15 sec in a period / 15-20 min

Non-reactive → 2) BPP / 3) Colour Doppler / 4) oxyt. Challange test

2) BPP

	0	2
1) NST		
2) AFI		
fetal 3) tone		
fetal 4) Mov.		
fetal 5) Breath.		

8-10 كويس
6 ½½: hypoxia
<6: وحش
TOP immed.

3) Colour Doppler
- ↑ resist. in umb. a
- ↓ resist in Mid cerb. a.

means pl. insuff
??

4) oxyt. Challange test
لا يعمل الآن
I.V. oxyt → cont.
+ve: deceleration
-ve: no dec. عادي كويس

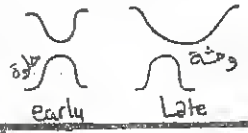

Management

- Chronic: conserve in (H) & close monitor
- Acute: e.g. acc. hge ↳ immediate TOP

2 CFMF

Types

- Cong.
- Chrom.

Cong.	Chrom.
• Structural defects	• Structural
• Biochem. "	• Numerical

Etiology

idiop. ///

- extrinsic
  - teratogens
  - Pollutions
- intrinsic
  - Mat. e.g. DM
  - fetal. e.g. p.pr.

Indications

1) Age > 35
2) Consanguinity
3) Previous history of CFMF
4) Exposure to etiology

Technique

1. Serum markers
   - ∝ FP (↓ in Down)
   - tripple test α β ʒ
2. 3D U/S ... MRIx
   - 12 wks → NTL (N: 1.5mm)
   - 18-20 → detailed anatomy
3. Invasive
   - Amniocentesis 16 wks
   - Ch. villus Sampling 8 wks
4. Recently
   - PGD (pre-impl. genetic diag.)
   - Fetal cells in mat. circ.

Intrapartum

Etiology

1] Chr. hypoxia (as antepartum) < M. / P. / F.

2] Acute hypoxia
- Placenta → sudden sep: Acc. hge
- Cord < prolapse, rupture vase previa, true knots, Cord around neck
- Head (prolonged compr.) < Long Rom / abst. lab., ut. hyper-toicity

Assesment

A.] clinical < Abn. FHR by < Pinard / Sonicaid
Mec. stained liquor

B.] electronic (CTG)

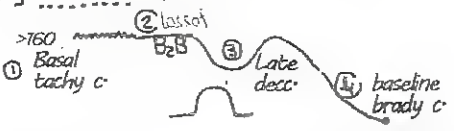

C.] chemical
fetal scalp bl. sample < 7.25-7.35 (N) / 7.2-7.25 mild / <7.2 severe acid.

Management

Immediately: change position to side / stop oxyt. / O_2 mask to mother / I.V. fluids

- Correction of FHR → cont. under very close monitoring
- failed
  - not fully dil → C.S.
  - fully dil
    - ceph. → forceps
    - Br. → extr.

Postpartum

Etiology

1] Persistance of < antepartum / intrapartum

2] PTL .... CFMF

3] Neonatal supression < Cardiac / Resp. < central / periph. obst. (mecon, blood)

Assesment

	0	1	2
Appearance	blue, pale		Pink
Pulse	absent		>100
Grimace	none		cry
Activity	flaccid		active
Resp.	absent		good

measured at < 1 min. / 5 min.

Management

- Prophy.: good < antepartum care / intrapartum care
- Active:
  - Assist vent. → endot. tube
  - Breathing < O_2 / clear air-way
  - Cardio-pulm. ressusc.
  - Drugs < Nalorphane / Na bicarb. (acidosis) / vit K. (hge) / Abx.

Obstetrics - Dr. Mohamed El Mandoob

IUGR

3 4
10th 90th

Macrosomia

Def

< 2.5 Kg (< 10th percentile) = path rest. of ability to grow } D.D. of LBW:
- Small & healthy
- IUGR عيل
- PTL عيل

> 4.5 Kg (> 90th percentile) = except in DM > ... Kg

%

5%

5%

Etiology

- الأم ..... بحيلة
  - HRP... PET ✓
  - برد
  - جوه
- الرحم ..... وحش
  - pl. previa.
  - pl. anomalies
  - cord anomalies
- الجنين ..... أهبل
  - CFMF
  - STORCH
  - T.T.T.T

= Pl. insuff.

generalized — Localized

✓ D O P E

Assesm

History

Exam.
- G.
- A.

Inv. [U/S] ✓
- Aetiology
- B
- Comp. (FWB)
- Diagn. (U/S)
- E

⇩ ± oligo

⇧ ± p hy

كلمة السر "2 weeks فرق"
- EGA & U/S
- * U/S وقت

ذكى II — Asymet — حلو — M. / pL.

أهبل I — Symet. — وحش — F

fetal weight may be known
- exam. — note D.D. of FL
- U/S
  - BPD
  - TTD
  - HL
  - TAD
  - FL
  - Biparietal
  - Trans-thor.
  - humerous
  - Trans abd
  - femur

wrong calc. of

أهم للوزن "TAD" → large margin of error

Comp.

Fetal Asphyxia
- hyp. isch. enceph.
- mecon. aspir.
- death

Fetal Injury
- obst. labor
- should. dyst. .... McRobert
- rupt. ut.

تعمل إيه فى الزنقة
- غير وضعك
- أطلب المساعدة

تشد الرأس؟
ولا تزق الرحم؟

P... osition	H... elp
O... xytocin	E... pisiotomy
S... upply fluids	L... ithotomy
I... mmediate	P... ressure
T... ermination	E... nter
O... xygen	R... otation
IV... eonatal resuscit.	

Ttt

Proph.
- Aspirin
- C.S. if macrosomia

Preg.
- أدوية
  - Aspirin
  - Heparin
  - Cortic.
- متابعة
  - FWB
  - growth
  - maturity
- أدوية .... Proper control of DM
- متابعة
  - FWB ... CTG, BPP, Doppler
  - growth ... serial U/S
  - maturity

TOP
- إمتى؟ As soon as ..... maturity could be documented
  - 1] History .... EDD
  - 2] Exam ... FL ?!
  - 3] Inv.
    - U/S
    - ?
- إزاى؟ "C.S."
- إزاى؟ عملياً
  - عملياً "C.S."
  - V.D. under cont. monitor

1] الأم — إمتى؟ إزاى؟ عملياً

2] الوزن

3] الجنين

1] Clinical
- FHS
- liqour color

2] electr. .. CTG

3] Biach. ... scalp Ph

PROM. 1-10% | Oligo 0.5% | Polyhydram. 0.5%

Def.

PROM.
- PROM < active ut. cont. — 10% ... 80% في حالة ولادة
- PPROM < 37 wks — 1% ... في خلال أيام PTL

Oligo
- Clinically ↓ amount
- U/S < AF < 0.5 L ; AFI < 5 cm

Polyhydram.
- ↑ amount ... > 2 L ... > 20 cm
- الأم — بالزائد 1st 1/2 — dynamic — بالناقص 2nd 1/2 — F.

etiology

PROM
- 7i
- inflation < twin, Polyhyd.
- inherent weakness
- insuff. nutr. ضعيف
- incompit. cx
- iatrogenic, I.C., infection ✓
- idiopath 2/3 of cases

Oligo
- Post-term
- PL. insuff. e.g. PET
- أفراز قليل
- CFMF (Potter), anti-PG
- فوق

Polyhydram.
- DM ✓
- chorioangioma
- 1] 2] 3]
- يرضع زيادة
- أفراز كثير
- - H. fetalis
- - twins esp. ?!
- - CFMF
- causes of g. anasarca: 1] open NTO, 2] esoph atresia, 3] Cong. nephrosis

C/P

PROM
- G. Sudden gush of H_2O vag. fluid .. D.D. < urine, show, inf.
- A. FL .... < amen.
- UG ... easily felt
- FHS ... easily heard
- الرحم moulded
- L. Never .... except if TOP is done. ∴

Oligo
- History of PROM ... PET ..
- } ! same
- → small bag of fore water

Polyhydram.

	Acute أمراض	Chronic أهمية
%	1/2000, 4-6 m	1/200, Late > 28 wks
sympt	- Rapid progr. - Abd pain	- gradual - Abd discomfort

Signs:
- G → dyspnea, palpit, ↓↓ edema ± PET
- A → • fetal parts unfelt ..... difficult to feel; • FHS unheard ..... difficult to hear
- L → cx is partially dilated ± bulging memb.

Inv.

PROM
- A. ....vag. swab: C&S
- B. ... FWB < CTG, BPP
- C. .... ESR, TLC, CRP
- D. .... U/S (non-inv.)
- E. amn. (v. invas.) بالصفة
- 1 History لو صعب
- 2 Sterile cusco شوف بعدين
- » يعمل Nitrazine, Nile blue, Fern test
- 3 U/S ... ↓ liquor
- 4 Amnioc. ..... نادر

Oligo
- Exclude ROM مهمة
- U/S → AFI < 5 cm ; CFMF ; Post-maturity

Polyhydram.
- Exclude DM مهمة
- U/S → AFI > 20 cm ; CFMF ; twins esp → uniovular → acute poly.

Comp.

PROM
- M. M → PTL → Chorioamn.
- F. F → Perinatal asphyx. d.t.
  - - malpresent.
  - - cord compr.
  - - cong. inf.
  - Prolonged oligohyd.
  - - lung hypop. مهمة بالزائد
  - - Arthrogryposis
  - - Talipes equinov.
  - <26 wks, >6 wks

Sympt. & Signs
- G) fever, ↑pulse, ↑WBC
- A) tender, f. tachy.
- C) Purulent disch.

Inv. < TLC, ESR ; Amnioc.

أرض الطبيعية → elevate! q. cond → TOP
- fluids
- ⊕ Abs
- • V.D. أحسن للأم
- • C.S.

Polyhydram.
- M عادي
- Pregnancy < PTL ; Pressure sympt ; PET ; P. pr. & acc. hge if malpresent.
- Part. — 1st, 2nd, 3rd — PROM, Prolonged, PPhge, P. sepsis
- Puerp. 3S
- F. PTL, CFMF

ttt

PROM
1) Proph.
2) Active
- Conserv. فخ إزاي
- TOP إمتى إزاي
3) Neon.

−ve	<26 ..... >35	+ve
!? tocolyt.	PTL الأم	
!? steroid	lung mat الجنين	
!? Abcs.	infect المرض	
Hosp.		TOP

- Hosp.
  - Fever Chart
  - Acute phase reactants على الكلى
  - Sterile dressing
  - Remove cerclage مستوى
- TOP
  - V.D.
    - fit ↳ induction
    - no fet. distr.
  - C.S. + strong Abs
    - الكلى

Oligo

Preg. Malformed
- No → • follow up fet. distress ; • ± amnioinfusion
- Yes → TOP

Labor CS% عالية
- → Prolonged lab } ولادة ناشفة
- → fetal distr.
- → malpr. (breech)

Polyhydram.

Acute: علاج TOP by
- Controlled ROM
- Drew Smythe

Chronic: Hosp.
- • Follow up < Nutrition, pr. sympt.
- • ttt of ! cause
- • Drugs < Anti-PG: ↓ F. urine ; Amnioreduction

TOP
- - CFMF
- - no improven

Twins

1/80

Helin's rule *

etiology

1) Race < familial (أكثر في نيجيريا) ↑age, ↑parity

2) Hormones < induction, C.O.C.

due to fertilization of one ovum by one sperm → constant factor all-over the world = 1/250

كلما كان الانقسام متأخراً كلما كان الاندماج أكثر
↳ • placenta • Am. mask • fetus

identical except in

Types

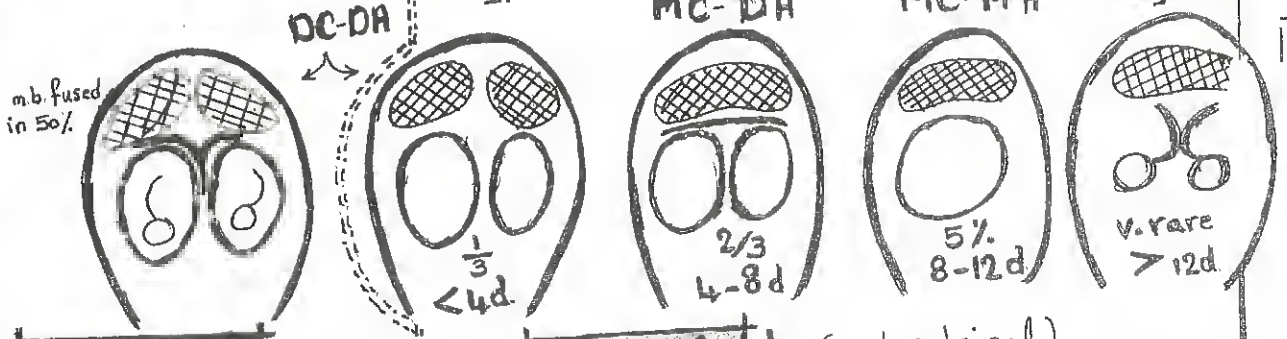

Inv.

- number 1. — 8 cells, فيه إمكان واحد يختفي في 20% = vanishing
- zygosity 2. — Lambda, Tau
- Comp. 3. — polyhyd.
- FWB, Doppler 4. — لكل طفل على حدة
- 5. selective embryo-reduction — إيه فايدة الـ...

Comp

M — F

- P. — Prolonged, PROM ← 1st
- P. — obst. Locked, !? Acc. hge ← 2nd
- P. — PPhge ← 3rd
- S3 ..... P.

حروف الـ M

2/3 Binovular (fraternal)

- CFMF
- IUGR ... discordant twin
- PTL
- IUFD ... maybe single fetal demise

فوق 20%

Monovular 1/3 (identical)

- TTTT < IUGR (donor) fetus, Hydramnios (recepient) — فيه واحدة
- Cord entanglement, acute polyhydramnios — كيس واحد
- Conjoined twin — عيل واحد

compressus / laqueus

(C/F)

- G. < excess weight, ↓↓ edema, PET
- A. — palpation
  - FL > amen.
  - multiple poles
  - delayed engag.
  - — auscultation
  - 2 FHS heard بواسطة سكاتوسكوب
  - Arnaux sign (gallop rhythm)
- L. — slow ex. dil.
  - large bag of 4 H_2O
    - PROM
    - cord prolapse
  - small present part

ttt

P — L

- Diet كويسة
- Rest أكثر — proph. cerclage, steroids ?!, tocolytics
- Followup أكثر
  - → الأم — علشان الأكل كتير
  - → الطفل — كل طفل لوحده

1st stage — guard against <

2nd stage
- twin A ---- episiotomy ✓, min. interference
- after its delivery --- no methergine ✗, exclude cord prolapse
- twin B → cephalic < spont. delivery (20-30 min) / if distressed or > 20 min
  - engaged → forceps / ventouse
  - non-engaged → IPV & br. ext.
- breech < spont. br. delivery / if ---- or ---- → Br. extraction
- transv. — IPV & br. extraction

3rd stage
- guard against PPhge
- إزاي تفرق الإيتين من بعض؟
  1. babies sex, group, HLA
  2. Placenta
     - → 2 ... binov. & 1/3 monov.
     - → 1 ... binov. & 2/3 monov. (fused)

C/S

1. Monoamniotic
1. st non-vertex
2. nd twin retained
3. babies or more

⊕ حالات عزيزة
- locked twin
- conjoined twin

Hydrops fetalis

= G. skin edema
+ fluid in ≥ serous cavity
+ placental thickening

immune

(↓ed > 1960)
(↓ed to 1.5%)

1. Rh
2. ABO (mild) — IgM
3. minor (Lewis) — Kell, Kid, Duffy — if received +ve

قبل الحمل: Grandmother theory

أثناء الحمل: Any maneuver
- Ab.
- ectopic
- amniocent
- ECV

مع الولادة
- esp. 3rd stage
- additional if
  - C. section
  - manual sep. of placenta
  - acc. hge

immunity
- 1ry: IgM
- 2ry: IgG

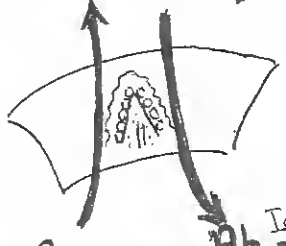

Ab → IgG

Ag: Cc, Dd, Ee (Homozyg. / Heterozyg.)
-ve in 15%
Lipoptin in RBC wall

non-immune

* causes of G. anasarca
* infections
* chromosomal (Turner)
* hematological (α-th.)
* TTTT

1. Cong. hemolytic anemia
2. Icterus gravis neon. — صفرا بعد الولادة بـ ٢٤ ساعة < Kernict C.P.
   ↳ mother removes bil intraut.
3. Hydrops fetalis
   ↳ HSM, Ht. failure
   - extra-medullary hematopoeisis
   - severe anemia < 8 gm%
4. reccurent IUFD
5. reccurent abortion

RH-ve mother
RH +ve father — متجوزة

PG

* Not affected except <
* Prophylaxis: Anti-D [RhoGAM] = 300 ug
  ↳ within 72 hrs (upto 3 wks)
  Some ... 28 wks (recently)
  ↳ no need if ! baby is Rh-ve
  ↳ Less need if minor maneuver (50-100 ug)
  ↳ more need if additional risk
* Best is according to Kleihuer Bêtke test = acid ellution test
  (300 ug < 30 fet. blood / 15 ml RBC)

N.B. Recent trials
steroids, de-sensitization → immunity
Ag → B.M. transplant
Ab → Plasmapheresis

MG

[0.1 ml is enough]
* Always affected (descending manner) except ... < sheep +ve RBC, anti-Ig.

Rh-titre (18-20 wks) indirect Coombs
- Sensitised (فقط 15% = 1.5%) — ليس هناك علاقة بين titre و affection درجة
  - ≥ 1/16 → Amniocentesis
    - ΔOD 450 nm
      - ↳ 28-30 wks (أو 10 wks قبل الوفاة)
    - Lilley's chart (♂): High / Mid / low; 8 gm%, 11-8, 13-11, >13 gm; high / low
  - ≤ 1/16 ... عيدة كل شهر
- Not <

a. low > 13 g → 3 wk → FT
b. Mid: 11-13 → 2 wk → 37-39; 8-11 → 1 wk → 35-37
c. High < 8 → L/S
- immature: intraut. transfusion
- mature: TOP

[O-ve: 10 ml/wk > 20 wks]
[intraperitoneal ... cordocentesis]

Other inv
- FWB
- U/S
- PUBS ?
- X-ray
  1. Buddha attitude
  2. Hala around scalp
  3. large pl. shadow
  4. IUFD ... B, O, K

Types

- Straight: Simpson ?, low forceps
- Curved: Wrigley] in C.S.

Ordinary
- Short
- Long — عايلة Chamberlein

Special
- Piper
- Kielland
  - Perineal curve
  - Breech after coming head

الطريقة — الشكل

1" — 7.5" — 3.5" — 2.5" — 5"

1] English
- Neville .... axist. piece handle
- Simpson ... Serration
- Barnes ... Notch
- ⊕ double slot

2] French (Tarnier)
- Axis t. piece: blades من جوه — علشان عبيله
- no serrations
- notch — علشان فراغير
- ⊕ screw lock

3] German (Milne-Murray)
- Axis t. piece: blades من برة — علشان ناهيين
- no serrations
- no notch — علشان جهدين
- ⊕ combined lock

(*) Lithotomy
- G. anesth
- sterilizati
- catheteriz

(*) left handle بالإيد الشمال في الناحية الشمال

(*) Right handle بالإيد اليمين في الناحية اليمين

(*) locking

(*) traction
- intermittent
- with ut. cont.

routine { (*) episiotomy, (*) fundo-perineal exam.

Blade (1) — min. pelvic curve — anterior or posterior
- fenestrated
- 2 curves
  - cephalic
  - pelvic

مش يمين وشمال ↓ علشان ← rotate

Shank (2) — longer ↓ علشان غالبة non-eng.
- to allow locking outside ! vagina

Lock (3) — sliding lock ↓ علشان يعدل ال asynclitism

Handle (4) — 2 Knobs تظبط بره ناحية ال occiput وداخلة وانت بتلف يبقوا قصاد عينك علشان في الآخر ← O.A.

Actions
- compression ✓
- vectis action ✓
- x lever action
- x stim. of ut. cont.
- x dilat. of cx

Traction
بإيد واحدة فقط
- should be applied with pelvic axis
  - down & back ---- down & forwards
- This may be helped by
  - (5) Axis traction piece ✗
- Replaced now by ..... Pajot maneuver
  - اضغط بإيدك التانية على ال shank

Rotation
- for
  - DTA
  - POP ... PMP
  - asynclitism
- methods
  - original ... ceph. curve looks anteriorly
  - direct ... ceph. curve looks posteriorly
  - wandering ... american
  - 1) ant. 1st
  - 2) post 2nd
  - 3) correct asynclism
  - 4) Rotation
  - 5) traction

Indications	Comp	Application	Level	Results
1] M. distress HRP to shorten 2nd stage - prolonged - exhausted - mal present. - 1st minor CPD - rigid perin. 2] F. distress IUGR with fully dil. cx & engaged head.	1] Maternal - injury < genital tract, Prolapse, SUI, fistula - hge - infection 2] Fetal - injury (forceps marks) - hge - infection - distress - death.	- cephalic ✗ - pelvic ✗ - cephalo pelvic here ! position cs < CPR, CPP (Sacral sacral [illegible]) [illegible] [illegible] علشان [illegible] لازم [illegible]	High ✗ zero .... mid +2 .... low ✓ outlet after crowning no need to separate ! labia to see ! head	1] Elective من الأول prophylactic f. after 20 min. from exdil to ↓ M. & F. distress 2] Trial (tentative) بحرص تجربة مرة واحدة لو فشلت ← خلاص 3] Failed يا صبر رغم الفشل ← يكررها كذا مرة أكيد فيه : CPD حوض ضيق ⟨ راس كبيرة

TOP

indications

M
- maternal dis.: DM, cardiac, HG
- mental illness e.g. schizophrenia
- or ... malignancy: Chemoth., Radioth.

F
- Missed abortion
- CFMF or exposure to a teratogen: X-ray, Rubella, X-drug
- Vesicular mole

methods

قبل 14
- medical: mifepristone, mesoprostone, methotrexate — 3 m
  - 1st → 99%
  - 2nd → 80%
- Surgical: E & C مشاكل
  - 1) Anesth.
  - 2) Hge ... retained pots
  - 3) inf ... Ashermann
  - 4) injury: perf. of ut. ✓, cx. tears

بعد 14
- medical: PG, oxyt.
- Surgical:
  - ROM
  - hysterotomy
  - زمان: intramniotic inj. of hypertonic
    - saline 20%
    - urea 40%
    - glucose 50%

± تحضير (laminaria tents)
أعشاب بحرية تمتص الماء وتوسع عنق الرحم زي .....

✓ Suction أحسن
by Karman cannula
- short time
- less trauma
- less hge

V. mole septic

hypernatremia ←
hypervolemia ←
infection ←
DIC ← الأخطر

---

induction of labor

Indication
- M: كل ال HRP
- F: كل ال fetology

Technique
- ✓✓ post-term
- IUGR, CFMF, IUFD
- polyhyd.
- PROM

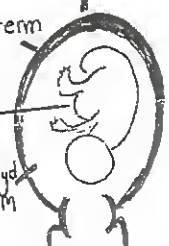

- stripping of memb. بلدي
- medications أدوية
  - prostein ... E_2
  - mesoprostol E_1
  - PG: في الأول
  - oxytocin: في الآخر
    - 5-10 u/500 saline
    - infusion drip
    - 0.5-2 mU/m
    - 1-2 mU/30m.
    - phys. cont.
- Amniotomy: AROM ... 1hr ... oxyt. جراحة

augment-ation يعني إيه؟

Bishop > 8 كويس
± تحضير: مهمة (Ripening of cx)

	0	1	2	3
1. Dilat.	closed	1-2	3-4	>4
2. effac.	0-30%	40-50	60-70	>80%
3. station	-3	-2	-1,0	+1,2
4. consist.	firm	medium	soft	
5. Position	post.	middle	ant.	

العكس: hind water ✗ / fore water ✓
Drew, Smythe

الميزة: easy, no injury, no anesth.
العيب: cord pr., bag of H_2O → infection, sudden → acc. hge

episotomy

Indication
- if perin. is about to tear
- to shorten 2nd stage ∴ less stress on mother, fetus, perin.

Technique

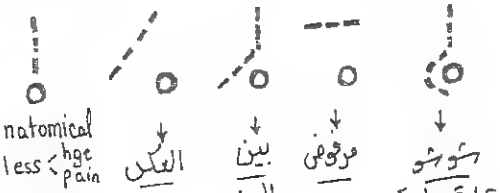

anatomical
- less hge pain
- easy repair

العكس: العيب ↓ يفتح ف .....
بين البين
مرفوض
شوشو: عملية مامة في حالات الـ fistula

---

indications

Pregn. [1]
- A.....
- B.....
- C.....
- D.....

Labor [2]
- mat. distress
- abn. ut. action
- fetal distress
- abn. present.
- Macrosomia
- bony
- soft

[3] previous op.
- >1 LSCS ..... obst.
- weak scar
- عملية ال ..... gyna
  - fistula
  - SUI
  - prolapse

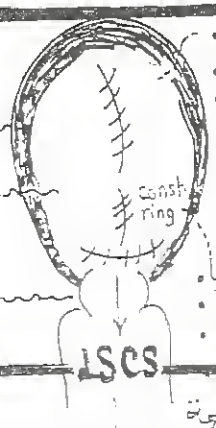

- fibroid in LUS
- V.V. in LUS
- fibrosis in LUS
- fist. ال زي بعد
- obst. ✓ shoulder ✓
- C. hysterectomy

const. ring

- less hge
- less injury: water
- less injury: uterine

LSCS

complications

- operative
  - anesth.
  - hge
  - injury
  - neonate → HMD
- post-op.
  - wound .....
  - uterus .....
  - urinary .....
  - GIT .....
  - DVT & P.E.
- mortality <0.1%

Advantage

:- less

technique

قبلها ... إقفل كل طبقة لوحدها
- uterus (2 layers)
- perit.
- sheath
- skin

العملية

anesth. cathet. sterilization
قبلها ... وسع البتر

- skin incision ↔ Pfannenstiel
  - = separate recti
  - = parietal perit. واقع
- uterine incision: C-shaped
  - = centralize ut.
  - = retract bladder تحت (Doyen)
- delivery of fetus & pl.
  - Scooping
  - forceps

Criteria for VBAC

مهمة

- → one LSCS (not USCS)
- → no permanent indication
- → no associated indication
- → no tenderness over scar
- → no previous op. difficulty
- 1st stage
  - vital data
  - ut. cont. / F. distress
  - any hge.
- 2nd stage ... [illegible]

PV: vertex, size, engaged

1] Hge
2] Rupture 0.2-0.4%
3] infection
4] Paralytic ileus
5] Postop. adhesions
6] Mortality rate

Abortion 10-20%

Etiology
Types
Pathophys.

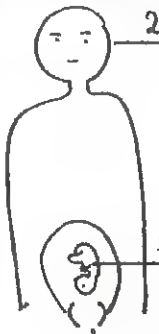

2. Systemic (مسلح)
- Diseases
- Endocrine — DM, thyroid; LPD (CLI); PCO
- Infection
- immun. — auto: APS, SLE; allo – Rh
- Drugs
- Trauma (منقطعة / متقطعة)

⊕ thrombophilia

1. Fetal (نتوء) → C.F.M.F. (numerical); Blighted ovum

3. Local (fresh) →

Habitual:
- 1. Patulous int. os
- 2. structural: عنق ضيقة – CMF flut.; – septum; – fibroid
- 3.

Triad

1st trim. / 2nd trim.

1. Amen.
2. Bleeding
3. Pain

Bleeding / ROM

PG

if ≥3 = Habit.

Types:

Spont.
- Threatened → cont. 80%; inevitable; missed; septic
- inevitable → Comp.; incomp.; cervical (D.D. ectopic)

Induced
- * Therapeutic: F + 3 (M, M, M)
- * Criminal

Ectopic 1-3%

Fertilized ovum (*) — early disap. of ZP; early develop. of ch. front.; migration (ext, int)



Tubal ✓✓

Rarely:

1. Cong. : hypoplasia, ostia, diverticula
2. Traumatic : on or near ! tube
3. Infl. : on or near ! tube — 50% (جي أكثر) ← chlamydia
4. Neop. : stretching ! tube
5. Misc. → endometriosis; ART; contraception (Progest., IUCD)

why ↑ed → ↑ STDs; ↑ contraception; ↑ infertility → ART

Types:

Undisturbed 2%
- Needs high level of susp
- U must be ectopically minded
- helped by early routine U/S

Disturbed
- Extra
- Intra

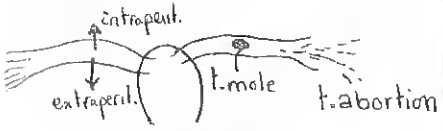

according to:

Blood
1. Acute: G. intraph. hge
2. Subacute: Peritubal hematoma
3. Chronic: Pelvic hematocele

Baby: نادراً ما يعيش + adv. abd. preg.

V. mole 1/1000

Benign tumor of trophoblast c/c by
- troph. proliferation
- hydropic deg. of Ch. villi

Androgenesis
Maternal chromosomes disappeared

صحاوية
46xx (all paternal)

1. Food

2. Fixation

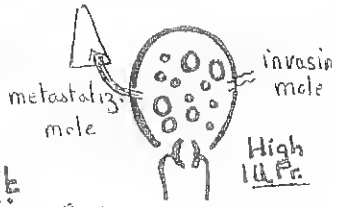

3. Funct. unit

⊕ بطيخة كبيرة برتقالتين

Types:

Complete — more common ✓
- 46xx all paternal
- malig. 10-20% ✓

Incomplete — Rare
- 69 xxy pat. + matern.
- malig. V. rare.

	Threatened	Inevitable	Missed	Septic	Undist.	Disturb.	V. mole
Def.	Partial separation of fert. ovum from ut. wall	comp. separation ↓ fetal expulsion	Retained non-viable fetus	Super imposed inf. • G+ve: GBS • G-ve: E.coli • Aner.: clostr.	early diagnosis < rupture	Rupture occured	Benign GTD
Sympt. 1. Amen 2. BL 3. Pain	+ve / slight / slight	+ve / severe (+ colick) / severe (+ backach)	+ve / No bL. → Br. disch. / No pain → absent f. Kicks	All are present followed by sympt. of inf. → FAHM-R → cont. lower abd pain → offensive disch.	- Short period of amen. (usually one missed period) - slight pain - no bleeding	- short / absent - sudden severe pain ↳ collapse - no/slight bL.	- Amen. (but no f. Kicks) - BL ± vesicles (diagnostic) - Pain < dull aching, colicky, sharp ± acute ?! abd.
Signs 1. G. 2. Abd 3. PV	signs of preg. / = F.L. / cx: closed	Pallor/shock / = F.L / cx: opened	No signs of preg. / ↓ F.L. / cx: < closed, ± Prune juice	Toxic Look / Tender uterus / Pelvic abscess/ physometra	- Signs of preg. - uterus slight ⇧ - mild tenderness or small adnexal swelling	- Shock not proport. to ext. bL - T, R, RT < Cullen shifting - Tender adnexum = Jumpin sign ✓	- Pallor / shock ± comp. - ut > FL < doughy, no FHS < twins, partial, bilat. U.gyl - vesicles
Inv. β-HCG U/S → etiology → comp.	+ve: doubles/2d. +ve → TV 5 wK, TA 7 wK, Sonicaid 10	clinically diagnosed, U/S → comp. / incomp.	→ no doubling → no fetal pulsation, Fibrinogen ✓	U/S < dead fetus, incomp. abortion → < blood: ESR, TLC, high vag. swab → DIC... Renal funct.	β-HCG: subnormal rise < 66% (مكن تبقى thr. ab.) TVUS: small sac outside ut. (مكن تبقى C.L. + AriaStella) → Combination Disc. zone = 2000 (من غير عمل جوه) لو زهقت < Laparoscope ✓, culdocentesis ✗	Clinically diagnosed → Hct level	- β HCG [illegible] for followup - U/S [illegible] - X ray - Honey comb, no fetal skeleton, chest: Cannon ball
Comp.	* Continues 70-80% * OR → inf. / dies / BL↑	- Hge - inf. - injury → perforation in D&C	• DIC < 100 mg% ↳ slowly 50/wK ↳ heparin may be given (twins) • Sepsis	SIRS 		Shock	General: - PIH < 20 wK - HG - thyrotox. - Pul. emb. / Local: - Hge, inf - Malig. - Perforation - Reccurence
ttt.	Conservation: 3 < Rest, Fe, anti-d; 3 < anti-PG ✓, Progest, β_2 agonist ✗; TOP if ✗	Rescussit.: 1st • suction • D&C; 2nd • oxyt. • PG; followed by • ecbolics • antibiotics	According to fibrinogen: > 100 → TOP (1st, 2nd); < 100 → correct first • fibrinogen • FFP • Fresh bL.	1 elevate G. cond. Antibiotics < high dose, combin. ICU, CVP, قطع كلية 2 TOP < suction ✓, hysterotomy, hysterect. Intoto 3 Comp. علاج الأعراض	Laparoscopy ✓ or Laparotomy → - Salpingectomy ✓, ovary - salpingotomy < PG, mild cases, one tube present. Medical = methotrexate • < 3cm, < 3000 • no ♡ pulsation • vitaly stable } 50 mg/m² I.M.	Rescussit. ↓ Laparotomy ↓ Salpingectomy • D&C ± • RH ±	Rescussit. صغيرة → Suction evac. then → ecbolics, ↳ curretage; كبيرة malig. 35% → Hysterect. but → Leave! ovaries. Follow up: 2-3 m. -ve, 6-12 m. C.O.C. (no IUCD) -ve, -ve, month, 6wK

Bleeding in early Preg

Mild < spots, pain

Threatened ab.

Etiology

- 2] Mat. < اعراض باطنة: endoc < ↓P, ↑And; imun. < SLE, APS; inf.
- 3] Local → عنق مفتوح
- 1] Fetal → عيل مشوه

G. A. L.

- Anemia
- Corresponds
- cx closed

المشكلة إنه متشبه

Invest.

H. → Repeat < β-HCG, TVUS, Hct

لو زلقت / شكيت → lapar.

ttt

3 أساسي: tocolytics, Anti-PG, Progest

3 بنتام: Fe, Rest, Anti-D

Undisturbed ect.

كلمة الر

>7d.

- Cong ----- DES
- tr ---- en/near
- infl ---- en/near
- Neep ---- stretch
- Misc < EØ, IUCD

HCG, E, P

1) Acute abd. → dist.
2) Discovery of mass
3) Discovery of fetus
4) Discrimination zone = 2000/TVUS

- laparoscopy
  - → salpingotomy
  - → salpingostomy
  - → salpingectomy
- Methotrexate
  - → < 3000
  - → < 3cm
  - → vitally stable

Acute abdomen

1] Acutely disturbed ⊕ shock

intra, extra, t. mole, t. ab., intraperit, intralig.

- Shock # ext. hge
- T, R, RT < Cullen's sign, Shifting dull
- Jumping sign

No need → clinical

- severe → acutely dist → G. Intraperit. hge → shocked
- mild → sub-acut. dist → Peri-tubal hemat. → مدروسة
- chronic → collects in Dpouch → Pelvic hematocele → pressure

1] Resuscit < Wide bore, Call + help

2] Laparotomy → Salpingectomy

2] Septic Abortion ⊕ fever

- org < G+ve, G-ve, anaerobe
- route < exog., endog., hemat
- pdB — criminal ab.
- FAHM-R
- cont. dull pain
- tender ± pelvic abess

الرعاية

Abc, C.sts, BP, pulse oximeter

elevation of g. Cond. ↓↓ fever

صغير → suction ✓, D&Cx

كبير → PG, hysterotomy, hyst.

TOP (op. theatre)

3] Vesicular Mole ⊕ complicated T. & cyst

→ ⊗ : "Androgenesis" ⊕ 46xx all paternal

بضخامة كبيرة + برتقالة

↑ IUP: 1) Benign 2) invasive 3) metastasizing

↑ Horm.: 1) PET 2) Hyperthyr 3) Hypothyr.

chest x-ray "cannon ball"

β-HCG >100000 — U/S snowstorm, Honeycomb

العلاج حسب السن

صغيرة → Suction ± ecb, D&C

كبيرة → hysterectomy

Follow up: صنوع الحمل COC — كل أسبوع → 2-3m — كل شهر → 6-12 month

غالباً V.D

- Cephalic
- Contractions
- DIC

AROM المطلوب + تطبيل + shock

1. Pdf → albumin
2. Dis. → U/S
3. Comp → FDPs

Pain → concealed

Bleeding → revealed

Placenta

acc. — previa



Bleeding

1. painless
2. causless
3. Reccurent
4. fresh

} U/S

غالباً C.S.

ممكن طبيعي if

mild bleeding — minor degree

Fetus

IUGR — macro

placental insuff

FGB ← (H) → Aspirin ± heparin

↓

TOP once mature or distressed.

obstructed → Ruptured

exhausted, painful → collapsed, calm

∴ C.S.

A. fluid

oligo — poly.

AFI 5 <

pl. insuff. ← due to

C.S. ← غالباً

> 20 AFI

due to < polyurea, large pl.

V.D ← ممكن

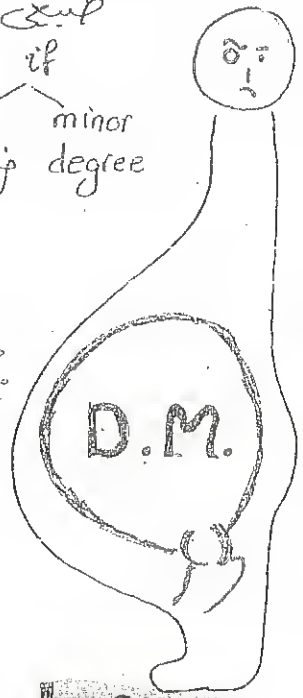

• Pdf	trophl. كبير ← vessel dis. ⊕ PG	cbcse ⊕ GMP
• Sympt	trenctes severity < Neurolog. of Comp. / epig. pain / oliguria	4P
• Signs	BPr. >140/90 — Alb >+1 300mg — ↓↓ edema < occult / manifest / dry	3↓ 3→ 3↑ NB! → ↑ Ps < Preg / Parl. / Peurp. → M
• Comp	M] eclampsia, HELLP, acc.hge — F] < IUGR / PTL / IUFD	screening 1 hr GTT → Confirm 3hr GTT
• Inv.	M] albumin ⊕ organ funct. tests — F] FGB ⊕ Doppler	
• ttt	mild → conserve; till < الأم / المرض / الجنين; severe → TOP ⊕ $MgSO_4$ / Anti-HTN	Pre concept. منع الحمل ← ANC → insulin, inv., TOP (إمتى) ← إزاي --- CS ✓ (40 / 38 / 37)

DM

Macrosomia

- Weight > 90th percentile
- > 4 kg (DM) > 4.5

G — D.O.P.E. — L

↑ Fl.
amen. < UG.
FHS.

best is proph. C.S.

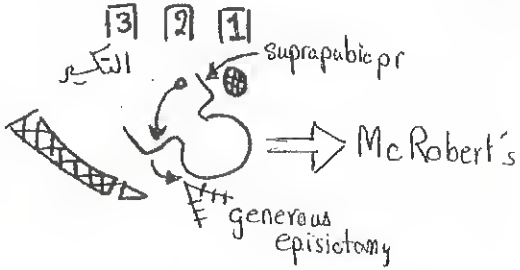

Polyhydramnios

- Clinically ↑ amount
- U/S AFI > 20 cm = AF > 2 L.



Acute	Chronic
1/2000	1/200 ✓
4-6 m	> 28 wk
كل حاجة أكبر	كل حاجة أقل

G] Pr. sympl, dd ed, PET

A] Pain, stretch < fetal parts, FHS

d] cx partially dilated

etiology

- Fl ↑
- UG > amen
- FHS كبيرة

M) < P P P ; F) < PTL, CFMF

Diagn.

Comp.

Manag.

Conserv ------ TOP

± anti-PG
± amnio-reduction

± controlled ROM
± Drew Smythe

PTL

- induced
- spont

M أم بجلة

twins, CFMF, H. fetalis — F

مطبخ وحش — كيس لفل — L

β_2

$MgSO_4$

Ca ⊖

Tocolytics

Atosiban حديثاً

Anti-PG

Steroids

- Beta: 12 mg/24 مرتين
- Dexa: 6 mg/12 ع مرة

28 – 34 أسبوعاً

حديثاً مرة واحدة

شبه الـ abortion

- Pts at risk
- threat. PTL
  - وجع خفيف
  - زيادة إفرازات
  - تمسح في الكلية
- established (inevitable)
  - > 2 cm dil
  - > 6 cont/hr
- Premature baby

PROM

- 10% < active ut. cont (PROM) — 80% ولادة في 24 ساعة
- 1% < 37 wks (PPROM) — 1/3 PTL في خلال أيام

etiology

- Fl ↓
- UG < amen
- FHS ↓

Diagn.

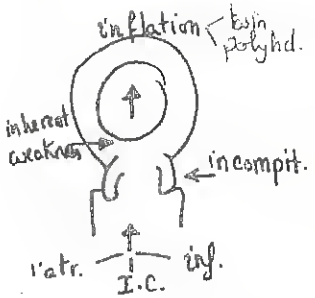

- History صبة < show, disch., urine
- Sterile cusco < Nitrazine, Nile blue, Fern
- U/S AFI
- Amnicoc لا تعمل

Comp.

- chorioamn.
- Prematurity

−ve	+ve
< 26 ---- > 35	
× Tocolytics	الأم ... ولادة
Single dose = steroids	mat. ... الجنين
✓✓ Abes	inf. ... الأم

TOP < V.D < fit 4 ind., no fetal distress; C.S. العكس

fever chart + H. + TLC, ESR, CRP

Manag.

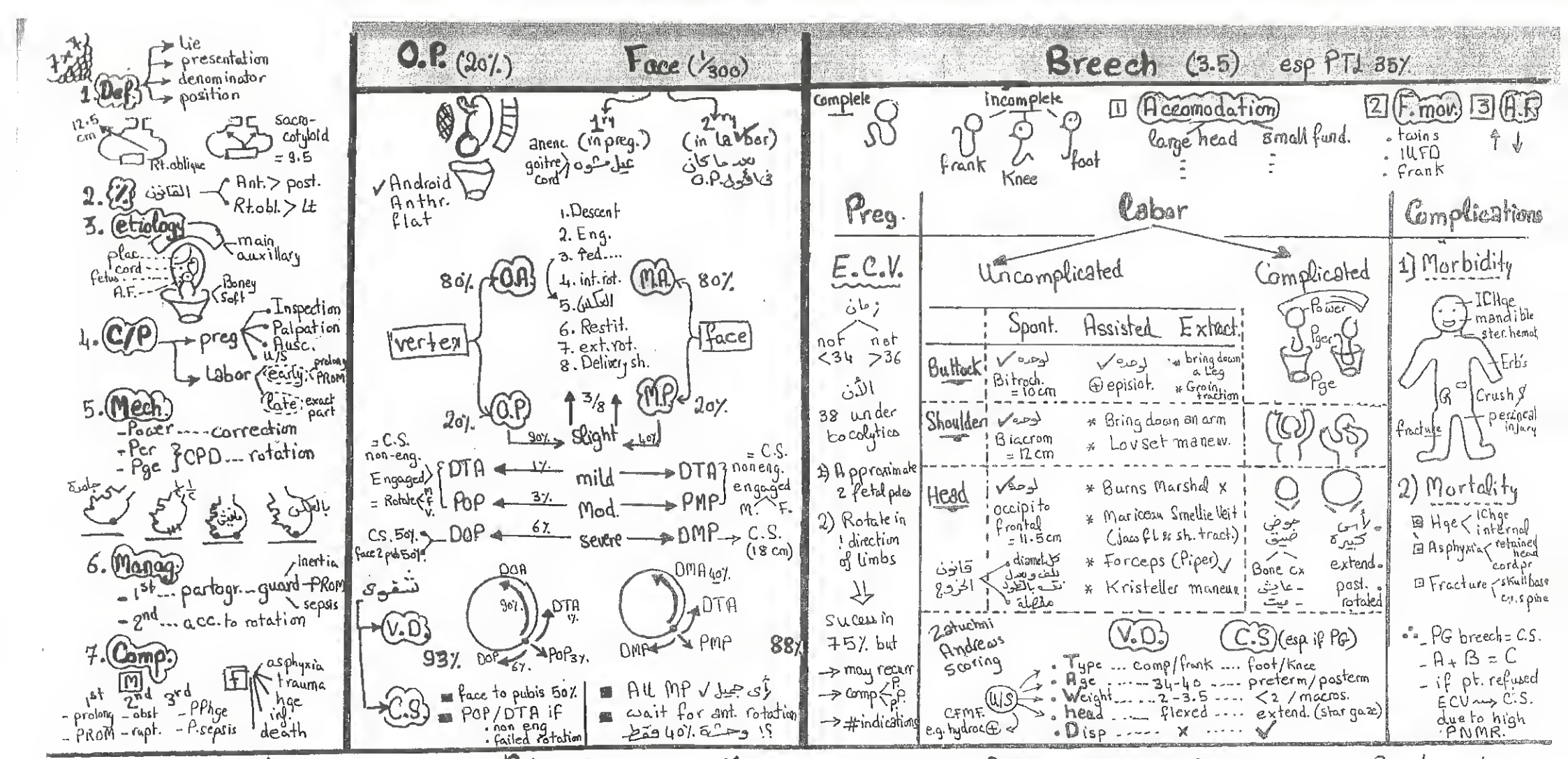
1. Def.
lie
presentation
denominator
position
12.5 cm
Rt. oblique
sacro-cotyloid = 9.5
2. % التقاوين
Ant. > post.
Rt. obl. > Lt
3. etiology
main
auxillary
placenta
cord
fetus
A.F.
Boney
Soft
4. C/P
preg
Inspection
Palpation
Ausc.
U/S
Labor
early: prolong PROM
late: exact part
5. Mech.
- Power ---- correction
- Per
- Pge } CPD ... rotation
جالسة
بالعكس
6. Manag.
- 1st ... partogr. -- guard - PROM
inertia
sepsis
- 2nd ... acc. to rotation
7. Comp.
M
1st - prolong - PROM
2nd - obst - rupt.
3rd - PPhge - P. sepsis
F
asphyxia
trauma
hge
inf.
death
O.P. (20%)
Face (1/300)
Android
Anthr.
flat
anenc.
goitre
cord
1st (in preg.)
عيل مشوه
2nd (in labor)
بعد ما كان في الحمل O.P.
1. Descent
2. Eng.
3. Fed....
4. int. rot.
5. الكتلة
6. Restit.
7. ext. rot.
8. Delivery sh.
80%
O.A.
M.A.
80%
vertex
face
20%
O.P.
M.P.
20%
3/8
90%
Slight
40%
= C.S.
non-eng.
Engaged
= Rotate
DTA
POP
DOP
1%
3%
6%
mild
Mod.
severe
DTA
PMP
DMP
= C.S.
non eng.
engaged
M. F.
C.S. (18 cm)
C.S. 50%
face 2 pelv 50%
شفوي
V.D.
93%
DOA
90%
DTA 1%
DOP 6%
POP 3%
DMA 40%
DTA
DMA
PMP
88%
C.S.
face to pubis 50%
POP/DTA if
non eng
failed rotation
All MP
wait for ant. rotation
Breech (3.5) esp PT1 35%
Complete
Incomplete
frank
Knee
foot
1 Accomodation
large head
small fund.
2 F. mov.
3 A.F.
twins
IUFD
frank
Preg.
E.C.V.
زمان
not <34
not >36
الآن
38 under tocolytics
1) Approximate 2 fetal poles
2) Rotate in ! direction of limbs
Sucess in 75% but
→ may recur
→ comp < P. / P.P.
→ # indications
Labor
Uncomplicated
Complicated
Spont.
Assisted
Extract.
Buttock
Bitroch. = 10 cm
episiot.
bring down a Leg
Groin traction
Shoulder
Biacrom = 12 cm
Bring down an arm
Lovset maneuv.
Head
occipito frontal = 11.5 cm
Burns Marshal
Mariceau Smellie Veit (Jaws fl & sh. tract)
Forceps (Piper)
Kristeller maneuv.
قانون الخروج
Bone cx
عايش
ميت
حوض ضيق
رأس كبيرة
extend.
post. rotated
Zatuchni Andrews Scoring
W.S
CFMF
e.g. hydroc
Type ... comp/frank .... foot/Knee
Age ..... 34-40 .... preterm/posterm
Weight ..... 2-3.5 .... <2 / macros.
head ..... flexed .... extend. (star gaze)
Disp ..... × .... ✓
V.D.
C.S (esp if PG)
Power
Per
Pge
Complications
1) Morbidity
ICHge
mandible
ster. hemat.
Erb's
Crush
perineal injury
fracture
2) Mortality
Hge < ICHge / internal
Asphyxia < retained head / cord pr
Fracture < skull base / c.n. spine
∴ - PG breech = C.S.
- A + B = C
- if pt. refused ECV → C.S. due to high PNMR.
etiology
50%
gynec.
Andr. 20%
Anthropoid 25%
flat 5%
Cong.
acquired
* G. cont. p.
* Naegele's / Robert
* high ✓ / low ×
* Split / Otto
Kyphosis
Scoliosis
Spondyl.
Rick.
Osteom.
Fracture
Amputation
tumor
Diagnosis
C.P
CPD
1. Mild (10-9) ..... No.
2. Mod (9-8) 1st
3. severe (8-6)
4. extr. (<6) } 2nd
Pelvimetry
Subpubic angle
Tsch. spines
Pinard
Muller
Kerr's
Management
V.D.
C.S.
Trial of lab.
Why ?!
- Power: m.b. effective
- Per: Asyn., moulding
- Pge: pelvic give
Who ?!
- Power: PG, healthy
Per: vertex, OA
Pge: 1st CPD no cont. outlet
Partogram
How ?!
alert
action
zero
200
<20 - 40>
Obst.
- Dehydrated
- Anxious
- severe p.
- F. distr.
- warm
- edema
- caput
G.
A.
L.
Rupture ut.
- Collapsed
- Calm
T
R
RT
- Acute abd
- F. death
- Hge
- no present part.

Normal Pelvis

- inlet (shape)
- cavity (isch.sp)
- outlet < sacro-sc. notch / sub pubic angle

Gynec. 50% — Andr. 20%

- inlet
- cavity < project / not
- outlet < wide / narrow

Platy-pelloid — Flat 25% — Anthropoid 5%

Inlet

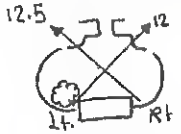

Cavity

plane of greatest pelvic dimension → rotation

Outlet

	AP	obl.	Tr.
inlet	11 (10.5)	↑	13
cav.	←	12 (12.5)	→
outlet	13	↓	11 (10.5)

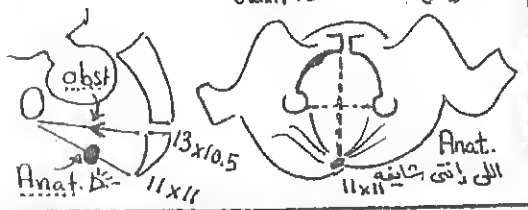

Pelvic axis

Anat. — C-shaped

Obst — L-shaped

Isch. spines '7'

- < حطة < uterus (prolapse) / fetus (engag.)
- < بيلفو < ureter / fetus
- < surf. anat. < plane of least / pud. n. block

⊕ Pelvic floor

Contracted Pelvis

1 Cong. — حوض ضيق

2 Acquired — Kyphosis, Scoliosis, Rickets, Osteom., fr./tum., dimbing, fract./tum, Amputation, Poliomyel.

Diagnosis

History — مشكلة في الولادة السابقة < M. / F.

Exam
- 1) G < spine: / الحوض: signs of old rickets / L.L.:
- ⊕ short < 150 cm ⊕ Dystacia, dystrophia syndrome
- 2) A — malpresent. / non-engagement
- 3) L — Pelvimetry → ext < sub-pubic angle / Bitub. diam. ✓ ; → int. < isch. spine ✓✓ / Sacrosciatic notch / Diagonal conj ?!

Inv.
- * U/S esp in Breech < BPD / HC / occipito fr.
- * Radiolog. pelvimetry ✗ كان زمان

Comp.

M. → F.

- Preg < malpres. / non-eng.
- Part < 1st ... Prolong, PROM / 2nd ... obst. / 3rd .... PPhge
- Peurp ... sepsis

5F < injury / hge / inf. / hypoxia / death

C.P.D.

Types

- No → V.D. ✓
- Moderate (1st° CPD) → Trial of lab.
- Marked (2nd° CPD) → C.S. ✓

Diagnosis

Pinard — د. واحد من فوق ..... بالشمال

Muller — كدكارة فوق ⊕ تحت

✓ Kerr — د. واحد من فوق وتحت .....

Manag. — trial of lab. ?!

- why < Power .... m.b. effective / Per ..... moulding / Pge .... yielding
- who < Power → PG healthy young / Per → vertex OA / Pge → 1st° CPD
- how < 1st stage (partog.) < guard against ARom ... oxyt. / 2nd stage < engaged .. F. or V. / non eng .. CS

Comp. ⇝ C.S. ?! عكس who

- □ Old., non-healthy
- □ non vertex pr.
- □ 2nd° CPD

⊕ general causes for C-S < unfit 4 induction / F/M dis tress / Ass. obst. ind.

Obst. Labor

etiology

عيل كبير ⊕ حوض ضيق

- Malpr. (large diam)
- Macrosom < general: DM ... / local e.g. hydrocephalus
- Locked twin (v. rare)

→ Bony : CP
→ Soft : Fibroid, Cont. ring, cx dyst., vag. cyst, rigid per. inter. (scalling)

Diagnosis

History of — Prolonged lab. / PROM / cause e.g. CPD

Phys. → ret. ring.

path. ring — hard & tender / F. dist.

- warm
- edema
- caput

- Dehyd
- exhaustion

Manag.

⊛ Proph. ✓ early diag. of CPD < signs & sympt. of obst

⊛ Active
- ✓ C.S. صعبة < head deeply engag. / dUS ballooned → injury
- لو V.D. → لازم exploration of birth canal under anesth. → excl. traumas
- * Forceps → خطر → يفرقع

Comp. علمي

M.
- Part < 1st ... Rupt. ut. / 2nd / 3rd .... Necrotic vesicovag. fistula
- Peurp ....

F. — 5F ...

Rupture uterus

etiology

Preg. < Spont. if weak scar e.g. U.S.C.S. / Myomectomy ; traum. ext.

labor < Spont. ✓ if obst. labor esp if improper use of ecbolics to augment. ; traum. < Forceps / Fund. press. / Breech < ext. / int. / P / V

Diagnosis

- Collapsed
- calm

acute abd T, R, RT — F. death — easy felt

- vag bleeding
- upward recession of ! presenting part

Manag.

⊛ Proph. ✓
- Partogram ⇝ early detection of CPD
- Proper use ⇝ ecbolics, forceps
- Proper manag. of previous scar ⇝ only one LCSS → V.D.

⊛ Active

✓ Hysterect. ; Repair ✗ ?!

Age, parity	↑ ↑	young, NP
Bleeding	severe	controlled
tear	extensive	limited

Comp.

M.
1) ↑ MMR
2) Hysterect. < infertility / possibility of uteric injury
3) Repair → rupt. ut. in next preg.

F. ↑ PNMR

	IUGR 5%	Macrosom 5%
Def.	- B.W. < 10th percentile - Pl. insuff. is d.t. < maternal / placental	- B.W. > 90th p. > 4.5 or > 4 (D.M.)
Etiology "idiopathic in 2/3 cases"	HRP ✓, جيار, دوا تقوية, inf., CFMF, M أم بجلة, P طفح وحش, F عيب	G D..... ✓ O..... P..... E.....
C/P	G ⇩ weight < <50 Kg / >28 wks A → FL. < amen. (gravidogram) → UG. ... oligohyd. (abd. girth) → FHS ... ± f. distress I	- ⇧ weight - > amenorrhea {previous history / presence of etiology}
Inv. A. B. C. D. E.	- GTT, Storcheb diagnosis U/S 2 types → متأخر أكثر في أسبوعين: I < symet. F, وحش → أسرع: II < asymet. P, M, حلو * EGA & U/S * serial U/S	- GTT السكر ± الأنسولين - U/S → esp. T.A.D.
Comp.	M. → P. (مرض PJ), P. (23), P. (3S); F. → P. (عروق), P. fetal ✗	.Preg..... IUFD • labor < HIE. عيل تعبان / MAS: مياه قليلة • Fetus < hypo < glycemia, calcemia, thermia; polyc.... Jaund., DVT
		Shoulder dyst. ✓ إزاي تعرفها؟ إيه مشاكلها؟ → M.... PPhge < atonic, traum. cut. → F.... ✗
ttt	1. Prophylaxis 2. Active → Cons. فين إزاي / TOP امتى إزاي 3. Neonate	⊛ Proph. Baby aspirin 75mg ⊛ Preg. < I... TOP; II... hospit. → 1. ttt of ! cause; 2. Drugs < aspirin, heparin, steroids; 3. follow up ⊛ TOP < - growth (U/S); - maturity (L/S); - FWB + Doppler ✓ • C.S.... عيل تعبان + حاد قليل غالباً • V.D.... ممكن .. CTG لو عندي	⊛ Proph. أهم - ttt of D.M. - elective C.S. ⊛ Active إلحقوا 1. < episiotomy; Mc Robert; supra-pubic 2. < Bring down post. arm; rotate trunk 3. < cleidotomy; symphysiotomy; Zavanelli ?!

	PROM 1-10%	Oligo 0.5%	Poly 0.5%
Def.	10% < active ut. cont. (PROM) ..... في ٢٤ ساعة 80% ولادة 1% < 37 wks (P. PROM) ..... PTL في خلال أيام	* clinically ↓ amount * U/S < AF < 0.5 L; AFI < 5 cm	* clinically ↑ amount * U/S < AF > 2 L; AFI > 20 cm
Etiology	ti: inflation < twin, polyhyd.; • inherent weakness; • insuff. nut. ضعيف; incompet.; I.C., infection ✓, iatrogenic	Post term; Pl. insuff.; إفراز قليل; فرق; CFMF (Potter); anti-PG.	D.M. ✓; chorio angioma; إفراز كتير; • H. fetalis; • twins; • CFMF; e.g. - open NTD; - esoph. atresia; - cong. nephrosis; causes of g. edema
C/P	* sudden gush of H_2O vag. fluid: D.D. < - < amen. - easily felt - easily head } الرحم moulded * Never.... except if.....	± P.E.T. } same → small bag of forewater	acute: 1/2000, 4-6 m. كل حاجة أكتر chronic ✓: 1/200, >28 wks كل حاجة أقل G] Pr. sympt., LLed., PET A] Pain, stretch < fetal parts, FHS I] cx. partially dilated
Diagnosis	History < urine, show, inf.; صعب; sterile cusco < nitrazine, nile blue, Fern; AFI; U/S liquor amount; amniocent. < ± dye, inf.	• exclude ROM مرجعة U/S → AFI, CFMF, post-maturity	• GTT مرجعة U/S → AFI > 20 cm; CFMF; twins → univ. → acute
Comp.	M → PTL; Chorioam. G.... fever, ↑pulse, ↓UOP A.... tend., fetal tachyc. I.... purulent disch. F → peri-natal asphyxia, malp., cord compression; Prolonged oligo: • lung hypoplasia; • Adhesions; • Talipes equinv.	M: عادي → Ps → P < → P..3S F: CFMF, PTL ✓	
ttt	-ve: < 26 ... > 35; tocolyt. ... PTL; steroid. ... lung mat.; abcs ... infection +ve: TOP • fever chart; • TLC, ESR, CRP; • remove cerclage V.D.: - fit for induction; - no f. distress C.S.: العكس - Abcs; - extraperit.	⊛ Preg: → malformed: No / Yes: TOP; • follow up f. distress; ± amnioinfusion ⊛ labor: → CS% عالية: وحدة ناشئة; • prolonged labor; • fetal distress; • malp. (breech)	⊛ Acute → TOP by: ليه؟ Controlled ✓ / Oreo Smythe; force H_2O ⊛ Chronic: Conserv. < ttt of ! cause; • drugs - anti PG - amnio reduction; • follow up < nutrition, ex. sympt. TOP if: no CFMF improv.

	Preterm 5-10%	Postterm 5-10%
Def.	labor < 37 wk ut. > 6-8/hr, > 4/20 m.; Cx > 2 cm dil., > 80% eff.	Preg. > 42nd wk Dysmature < post. + IUGR
Etiology	⊛ Spont.: M أم بجلة, I, twins, CFMF, H. fetalis, F, Af. Infection, Polyhyd., PROM, أم نشوة, مطبخ وحش ⊛ Induced for < M. / F. sake	* wrong dates ✓ * No < oxyt. i.e. / PG i.e. } steroids i.e.
C/P	1 Pts at risk: - Good ANC < inf., anemia; - Sedative, no SI, rest; Serial < TVUS, fibronectin; - 2 medicine < Prog., tocolysis; esp. < previous PTL, polyhyd., PROM, twins 2 Threatened PTL: < false L. pain ± backache; change of cce of disch.; Hospit. to assess * uterus (palpate) * cx (monitor, Bishop) * fetus (BPP) 3 Established PTL: * Hospit. < rest, hydration; * Abcs ✓; * tocolytics < β_2 agonists, Ca^{++} blockers, anti-PG; * steroids < $MgSO_4$; → Beta 12mg/24 (2 doses); → Dexa 6/12 hr (4 doses) 4 if delivery occured: 1st: • Abcs, • vit. K, • avoid depressant drugs; 2nd: • episi., • forceps, • CS if < distress, IUGR, breech; N.B.: special care	⇩ weight.. ⇩ abd. girth (علشان المياه قليلة بالرغم من أن حجمه كبير) U/S → BPD >10.2; liquor قليل / معكر; Pl. Ca^{++} M.: عادي F.: 1st asphyxia مياه قليلة; 2nd مشيمة متكلسة; 3rd injury عيل كبير
ttt		فوق 40 wks: • FWB twice/wk; • fetal Kicks 41 wks: • fit → إخلص; • not → إستنى (AFI أهم حاجة) 42 wks: النهاية V.D. ✓; C.S. PG → ARom → oxyt. عيل كبير مياه قليلة

Intra-partum "FWB"

1 Clinical = partogram

- intermittent ausc. (Pinard)
  - 1st ..... 30 m. } heard after ut. cont. for 30 sec.
  - 2nd ..... 5 m.
- A.F. colour
  - Meconium stained (distress)
  - Normal in: Breech, oligo, post date

2 Electronic

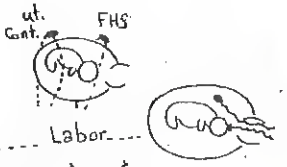

- external
- internal ---- Labor ---
  - B_2B ← بالإبرة ext. أدق وأسهل
  - ROM, ceph, cx dil ← لازم
  - inf., injury ← الأشكال

3 Biochemical

- fetal scalp Ph — مؤشر كمان الـ Ph بتاع الدم
  - N ... > 7.25
  - borderline ... 7.2–7.25
  - distress ... < 7.2 ⇝ C.S.
- fetal pulse oximetry — جديدة

شوي ↓ acute fetal distress

- change pt. position
- stop ecbolics (± start tocolytic)
- give < fluid / O_2
- if still distressed < C.S. (if < full dil) / forceps, vent. } if full dil - engaged

"Tocolytics"

1 Types

- long term .... widely used ... but no improvement in neon. outcome
- short term .... 48–72 hrs ... till steroid act & transfer to hospit. ✓

2 Indications

- Mother ⟶ distress ... PET
- Fetus ⟶ distress ... IUGR
- dis. (PTL) ⟶ progress ... > 4 cm, fully effaced, Rom

} contraind. for prolongation

3 B_2-agonists

- Ritodrine Hcl
- Yutopar ✓

50 mg ampoule / titration till contr. disapear ... مشكلة

B_1 effects with↑ dose

- Mother:
  - Palpit., ischemia
  - arrhythmia
  - Pul. edema (if + steroids)
  - hypergly.
  - hyperinsulin — علشان كده صنوع في الأنسولين
  - hypoglyc. & hypo Kalemia — مرضى
- Fetus:
  - tachyc. & arrhythmia + B_2B
  - Hypoglyc. Hypocalc. Hyperbili.

$MgSO_4$

- Loading — 4–6 gm IV / hour
- maint — 1–2 gm IV drip / hour
- excretion — Kidney
- follow up
  - Knee jerk
  - UOP
  - Resp. rate
- therap. level — 4–7 mEq/L
- Toxicity
  - 8–12 ... Knee
  - 12–15 ... Resp
  - 15–30 ... cardiac

Anti-PG

- oral — Brufen 25 mg 1×4
- rectal — Profenid, indocid 100 mg 1×2
- side effects
  - Mother: stomach ulcer
  - fetus < premat. closure of ductus art. / oligohydramn.

Ca channel blocker — كويس الآن

- Loading — 10 mg / 20 m. (4 doses)
- maint. — 10 mg / 6 hrs
- Adv. ... same efficacy as yutopar & more safe
- Side effect ... hypot., flush, tachyc.

Steroids

- indic ... all HRP ⇝ enhance fetal release of surfactant
- contraindic < DM, HTN } poor control < PROM, RHD } inf.
- Dose (24 mg) --- Beta 12 mg/24 مرتين ... Dexa 6 mg/12 أربع مرات
- Method --- multiple ..... single حديثة
  - < 28 بدري — 28–34 أسبوعيا — > 34 لازم
  - ↓ side effects

"Ecbolics"

1 Oxytocin

Nonapeptide < synth. in hypoth. / stored in post. pit.

أكثر - Late - contr. - safe

- uses
  - Preg. < early .... ind. of ab., ttt of postab. bl / late .... ripening of cx, ind. of labor
  - Labor < 1st ..... augment. of labor, ttt of iner / 3rd .... manag. of 3rd st., ttt of PP
  - Lactation .... may be used as lactogogu
- Comp.
  - over-stim. < Mother: R.ut., AFer / Fetus: Pl. insuff → d
  - over-dosage < water intoxic: hypon / neonatal jaundice
- Contraind. — ut. scar, GMP; pl. insuf, f. distress; CPD, p. prev., Tr. lie } absc
- administr. titration :- 0.5–2 /m (mIU) → ↑ by 1–2/m (mIU)

2 PG analogues

أكثر - early - ripening - dangerous

- * Cx → Ripening of cx & induction of labor
  - PGE_2 ... prostein, vagiprost } 25 ug/(4 dos
  - PGE_1 ... cytotec, mesotec
- * uterus
  - * intraut. extramn (ind. of ab.)
  - * intramyometrial (in PPhge)
  } PGF_2
- * fetus
  - Keeps ductus art. patent
  - helps urine production

3 Methergine — ergot alkaloide

أكثر tonic علشان كده بيعطى لحد (twins - الخلفة)

- uses (action lasts 4 hrs)
  - Abortion .... postab. bl.
  - 3rd stage ... atonic PPhge
- Comp. if
  - < fetal delivery → distress
  - > dose → V.C → HTN & ischemia

- * oral — 1 mg --- 7 min
- * IM — 0.5 mg --- 3.5 m
- * IV — 0.25 mg --- 1 m.

IUFD

أسباب غريبة لكن للأسف ☹

- Antenatal :- IUGR
- Intranatal :- ⊕ fetal < asphyxia, hge, trauma, inf.
- Post natal :- ⊕ PTL ✓✓

PNMR = (still birth + neonatal death) / (total birth in same year) × 1000

F. distress

- Ante-natal
- Intra-natal

ttt
- Prophyl. ... FWB
- active ... TOP

N. asphyxia

= asphyxia neonatorum

- A. Livida
- A. pallida

Ass. of lung mat.

- History .... dMP
- clinical ..... f. level
- Inv. → U/S < AF turbid, PL calc. grade III
- L/S ratio, bubble stability → aminocent.

R. distress synd

- type I ... HMD
- type II ... TTN

و تنفسي

Mecon. aspirat.

APGAR score

- Appearance
- Pulse
- Grimace
- Attitude
- Resp. rate

N. jaundice

- Physiological
- Patholog.
  - Prehepatic
  - hepatic
  - obstructive

لا تنسى Rh

fetal loss

- Early
- Late
- Reccurent

etiology
- 60-70% F. ✓✓
- M.
- L.

C/P
- thr.
- inev. < Comp / incomp / cx.
- missed
- septic

Comp.
- Hge
- Inf
- Injury إزاي؟

ttt
(thr.) Conserv.
- 3) anti-PG, Progest., β_2 agonists
- 3) Rest, Fe, anti-d

TOP
- Ress if inev.
- fibrin. if missed
- Abcs if septic
- < 14 < M..... 3M / S..... E&C or sucti
- > 14 < M..... PG oxyt. / S..... hysterotom.

1. Ante-partum

HRP
- أم حبلة
- P.pr. وضع
- Fetology عيل أهبل

How to detect ?!

Screening (ANC)
- * PET
  - PG, obese, age↑
  - Preg. with ⇐
  - Past H. of ....
  - → screened by Dopler
- * DM
  - obese, GMP
  - obst H... ⇐
  - Past H. of ....
  - → screened by thr PPS

FWB
- F. Kicks
- Progr. abd ⇧
- U/S
- Doppler
- CTG
- BPP

CFMF
- أنا
- scan: U/S, 3D
- lab: ↓FP
- scope: Amnioc.
- biopsy: PGD, CVS

PTL
PROM < oligo / Poly
حبة كبيرة قوية

± steroids → IUGR
± Tocolytics → PTL
± Abcs → PROM

2. Intra-partum

Fetal
- asphyxia
- injury
- IChge
- Infect.

How to avoid ?!
- Good INC
- 1st
  - 1] clinical < "FHS" / Partogr. / liquor
  - 2] Elect. = CTG
  - 3] chemical = scalp ph
- 2nd
  - ceph: proper forc. applic.
  - breech: proper delivery or CS
  - Macr: early CS → avoid sh.
  - PROM: proph Abcs
  - PTL: proph vit K

3. Post-partum < APGAR / ABCDE

etiology

Systemic 2.
- endocrine
  - CLI ✓✓
  - PCO ✓
  - DM, thyr.
- Immune
  - Auto < SLE / APS ✓✓✓
  - Allo < Rh / HLA
- thrombophilia
- Infection

local 1.
- غرفة ضيقة
  - Fibroid
  - Cong. anom.
  - Aschermann
  - Fixed RVF
- بوابة واسعة :- ✓✓✓
  - Cong
    - ↑ ms fibres
    - ass. e ut.
    - DES
  - acquired
    - obst.
      - Forceps
      - vent
      - Br. ext
    - gyna
      - D&C
      - Amput.
      - Coniz.

fetal 3.
- آخر حاجة
- 4-10%
- mainly structural

Assesment

History
- * Personal
- * C/O
  - >3 succesive
- * HPP
  - Abortions
  - Comp. ؟
- * Menst
  - ↓
  - ↑
  - PMspotting
- * Obst
  - time
  - order
  - abortus
  - special cc
- * Past
  - medical
  - surgical < obst / gyna
- * Family

Exam
- General
  - med. dis.
- local
  - ut (fibroid)
  - cx (tear) PIOs.
  - preg: < U/S better / T.V.
  - non-preg
    - HSG
    - Hysteroscopy
- Fetal
  - Post-mortem
  - Karyotyping

Inv.
- Progest. 21
- LH / FSH
- PPS
- $T_{3,4}$ TSH
- ANA, $C_{3,4}$
- ALA, ACA ✓✓
- Rh

ttt

General
- Reassurance
- more rest
- vit., Fe
- stop smoke, alcohol

Specific
- * PIOs



- * APS
  - Baby aspirin 75mg
  - ⊕ heparin 5000 u/12 or LMWH 30-40 m

idiopathic 50%
- ↓ imperical
  - Progest
  - folic acid
  - Aspirin ± heparin

السلام عليكم يا ست الكل
أنا ..... وبعد إذنك لو تسمحي هاكلم معاكي شوية

History

menst. obst

1. **LMP**

آخر مرة يا ماما جاتلك فيها الدورة كانت إمتى؟!
متأكدة؟ طب ده أول يوم ولا آخرها (1st day)

لو مش فاكرة
حاول تساعدها:
حدث مشهور
عيد الأضحى ...

ماكنش فيه أي استخدام لحاجة تمنع الحمل

طب آخر ٣ دورات كانوا عاديين؟

2. **EDD**: Naegel's rule
زود على
سبعة → الأيام
تسعة → الشهور (أو -3)

3. **EGA**:

wk = 7d
m = 4 wk +2
trim = 13 wk

القاعدة

حاجة من اتنين

LMP → EGA ← EDD

مطلع لأدام — "حسب أيهما أقرب" — ترجع لورا

Obst.

١- نمرة كام
٢- اتولد سنة كام
٣- اتولد في البيت ولا في المستشفى إسمها إيه؟
٤- فترة الحمل عدت على خير، يعني ماكنش فيه حاجة وحشة لا قدر الله زي الضغط أو السكر
٥- ولديه في الكام خد بالك أول السابع يعني 28 wk
٦- الولادة دخلتي فيها لوحدك ولا، وحتى المستشفى وهناك أدولك طلق صناعي أو ليه من أحب
٧- ولدتي صبي ولا بنت — جفت؟ شفاط؟ ليه؟ — قيصري
٨- حصل مشاكل بعد الولادة؟ نزيف مثلاً وخدتي دم؟
٩- وزنه كام — رضع طبيعي — كويس — وادولا — البيبي
١٠- فترة النفاس كان فيها مشاكل — جلطة مثلاً — جي نفاسي

P — + — > 28 <
- كام مرة؟ وحده؟ إسقاط؟ إزاي؟ بعملية
- حصل مشاكل بعدها؟ إسقاط؟ نزفتي؟

	2. Year	3. Place	4. Ante-partum	5. Duration	6. Onset	7. Mode of delivery	8. Post-Partum	9. Baby	10. Puerp.
1-			HTN	Term	Spont	Vaginal	PPhge	boy/girl	P. sepsis
2-			DM	PTL	induced	± forceps		alive, dead, incubated	DVT
3-						± ventouse		weight	
						CS		breast/bottle fed	

Contraceptive

- إستخدمتي وسائل منع حمل قبل كده؟
إيه هم: لولب/ شريط/ جهاز — أقراص — حقن/ ٣ أشهر — حقن تحت الجلد — جوزك بيستخدم حاجة موضعية (كبوت)
- من سنة كام لكام
- بين أي حمل و التاني
- إيه كانت آخر وسيلة فيها؟
- ليه بطلتيها؟ بطلتيها قبل الحمل ده كام شهر؟ كانت الدورة منتظمة؟
(إيه هي؟) مشاكل حصل علشان — أهمل علشان

menst. gyna

1. **Menarche**
البداية حلوة = 13yr
المشوار حلو

2. **D/C**
* regular
* sp. dysm.
* PMT ....

3. **LMP**
فيه معاها تقلصات
فيه قبلها بتعب
الصدر مثلاً بيبقى تقيل + صداع

* فيه تنقط قبل الدورة Premenst. spotting
* Midcyclic disch.
بين الدورة والدورة فيه شعور بالرطوبة في يوم معين

Investigations

Blood

- Hb → lower limit is 11 gm%.
  Normally 12-16
  but < RBCs ↑ 20-30% } physiolog. hemodilution
  plasma ↑ 40-50% }
- FBS 60-90
  1 hr < 140
  2 hr < 120
  RBS < 200

	Blood	Plasma
FBS	90	105
1 hr	165	196
2 hr	145	165
3 hr	125	145

- Renal function tests
  - creatinine 0.5 mg%
  - uric acid 3 mg%
  - BUN 8.5 mg%

Urine

- Pus cells 1-2/HPF
- Some crystals/ epith. cells
- Glucosuria : normal in preg. < renal / alimentary
- Albuminuria : only if dis :-
  ↓ ≈ 150 mg normally
  - PET
  - UTI
  - false (contamination)
  - orthostatic

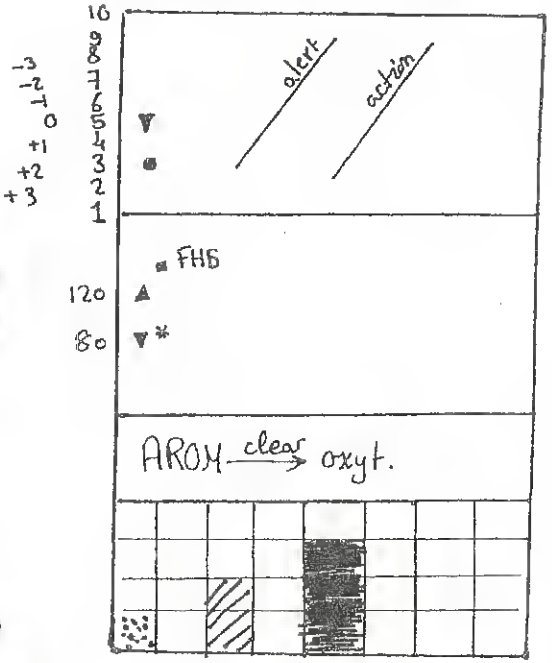

Tanner

	Breast	Pubic
	1	× ....عملة
1st mound	2	
بكر	3	
2nd mound	4	
بكر	5	....كبيرة

Final diagnosis

- Name
- age
- Parity
- gest. age
- ceph. / breech
- labor / not
- → obst. comp.
- → medical comp

on .... drugs
for .... invest.

CTG

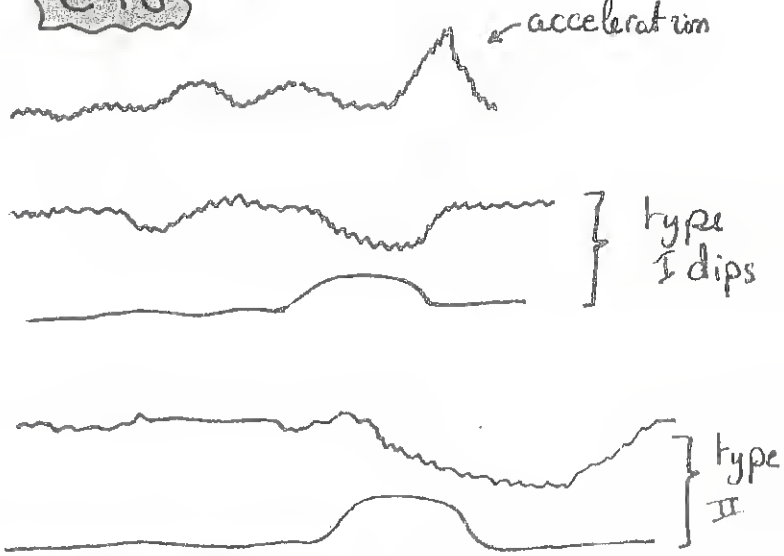

Fetal Kick chart

"Cardiff"
count to 10

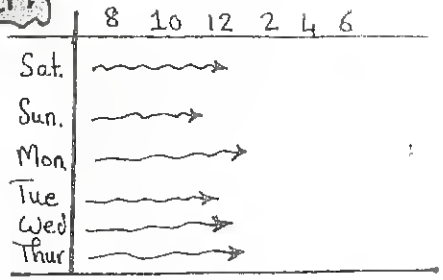

Semen

macrosc.	microsc.
- viscid	Count > 20 m/ml
- 2-4 ml	morph. > 30% norm.
- ccc odor	motility > 50% forw.
- ph alk. 7.2-7.8	pus cells < 1-2/HPF

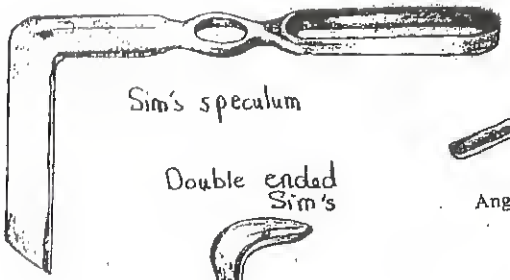
Sim's speculum

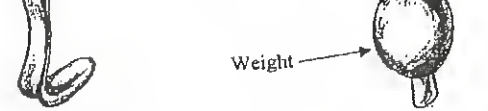
Double ended Sim's

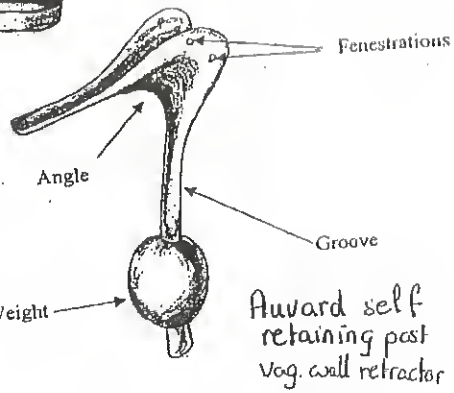
Fenestrations
Angle
Groove
Weight
Auvard self retaining post vag. wall retractor

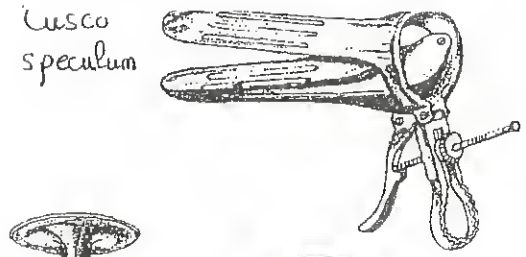
Cusco speculum

Pinard's stethosc.

Doyen's abd. retractor

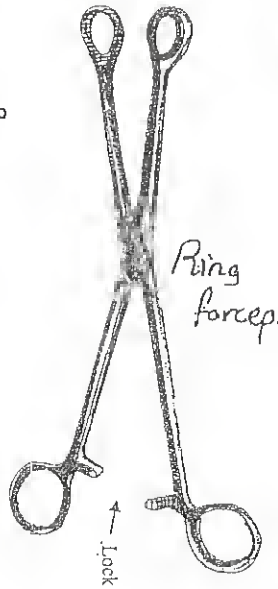
Ring forceps
Lock

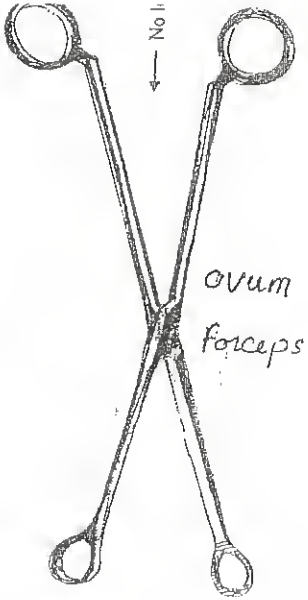
No 1
ovum forceps


metal catheter
uterine sound

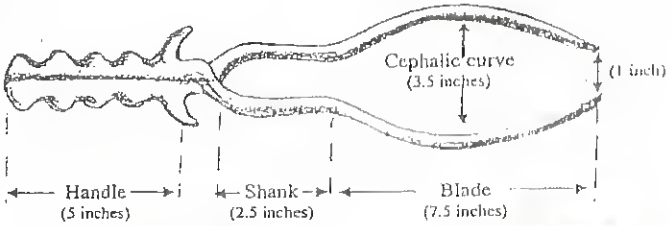
Cephalic curve
(3.5 inches)
(1 inch)
Handle
(5 inches)
Shank
(2.5 inches)
Blade
(7.5 inches)


multi-toothed volsellum
Hegar's dilator

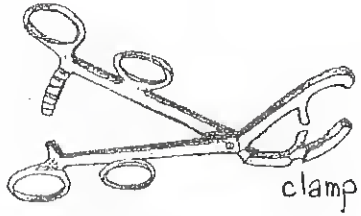
clamp
Bonney myomectomy

screw

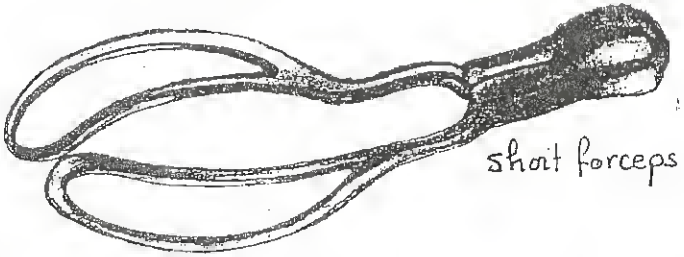
short forceps

Double end currette

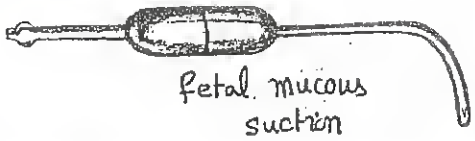
fetal mucous suction

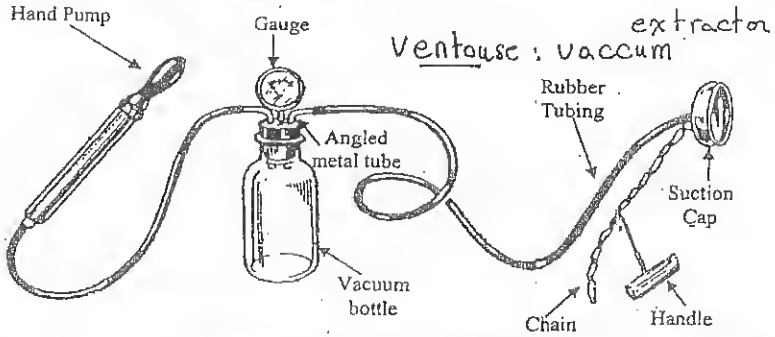
Ventouse : vaccum extractor
Hand Pump
Gauge
Rubber Tubing
Angled metal tube
Suction Cap
Vacuum bottle
Chain
Handle

أسئلة على الحالات obst الـ "A"

Abortion

→ threatened ± small retroplacental hematoma

→ habitual ab.

• إزاي تشخيصها
- من history > 3 successive
- من السونار: patulous: > 1cm عرض

• إيه أشهر الأسباب
- CAI
- APS
- thromboph.
- PIO

• إيه العلاج
1- McDonald } vag.
2- SchirodKar }
3- Abd.

• إيه مضاعفاتها
- إيرة: ROM, inj. of bl
- قلة: Ab., PTL, infect., irritat.

• إيه الأدوية:
imperical
- progesterone
- Heparin ± aspirin
- folic acid

ectopic

طالما محجوزة تبقى حاجة في البيت

waiting
- query?!
  - إيه الـ D.D.
    - thr. abortion
  - إزاي تتأكد
    - serial U/S, β-HCG
    - or laparoscopy
  - إيه أشهر سبب
    - Adhesions
    - PID
    - عملية
- undist.
  - قاعدة ليه
    - medical ttt
      - = methotrex
      - = 50mg/m²
  - إيه الشروط
    1- < 3cm
    2- < 3000 HCG
    3- no card. activity
    4- vitally stable

postop.
- laparotomy
- laparoscopy
- what was! presentation: acute abd ± collapse
- What was! 1st line of ttt: cannula + resuscit.
- What was done
  - ectomy
    - أنبوبة بارطة
    - كبيرة
    - معاها ميال
  - otomy
    - إلى حد ما سليمة
    - صغيرة
    - معاها في

Placenta

• في الأغلب الحالة المحجوزة:

P. previa

* عرفنا إزاي:
Painless, causeless
reccurent, fresh

* إيه أنواعها
minor { 1- Parietalis: low lying
2- marginalis
major { 3- partial
4- total } centralis

* إيه مضاعفاتها
- Fetal: ع حروف منتورة
- Maternal: Preg., Part. 1,2,3, Peurp.

* إيه الـ D.D.
- maternal: Pl., extra-pl
- fetal = V. previa

* العيانة محجوزة لإمتى؟
- Mother → labor
- fetus < mature / distressed
- Bleeding → severe

* إزاي هاتولد
- غالباً CS
  - major degree
  - severe bl.
- ممكن V.D.
  - minor degree
  - mild bl

* صفة المستشفى
1- NICU
2- bl. bank
3- Op. theat.
كويس

Mole

حالة نادرة

* إزاي تشخيصها
- History: ↑enlargem
- Inv
  - U/S: snow storm
  - HCG > 100.000

* إيه الـ etiology
- androgenesis

* إمتى يكون فيه عيل
- partial
- twins

* إمتى تبقى acute abd.
- torsion
- T-L cysts

* إيه العلاج
- صغيرة → suction
- كبيرة → hyst.
- ⊕ follow up by β-HCG

* إيه أخطر حاجة
- Choriocr. تقلب

أسئلة على الحالات الـ Obst "A"

HTN

mild PET

P.I.H.
P.Ass.H.
P.Agg.H.
> إيه الـ D.D.

not in lab. ... M.
not distressed ... F.
immature ...
mild ... المرض
> ليه محجوزة

إيه المشاكل
كل حاجة > Mat.
Fetal < IUGR, IUFD, pl. abruption

HTN
edema
Pturia
> إزاي تشخصها

لو بقت severe / mature > إمتى هاتولد

Chronic HTN

إزاي تفرقهم
- fundus exam.
- past history
- no pturia إلا لو الكلى باظت
- no syst. affection

إيه الـ criteria بتاعة severe PET
* sympt. ✓
* signs < BPr 160/110, Ptn >++
* comp } M. or F.
* inv. }

إيه الـ stages of eclampsia
Prodroma
tonic
clonic
coma

DM

* classify ! pt. according to Priscilla White
* take history for the medication

insulin
2/3 → 7 am: R 1/3, NPH 2/3
1/3 → 5 pm: R 1/2, NPH 1/2

* إيه مشكلة الـ baby هنا
↳ Pt. insuff:
- Abortion
- CFMF
- IUGR
- IUFD

ممكن تبقى حاجة من اتنين

gestational

* إزاي عرفتها : = screening
→ PPS 1 hr
>140 → 3 hr GTT

* إيه مشاكله
DM أصلاً ⇌ Preg.
- mother
- fetus
- neoborn

* إمتى هاتولد ؟
as soon as lung maturity is documented

* إزاي هاتولد ؟
في الأغلب قيصرية علشان الـ macrosomia

إزاي تتحكم فيها : HBA_{1c}

Pregestational

* إيه الـ normal 12-14

* يعني إيه path. anemia < 11 gm% علشان في حاجة اسمها physiological hemodilution

* إزاي أشخصها ؟
- S. ferritin ↓
- S. iron ↓
- B.M stores ↓
- transferrin sat. ↓
الوحيدة = ↑ total Fe binding cap.

Anemia

* إزاي أعالج : 1) Prophylaxis
oral Fe 30-60 mg/d
2) therapeutic
↳ oral 120-240
↳ parentral < Fe dextran, Fe sorbitol
↳ packed RBCs

Heart

* إيه الـ normal
في الحل شبه القلب

* إزاي هاتولد ؟
في الأغلب طبيعي > small baby, soft cx

* إيه المشاكل

symp. < dyspnea, palpit., lower limb edema, malar flush

signs — peripheral: • SVC • hyper-dynamic
central: • S_1 split • S_3 • syst. murmur (soft)

* إيه علاج الـ artificial valve
1- Heparin in 1st trim. & < labor
2- Heparin all through
3- OAC all through.

كبير ⊕ خد بالك من الـ valve replacement